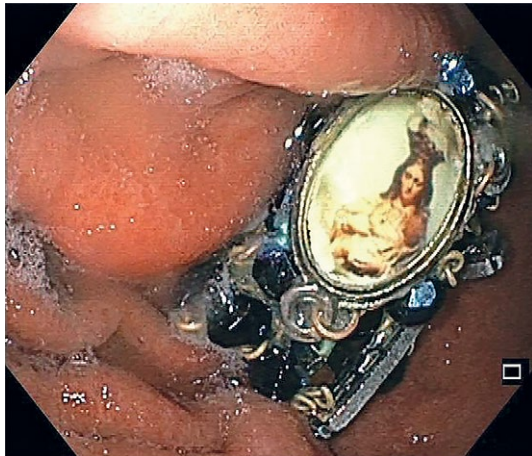


A Blessed Endoscopy

Tiago Leal, Bruno Arroja, Raquel Gonçalves

Braga Hospital, Sete Fontes - São Victor 4710-243 Braga, Portugal



Foreign body ingestion is a common gastroenterological emergency. Most cases occur in children (80%) [1]. In the adult setting, it usually consists of meat/fish bones ingestion or food bolus impaction, in patients with underlying pathology such as peptic strictures or eosinophilic esophagitis [1, 2]. Other foreign bodies may be ingested, namely in the elderly or in those with psychiatric diseases [1, 3].

An 83 year-old female patient with Alzheimer's disease was transferred to our Hospital due to foreign body ingestion. According to her relatives, she was praying avidly with a rosary, when they noticed it had disappeared, raising the suspicion of its inadvertent ingestion. The patient underwent gastroscopy where the rosary was seen, lodged in a gastric fold of the stomach body (Fig. 1). It was removed with the Roth Net® retriever, without complications.

Non-food foreign body ingestion, in adults, is more frequent in older people and in mentally affected patients. The clinical presentation may consist of dysphagia, sensation of foreign body or chest pain [4]. Endoscopy represents a safe and efficient tool to solve these situations [3, 5], being required in around 70% of cases [5]. The timing of endoscopy and the method and device used depend of the type of the ingested object [1, 3, 5]. Sharp objects, disk batteries and foreign bodies occluding the esophagus require emergent endoscopy. Short, blunt objects

may be retrieved using a net or basket; long or sharp-pointed foreign bodies are usually removed by polypectomy snare or retrieval forceps, sometimes with the application of an overtube, to prevent laceration. The need for surgery ranges from 1 to 16%, usually due to perforation [5, 6]. Although foreign body ingestions are generally easily manageable emergencies, they should not be underestimated since mortality is a rare but possible outcome [7].

The relevance of this case is highlighted by the peculiarity of the foreign body.

Corresponding author: Tiago Leal, tiago.afleal@gmail.com

Conflicts of interest: None to declare.

REFERENCES

1. Sugawa C, Ono H, Taleb M, Lucas CE. Endoscopic management of foreign bodies in the upper gastrointestinal tract: A review. *World J Gastrointest Endosc* 2014;6:475-481. doi:[10.4253/wjge.v6.i10.475](https://doi.org/10.4253/wjge.v6.i10.475)
2. Ambe P, Weber SA, Schauer M, Knoefel WT. Swallowed foreign bodies in adults. *Dtsch Arztebl Int* 2012;109:869-875. doi:[10.3238/arztebl.2012.0869](https://doi.org/10.3238/arztebl.2012.0869)
3. Birk M, Bauerfeind P, Deprez PH, et al. Removal of foreign bodies in the upper gastrointestinal tract in adults: European Society of Gastrointestinal Endoscopy (ESGE) Clinical Guideline. *Endoscopy* 2016;48:489-496. doi:[10.1055/s-0042-100456](https://doi.org/10.1055/s-0042-100456)
4. Chiu YH, Hou SK, Chen SC, et al. Diagnosis and endoscopic management of upper gastrointestinal foreign bodies. *Am J Med Sci* 2012;343:192-195. doi:[10.1097/MAJ.0b013e3182263035](https://doi.org/10.1097/MAJ.0b013e3182263035)
5. ASGE Standards of Practice Committee, Ikenberry SO, Kue TL, et al. Management of ingested foreign bodies and food impactions. *Gastrointest Endosc* 2011;73:1085-1091. doi:[10.1016/j.gie.2010.11.010](https://doi.org/10.1016/j.gie.2010.11.010)
6. Sung SH, Jeon SW, Son HS, et al. Factors predictive of risk for complications in patients with oesophageal foreign bodies. *Dig Liver Dis* 2011;43:632-635. doi:[10.1016/j.dld.2011.02.018](https://doi.org/10.1016/j.dld.2011.02.018)
7. Webb WA. Management of foreign bodies of the upper gastrointestinal tract. *Gastroenterology* 1988;94:204-216.