

Septo-optic dysplasia with olfactory tract hypoplasia

Manuel Ribeiro, Álvaro Machado,¹ and João Soares-Fernandes

Department of Neuradiology, Hospital de São Marcos, Braga, Portugal.

¹Department of Neurology, Hospital de São Marcos, Braga, Portugal.

Address for Correspondence: Dr. Alvaro Machado, Hospital de São Marcos Largo Carlos Amarante Ap 4200 Braga Portugal., Email: alvmac@gmail.com

This is an open-access article distributed under the terms of the Creative Commons Attribution-Noncommercial-Share Alike 3.0 Unported, which permits unrestricted use, distribution, and reproduction in any medium, provided the original work is properly cited.

• [Other Sections ▼](#)

Sir,

Septo-optic dysplasia (SOD) is a rare developmental anomaly, characterized by optic nerve hypoplasia and septum pellucidum (SP) agenesis, which is frequently associated with hormonal deficiencies.[1] The combination of SOD and olfactory tract hypoplasia is very rare. We present here one such case of a four month-old male patient with the antenatal diagnosis of an SP cyst.

The child had an otherwise unremarkable birth history and physical development, having appropriately reached all early childhood milestones. Transfontanelar ultrasonographic examination revealed absence of SP and mild enlargement of the lateral ventricles. MRI [Figure 1] confirmed complete SP absence and showed right optic nerve atrophy. Hypoplasia of the olfactory tract and sulci hypoplasia were also noted. There was diffuse white matter atrophy with thinning of the corpus callosum which was otherwise well formed, and large ventricles with squared-off appearance of the frontal horns. The pituitary gland was small and there was no evidence of schizencephaly. Ophthalmologic examination confirmed right optic disc hypoplasia whereas endocrine studies showed no abnormalities.

The diagnosis of SOD is established when optic disc hypoplasia is observed in association with agenesis of the septum pellucidum.[1,2] This case represents a very rare association of SOD and olfactory tract hypoplasia.

The etiology of SOD remains uncertain, with genetic abnormalities (in continuum with lobar holoprosencephaly) and intrauterine insults having nevertheless been proposed as etiological factors.[1] In several cases, mutations in the *HESX1* gene were shown to be implicated with mild pituitary hypoplasia or SOD.[1] Transgenic mice lacking the homolog gene of human *Hesx1* exhibit a phenotype, including SP abnormalities, hypoplastic optic vesicles, pituitary dysplasia, and defective olfactory development.[3] SOD also presents a highly variable phenotype in humans.[2] The authors believe that bulb and tract olfactory hypoplasia should be included in the variable phenotype of SOD.

References

1. Kelberman D, Dattani MT. Septo-optic dysplasia: Novel insights into the aetiology. *Horm Res.* 2008;69:257–65. [PubMed: 18259104]
2. Levine LM, Bhatti MT, Mancuso AA. Septo-optic dysplasia with olfactory tract and bulb hypoplasia. *J AAPOS.* 2001;5:398–9. [PubMed: 11753263]
3. Dattani MT, Martinez-Barbera JP, Thomas PQ, Brickman JM, Gupta R, Wales JK, et al. HESX1: A novel gene implicated in a familial form of septo-optic dysplasia. *Acta Paediatr Suppl.* 1999;88:49–54. [PubMed: 10626545]

Figures and Tables

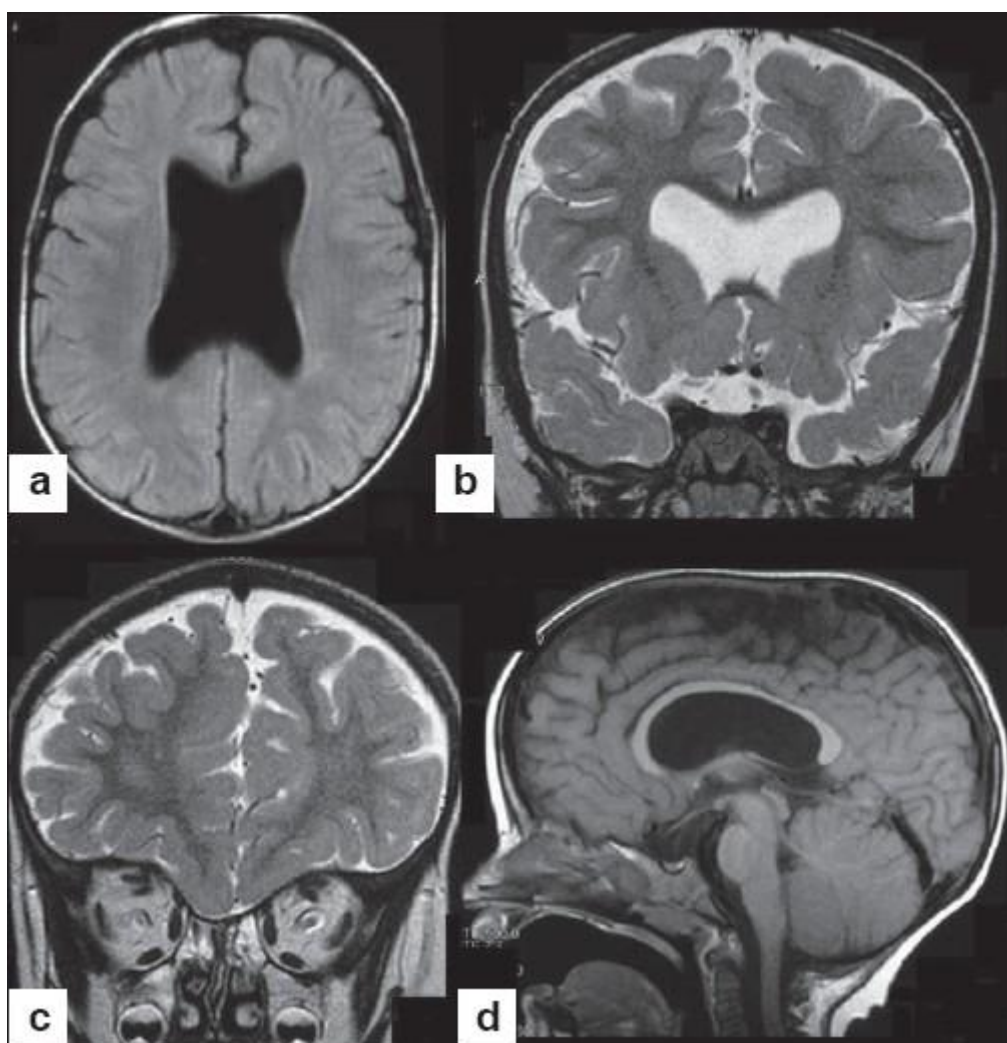


Figure 1

a) Axial FLAIR shows mild ventricular enlargement secondary to diffuse white matter hypoplasia; b) Coronal T2 shows absence of septum pelucidum and hypoplasia of the right optic nerve; c) Sagittal T1 shows thinning of the corpus callosum and a small hypophysis

