

## References

- 1 Raj S, Calonje E, Kraus M, *et al.* Cutaneous pilar leiomyoma: clinicopathologic analysis of 53 lesions in 45 patients. *Am J Dermatopathol* 1997; **19**: 2–9.
- 2 Akay BN, Boyvat A, Heper AO, *et al.* Congenital pilar leiomyoma. *J Am Acad Dermatol* 2008; **59**: S102–S104.
- 3 Gokdemir G, Altunay IK, Koslu A, *et al.* A case of multiple facial painless leiomyomata. *J Eur Acad Dermatol Venereol* 2000; **14**: 144–145.
- 4 Tomlinson IP, Alam NA, Rowan AJ, *et al.* Germline mutations in FH predispose to dominantly inherited uterine fibroids, skin leiomyomata and papillary renal cell cancer. *Nat Genet* 2002; **30**: 406–410.
- 5 Alam NA, Barclay E, Rowan AJ, *et al.* Clinical features of multiple cutaneous and uterine leiomyomatosis: an underdiagnosed tumor syndrome. *Arch Dermatol* 2005; **141**: 199–206.
- 6 Badeloe S, van Geel M, van Steensel MA, *et al.* Diffuse and segmental variants of cutaneous leiomyomatosis: novel mutations in the fumarate hydratase gene and review of the literature. *Exp Dermatol* 2006; **15**: 735–741.
- 7 Stewart L, Glenn GM, Stratton P, *et al.* Association of germline mutations in the fumarate hydratase gene and uterine fibroids in women with hereditary leiomyomatosis and renal cell cancer. *Arch Dermatol* 2008; **144**: 1584–1592.
- 8 Sifaki MK, Krueger-Krasagakis S, Koutsopoulos A, *et al.* Botulinum toxin type A – treatment of a patient with multiple cutaneous piloleiomyomas. *Dermatology* 2009; **218**: 44–47.
- 9 Gravvanis A, Kakagia D, Papadopoulos S, *et al.* Dermal skin template for the management of multiple cutaneous leiomyomas. *J Cutan Med Surg* 2009; **13**: 102–105.

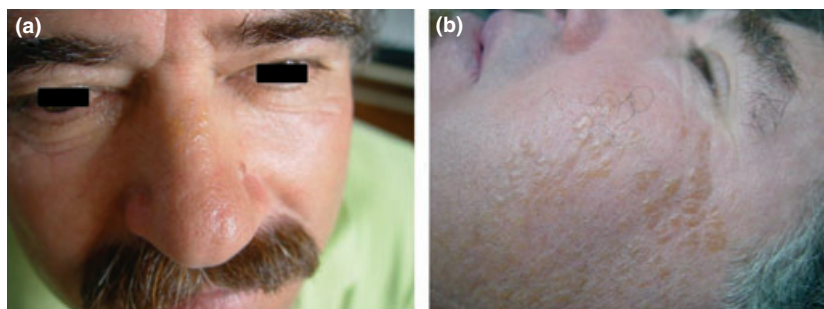
## Colloid milium successfully treated with MAL-PDT

An otherwise healthy 55-year-old Caucasian man presented for evaluation of long standing asymptomatic slow-growing lesions on his face. Physical examination revealed numerous yellowish, translucent, firm, millimetric papules on his nose, bilateral temples, and zygomatic cheeks (Fig. 1a). His past medical history was negative for photosensitizing medications or disorders. His 47-year-old brother had similar lesions on his cheeks but in greater number (Fig. 1b). Skin biopsy of one of the papules of both patients revealed a well-circumscribed mass of homogeneous, faintly eosinophilic, fissured material on papillary dermis, consistent with colloid milium (CM; Fig. 2).

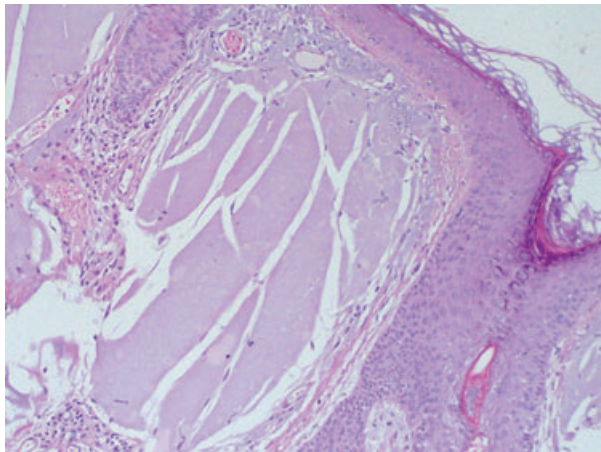
Though largely asymptomatic, both of our patients sought treatment to improve their appearance. Several approaches have been tried in the management of this condition, including dermabrasion, diathermy, cryotherapy and laser resurfacing,<sup>1–3</sup> but there are few reports of effective treatment. We initiated treatment with cryotherapy and photoprotective creams with limited success. The next step involved the use of topical photodynamic

therapy (PDT), using methyl-aminolevulinate (MAL) cream as photosensitizer. Prior to PDT, a superficial curettage was performed. MAL cream 160 mg/g (Metvix<sup>®</sup>, Galderma, Portugal) was applied and covered with an adhesive occlusive dressing for an incubation period of three hours, followed by illumination with red light source, Aktelite<sup>®</sup> CL 128 lamp (PhotoCure ASA, Oslo, Norway) (average wavelength 635 nm, light dose 37 J/cm<sup>2</sup>). Two PDT treatments seven days apart were performed (one cycle).

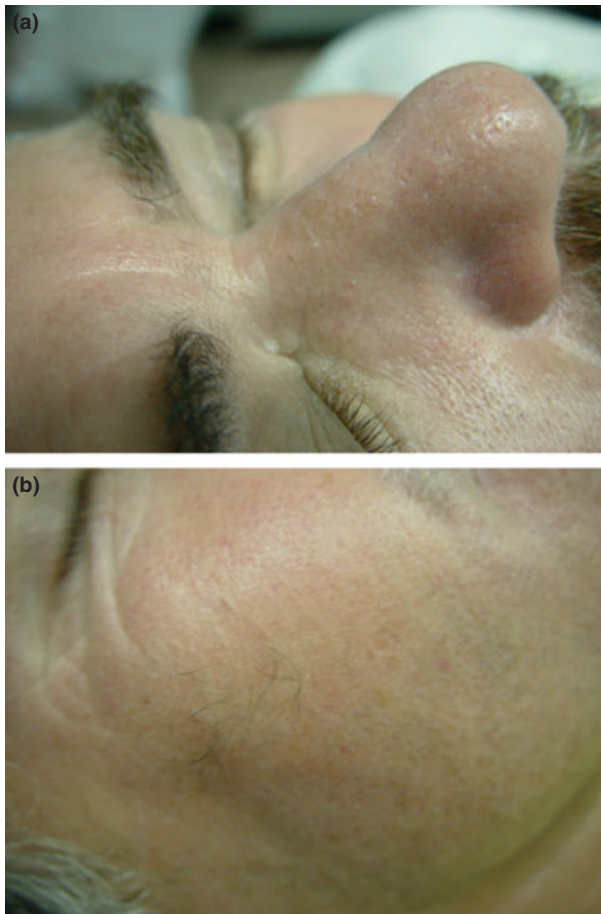The patient with fewer lesions showed complete resolution of the lesions after two sessions (one cycle) of MAL-PDT, with excellent cosmetic results (Fig. 3a). The younger brother required three additional treatments, with a monthly periodicity, to cope with the larger number of lesions, but the results were also excellent (Fig. 3b). Treatment was well tolerated. Both patients reported mild burning sensation during irradiation, but none of them asked to interrupt the procedure. We did not observe any side effects, such as swelling or blistering. No recurrence was observed at a one-year follow-up visit.



**Figure 1** (a) Patient 1 – 55-year-old brother with multiple yellow, translucent papules on his nose. (b) Patient 2 – similar lesions but in greater number on the younger brother



**Figure 2** Hematoxylin and eosin-stained section showing well-circumscribed dermal collections of amorphous, homogenous, fissured material ( $\times 40$ )



**Figure 3** Appearance after PDT. (a) Patient 1. (b) Patient 2

CM is a rare cutaneous deposition disease that frequently involves areas of chronic sun exposure.<sup>1,2,4</sup> It was first described in the medical literature by Wagner in

1866 and was thought to result from the degeneration of sebaceous glands.<sup>5</sup> Multiple theories have been proposed regarding the pathogenesis of CM, but the exact etiology remains unclear, although prolonged, unprotected sun exposure is clearly involved in its pathogenesis.<sup>1,6</sup> This condition is most common in middle-aged, fair-skinned individuals.<sup>6</sup>

There are at least four variants of colloid degeneration of the skin: juvenile CM; classic adult type; pigmented CM; and nodular colloid degeneration or paracolloid.<sup>6</sup>

Adult CM is the most common type.<sup>7,8</sup> The colloidal material is thought to be either derived from actinic degeneration of elastic fibers or produced by actinically damaged fibroblasts.<sup>7,9</sup>

Juvenile CM is a very rare subtype, with the onset being prior to puberty. A family history of this condition has been reported.<sup>8</sup> Clinically the lesions are similar to the adult type, but it appears that the keratinocytes, rather than the elastic fibers, provide the cellular origin for the eosinophilic material in the dermis in the juvenile variant.<sup>2,8</sup>

Pigmented CM has been shown to be linked to sun exposure and the use of hydroquinone-containing creams.<sup>6</sup> It has a distinct clinical presentation. Lesions are usually hyperpigmented, and the skin can have an atrophic appearance.<sup>6</sup>

The use of PDT by dermatologists has expanded over the past years, now including a wide range of skin disorders. An attractive feature of topical PDT is the relatively low number of side effects, with only mild, transient, local side effects. In conclusion, PDT may prove to be a viable alternative in the treatment of CM, but further research in this field is needed.

Joana Gomes, MD  
Filipa Ventura, MD  
Maria da Luz Duarte, MD  
Celeste Brito, MD  
Dermatology Department  
Hospital de Braga  
Braga  
Portugal  
E-mail: gbmjoana@yahoo.com

Funding sources: None.  
Conflict of interest: None.

#### References

- 1 Netscher DT, Sharma S, Kinner BM, *et al.* Adult-type colloid milium of hands and face successfully treated with dermabrasion. *South Med J* 1996; 89: 1004–1007.

- 2 Wagner E. Das Colloid-Millium der Haut. *Arch Heilkunde* 1866; 7: 463–464.
- 3 Ammirati CT, Giancola JM, Hruza GJ. Adult-onset facial colloid milium successfully treated with the long-pulsed Er:YAG laser. *Dermatol Surg* 2002; 28: 215–219.
- 4 Grunwald MH, Giryas H, Hallel-Halevy D. Adult colloid milium. *Eur J Dermatol* 1997; 7: 603–604.
- 5 Pourrabbani S, Marra DE, Fincher EF, Moy RL. Colloid milium: a review and update. *J Drugs Dermatol* 2007; 6: 293–296.
- 6 Marra DE, Pourrabbani S, Fincher EF, Moy RL. Fractional photothermolysis for the treatment of adult colloid milium. *Arch Dermatol* 2007; 143: 572–574.
- 7 Desai AM, Pielop JA, Smith-Zagone MJ, Hsu S. Colloid millium: a histopathologic mimicker of nodular amyloidosis. *Arch Dermatol* 2006; 142: 784–785.
- 8 Hashimoto K, Black M. Colloid milium: a final degeneration product of actinic elastoid. *J Cutan Pathol* 1985; 12: 147–156.
- 9 Chowdhury MMU, Blackford S, Williams S. Juvenile colloid milium associated with ligneous conjunctivitis: report of a case and review of the literature. *Clin Exp Dermatol* 2000; 25: 138–140.

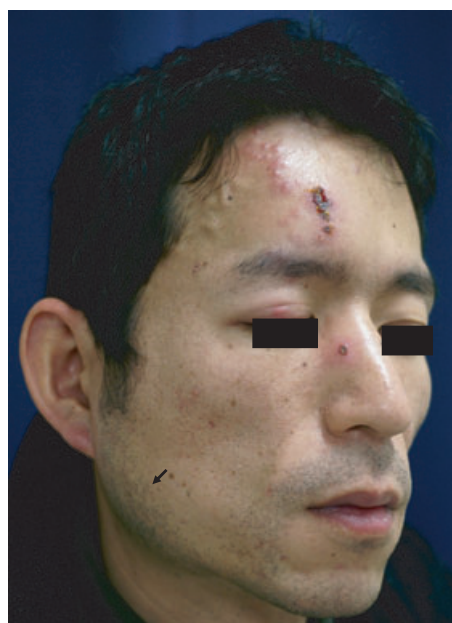### Herpes zoster ophthalmicus with ipsilateral parotitis

Parotitis as a complication associated with herpes zoster is very rare. We describe a healthy man who developed roughly simultaneous onset of herpes zoster ophthalmicus with ipsilateral parotitis.

A 38-year-old man was admitted to our hospital complaining of painful eruptions on the right side of the forehead and swelling of the ipsilateral parotid gland. Six days before initial examination, he developed painful erythema on the right forehead, and then two days later, he noticed vesicles on the right forehead and painful swelling in front of the auricular region and involving the jaw. The patient did not have a history of chronic recurrent parotitis. Physical examination demonstrated vesicles and ulcers with crusts on the right forehead, upper eyelid, and nose, but there were no lesions on the cheek or jaw (Fig. 1) and no lesions in the oral cavity. There were no generalized eruptions either. However, he complained of lancinating pain affecting the head, forehead, cheek, and jaw. Varicella-zoster virus (VZV)-specific antigen was observed in a smear from the lesion by direct immunofluorescent staining using fluorescein isothiocyanate-conjugated anti-VZV monoclonal antibody. An assay of serum antibody to VZV by complement fixation test was carried out using acute phase and convalescent phase sera. The titers of VZV antibodies were 8 on April 7 and 256 on May 6, respectively. Specific IgM and IgG antibodies to mumps virus by enzyme-linked immunosorbent assay were <0.8 and 8.1(+) on May 6, respectively. Antibody to human immunodeficiency virus-1 and 2 was not detected by gelatin particle agglutination assay. Diffusion-weighted magnet resonance (MR) imaging demonstrated that the right parotid gland was larger than that on the left (Fig. 2). Intravenous acyclovir therapy (750 mg/d) was administered from April 7 to April 13. Three days after the start of therapy, painful swelling of the parotid gland was rapidly decreased. Two weeks after therapy, the eruptions had healed;

two weeks later, most of the parotid gland enlargement had subsided.

To our knowledge, this is the second case of herpes zoster ophthalmicus with ipsilateral parotitis. In 1970, Marshall first reported a previously healthy 58-year-old man who developed herpes zoster involving the left side of the head and forehead accompanied by ipsilateral painful parotitis. There were no skin lesions in the left jaw area in that case.<sup>1</sup> In our case, ophthalmic herpes zoster and ipsilateral parotitis developed with roughly simultaneous onset. In addition, after acyclovir therapy, eruption and enlargement of the parotid gland both recovered rapidly. MR imaging demonstrated swelling of the right parotid gland. These findings suggest that parotitis might



**Figure 1** Clinical finding: skin lesions on the face and enlargement of the parotid gland