

PRIMARY SYSTEMIC AMYLOIDOSIS - THE NEED FOR EARLY DIAGNOSIS

Lages, A; Cabral, C; Gonçalves, A; Araújo, R; Mariz, J.
Hospital de Braga, Portugal

European and Swiss Congress
of Internal Medicine 2014

Amyloidosis is a group of rare but serious diseases caused by deposits of amyloid substance in tissues and organs throughout the body. It can be classified in primary or secondary with evidence of coexisting previous chronic inflammatory or infectious conditions. Our aim is to demonstrate the importance of considering amyloidosis as a diagnosis in a patient with multiple organ failure of undetermined etiology.

Clinical Case

Sixty-six year's old male with one year history of chronic liver and kidney disease (stage 3) of undetermined etiology was admitted, to our Ward, for declined renal function with hyperkalemia and right heart failure signs.

Physical examination was remarkable for hepatomegaly, ascites and oedema of the lower limbs.

Full Blood Count

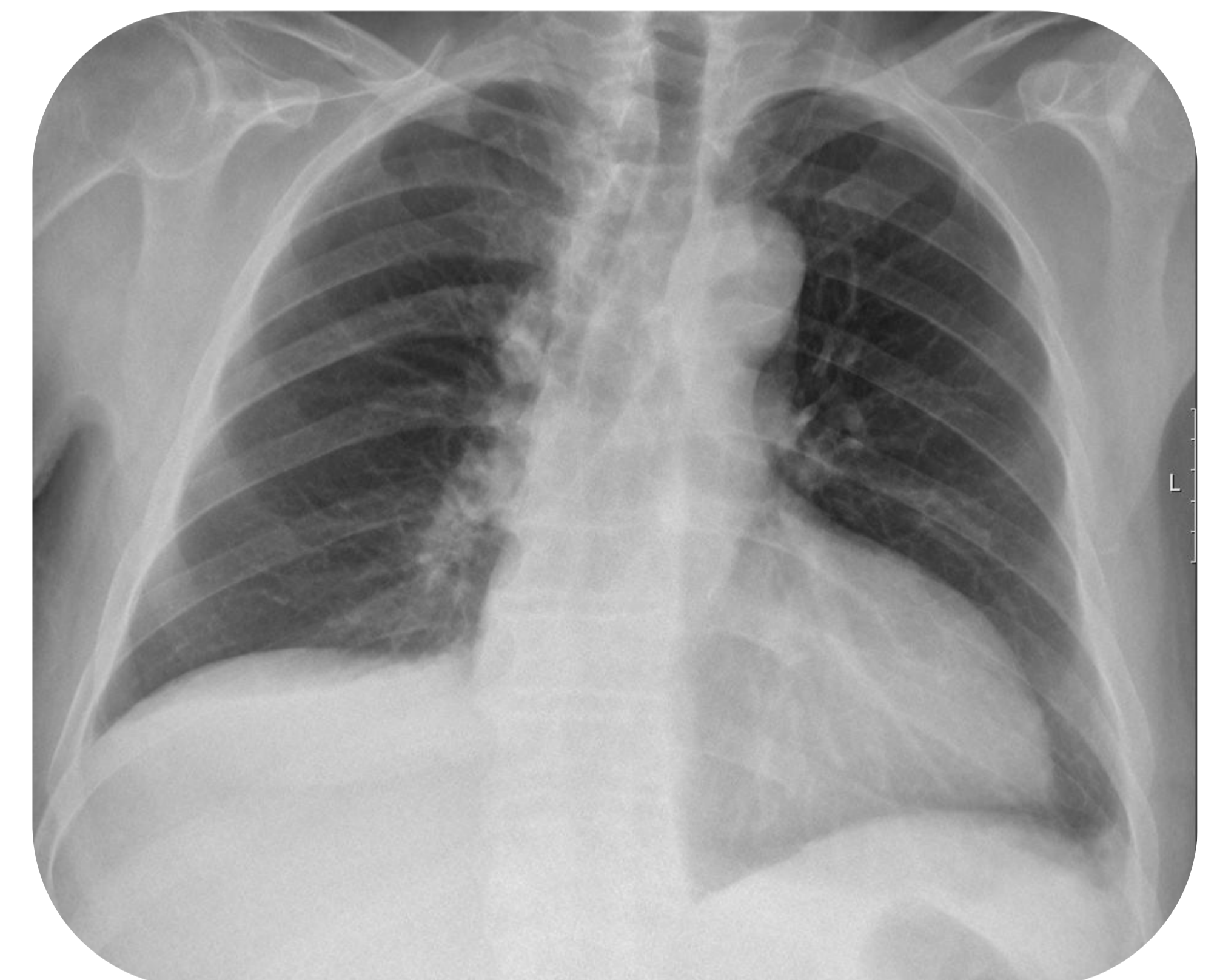
Erythrocytes (4-5 10*12/L)	4.35
Hemoglobin (12-16 g/dL)	12.3
Leucocytes (4.0-11 10*9/L)	13.80
Platelets (150-400 10*9/L)	244
Coagulation	
PT (8.0-14.0 sec)	14.1
aPTT (25.0-35.0 sec)	31

Biochemistry

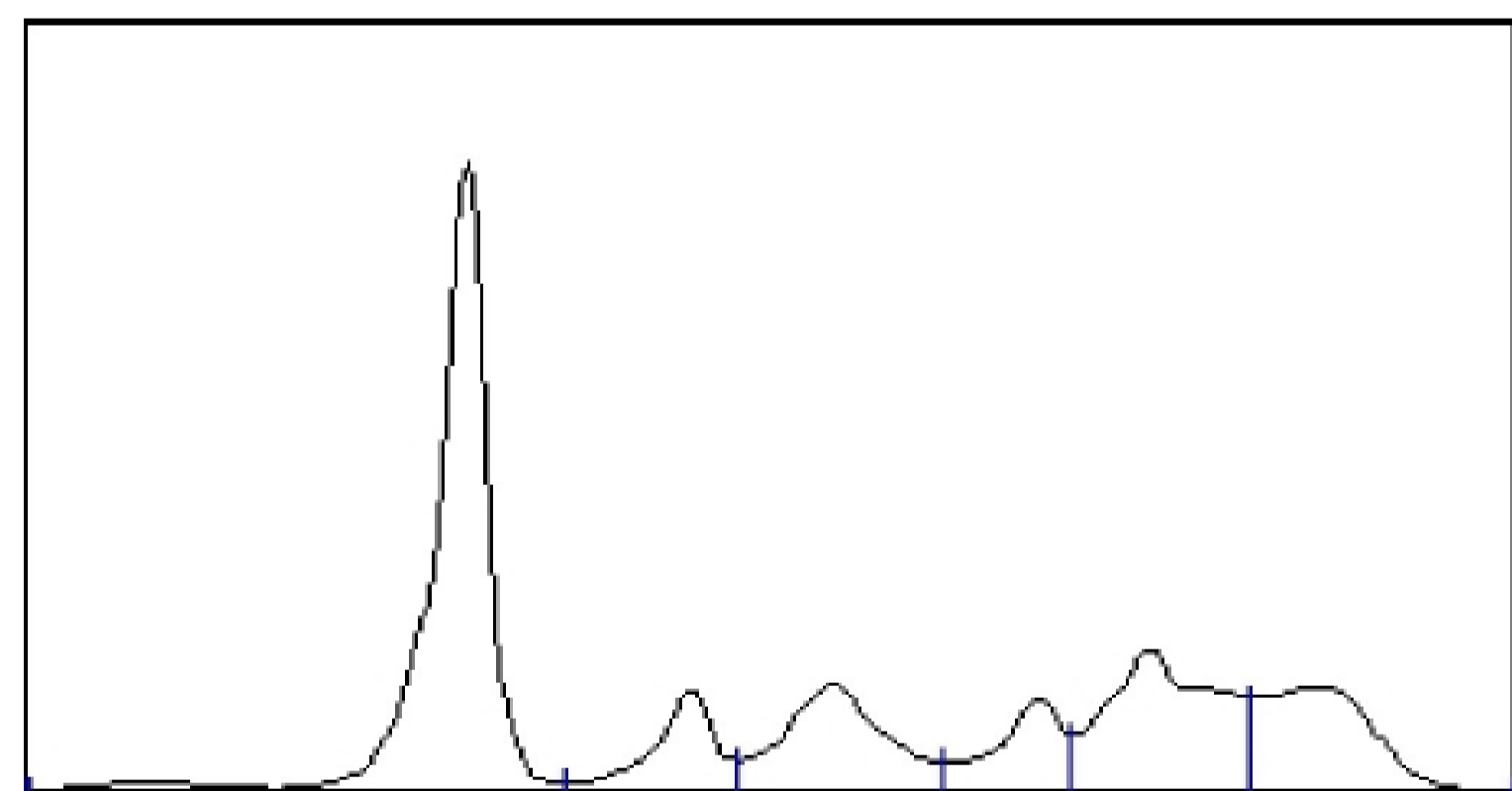
Glucose (75-110 mg/dl)	89
Urea (10-50 mg/dl)	135
Creatinine (0.6-1.1 mg/dl)	3.5
Potassium (3.5-5.1 mEq/L)	5.5
Sodium (136-147 mEq/L)	145
Calcium (4.05-5.2 mEq/L)	5
Phosphorus (2.7-4.5 mg/dl)	4.4
Bilirubin (<1.2 mg/dl)	0.63
AST (10-31 U/L)	33
ALT (10-31 U/L)	23
Ferritin (26-388 ng/mL)	111
β2 microglobulin (1090-2530 ng/mL)	15007
LDH (135-225 U/L)	234
C-reactive Protein (<3 mg/L)	27.2
Serum proteins (6.4-8.2 g/dl)	5.5
Albumin (3.4 -5 g/dl)	1.9
Creatinine Kinase (39-380 U/L)	69
PBNP (<125 pg/ml)	1357

ECG: Sinus rythm, low voltage.

Echocardiogram: left ventricle wall thickened with heterogen tissue aspect in favour of an infiltrative process.



Autoimmune panel and viral serologies negative.
Bone marrow aspirate: 5% plasmocytes.



IMUNOELECTROFORESE

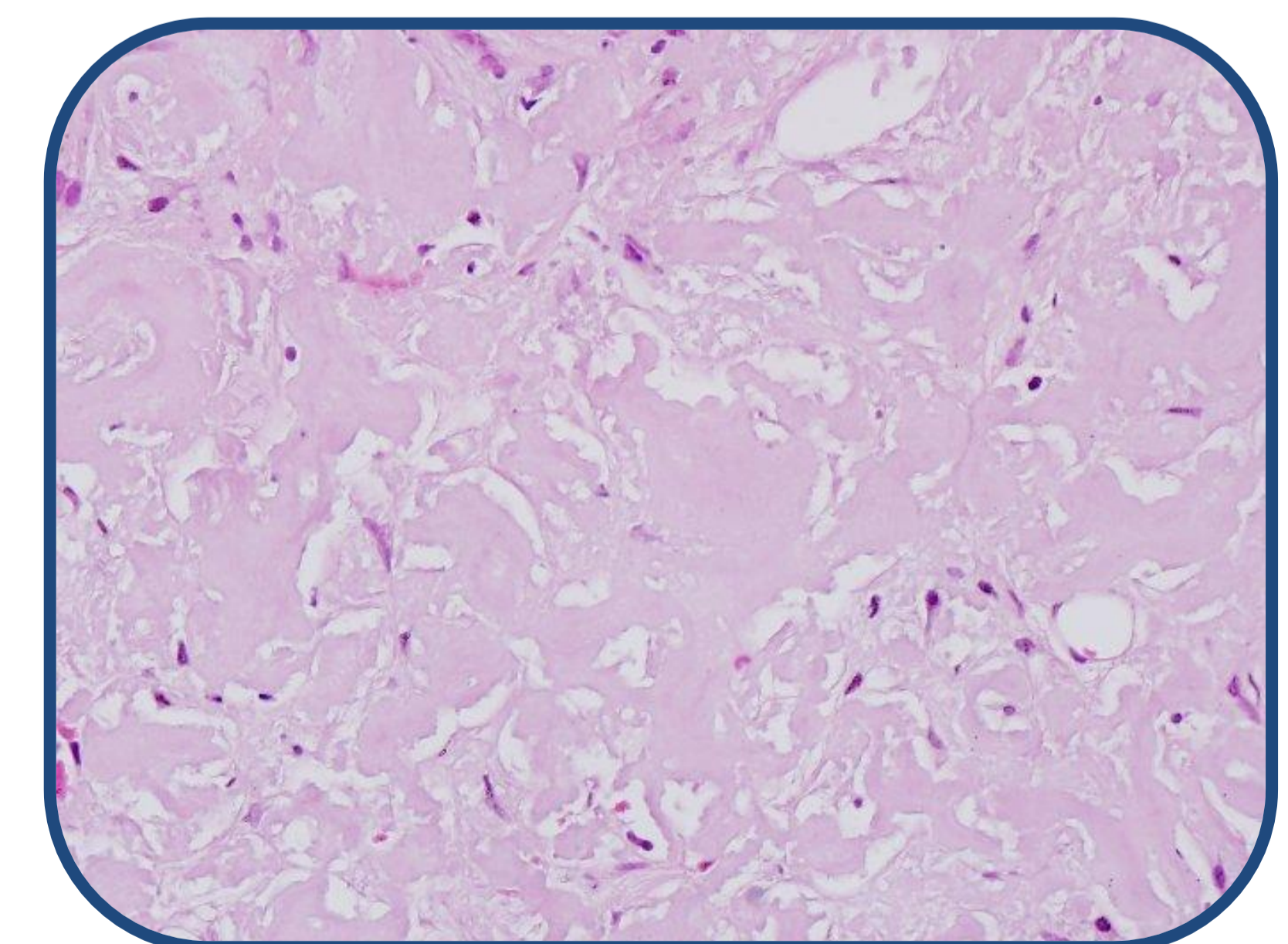
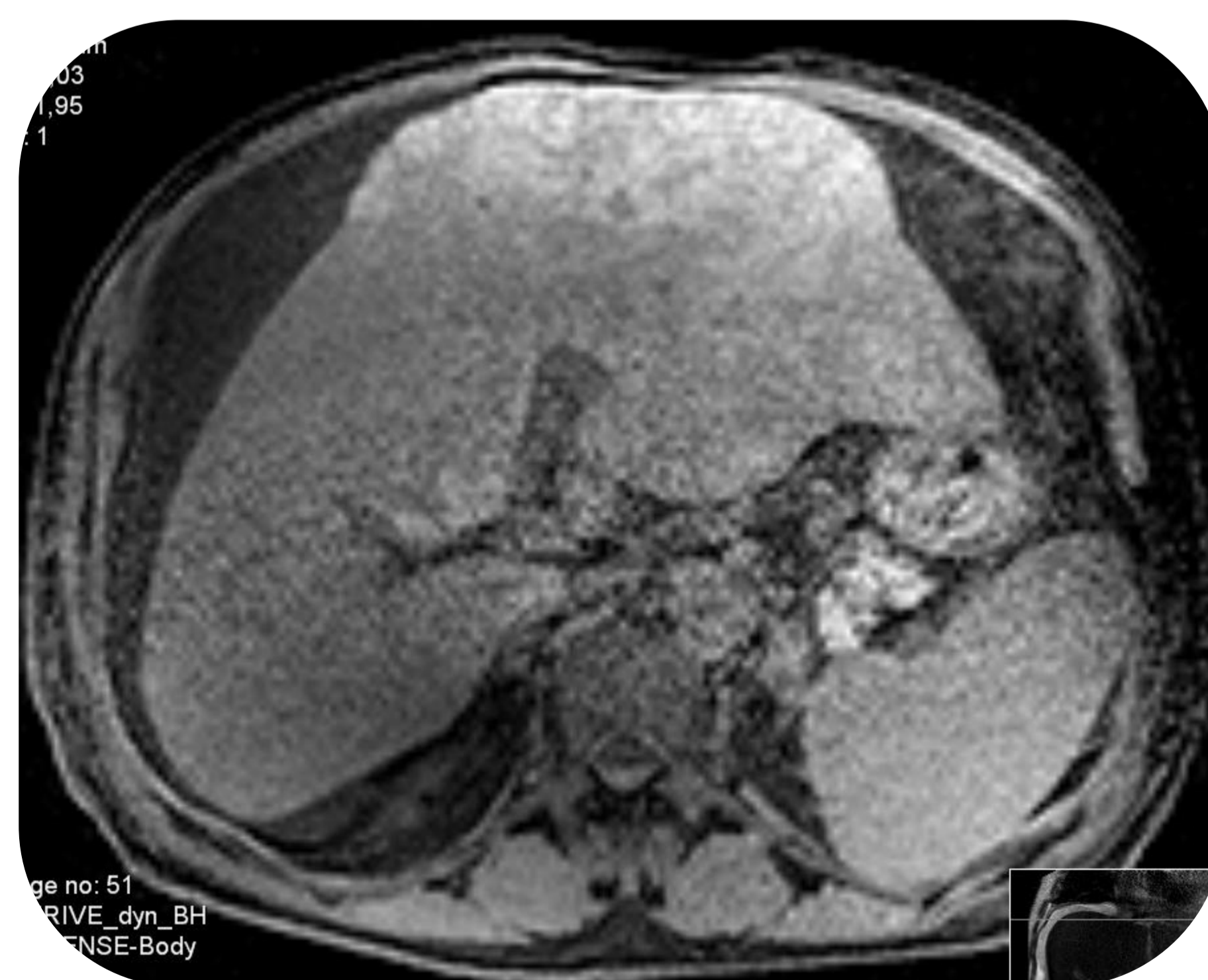
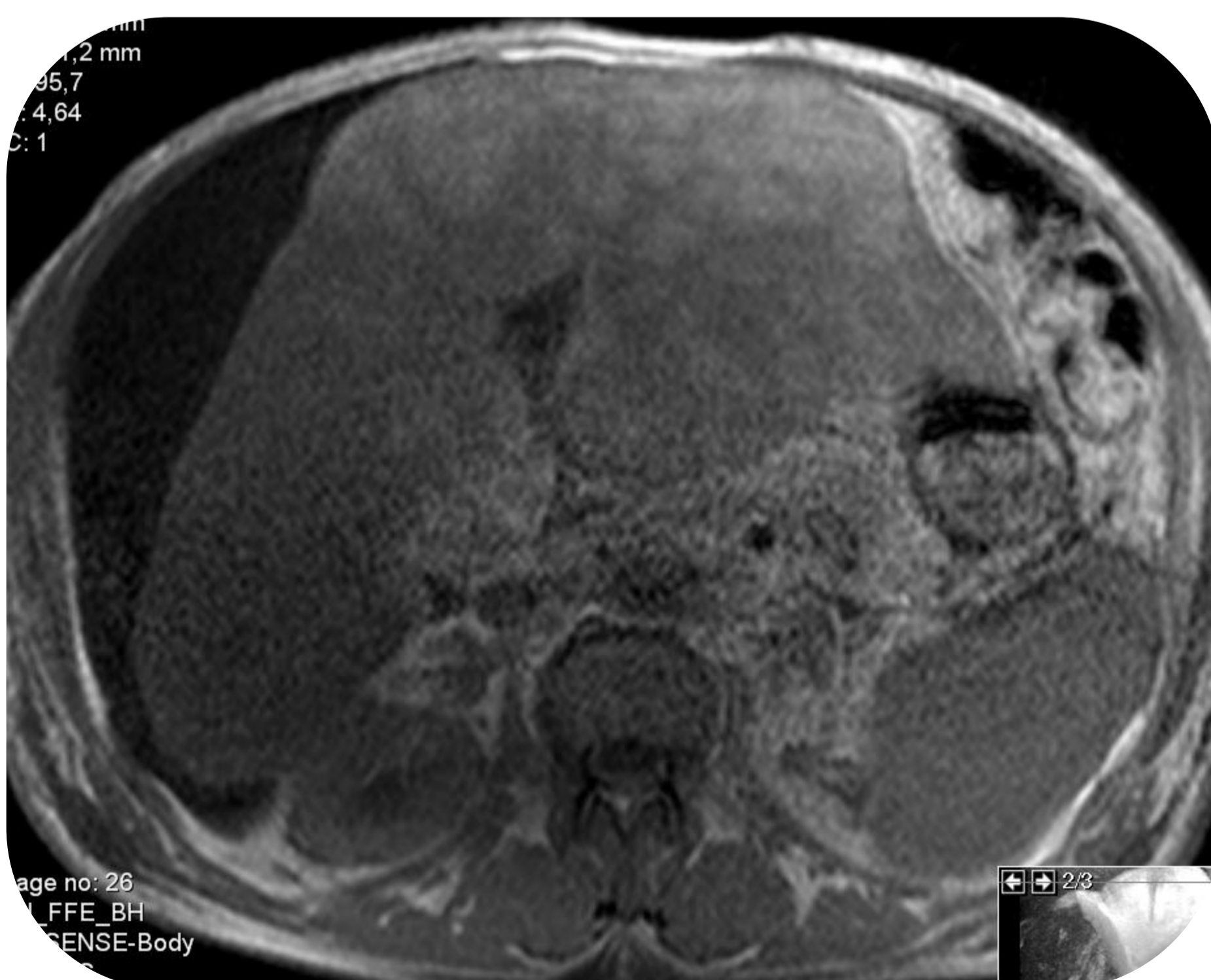
Comentário: Não se observam picos monoclonais

IgA	721	mg/dl	70-400
IgG	1020	mg/dl	700-1600
IgM	55,3	mg/dl	40-230

Proteinuria

Proteins (<0.15 g/24h)	5.4
------------------------	-----

Abdominal US: hepatomegaly (23 cm), bosselated and hyperechogenic eco-structure, diffusely derranged with no focal alterations. Moderate ascites. Kidneys with diminished parenchyma volume in favour of chronic nephropathy.



Liver biopsy – Hepatic deposition of AL amyloid substance.

For systemic AL amyloidosis with heart, liver and kidney involvement, **Dexamethasone** (100% dose) was started alongside **Cyclophosphamide** (33% dose) and **Bortezomib** (100% dose). Despite prompt action the patient died within days.

The clinical case enhances the importance of early investigation and capacity of integrating combined organ involvement and analytical changes to fit one consistent diagnosis.