



Review

Frontal lobe epilepsy

Pedro Beleza*, João Pinho

Epilepsy Group, Department of Neurology, Braga Hospital, Largo Carlos Amarante, Apartado 2242, Braga 4701-965, Portugal

ARTICLE INFO

Article history:

Received 13 January 2010

Accepted 7 August 2010

Keywords:

EEG

Frontal lobe epilepsy

Refractory epilepsy

SPECT

Surgery

Treatment

ABSTRACT

About one-quarter of patients with refractory focal epilepsies have frontal lobe epilepsy (FLE). The typical seizure semiology for FLE includes unilateral clonic, tonic asymmetric or hypermotor seizures. Interictal electroencephalograms (EEG) usually reveal interictal epileptiform discharges and rhythmical midline theta, which has localizing value. The usefulness of ictal EEG recordings is limited by frequent muscle artifacts in motor seizures and because a large portion of the frontal lobe cortex is “hidden” to scalp electrodes. Ictal single photon emission CT and positron emission tomography are able to localize FLE in about one-third of patients only. A pre-surgical evaluation should include, whenever possible, a subclassification of FLE as dorsolateral frontal, mesial frontal or basal frontal lobe epilepsy to allow a minimal cortical resection. A review of the typical findings of seizure semiology, interictal and ictal EEG regarding the different FLE subtypes is given. Etiology, medical treatment and surgery are also discussed.

© 2010 Elsevier Ltd. All rights reserved.

1. Introduction

Refractory epilepsy is diagnosed when there is inadequate seizure control despite use of potentially effective antiepileptic drugs (AED) at tolerable levels for 1–2 years. Once refractoriness is established, surgical treatment must be considered.¹ Of all patients with refractory focal epilepsies referred to epilepsy surgery, 25% have frontal lobe epilepsy (FLE).² The objective of resective surgery is the removal of the entire epileptogenic zone (EZ) without causing permanent neurological deficits. Given this objective, localization of the EZ is of paramount importance. This can be achieved by combining seizure semiology, interictal and ictal electroencephalogram (EEG) findings, as well as fluorodeoxyglucose (FDG)-positron emission tomography (PET), single photon emission CT (SPECT) and MRI.³

Unilateral clonic seizures,⁴ tonic asymmetric seizures with preserved consciousness⁵ and hypermotor seizures,⁴ while not pathognomonic, are specific for FLE. Even though abdominal auras may occur in FLE, the evolution of an abdominal aura into an automotor seizure is typical of temporal lobe epilepsy (TLE), which allows its differentiation from FLE.⁶ The presence of a visual aura strongly argues against an FLE, since visual auras are associated with parietal, temporal or occipital lobe epilepsy.⁷ Given that an ictal EEG from a patient with FLE is characterized by frequent false negatives and frequent muscle artifacts,⁸ the analysis of ictal semiology is crucial for the differential diagnosis between FLE and psychogenic non-epileptic seizures (PNES), the most frequent (~90%) condition

misdiagnosed as epilepsy.⁹ Certain characteristics of the motor phenomena are strongly associated with PNES, including a very gradual onset or termination, pseudosleep, discontinuous (stop-and-go) and irregular or asynchronous (out-of-phase) activity, side-to-side head shaking, opisthotonic posturing, stuttering and weeping.¹⁰

Interictal epileptiform discharges (IED) occur in 60% to 80% of FLE and are considered to be of less localizing value than in TLE because they can be bilateral, multilobar or even generalized.¹¹ Interictal rhythmical midline theta (RMT) is common (~50% of FLE patients) and has localizing value in patients with FLE, provided that it can be distinguished from normal variants occurring with drowsiness and mental activation tasks.¹² Ictal EEG is often generalized and localized patterns are observed in fewer than one-third of patients (Fig. 1).¹³

Localization of seizure onset with ictal SPECT in adults is possible in only 30% to 43% of patients with FLE.¹⁴ With the use of FDG-PET, it is possible to localize a hypometabolic region in about 75% of patients with unilateral FLE and abnormal MRI,¹⁵ but in only 29% to 45% of patients with unilateral FLE and normal MRI.¹⁶

FLE should be, whenever possible, further classified as dorsolateral frontal, mesial frontal or basal to allow minimal cortical resection.

2. Dorsolateral frontal lobe epilepsy

Dorsolateral FLE may be further subdivided into central, premotor and prefrontal lobe epilepsy. The central lobe is sometimes described as the region formed by the primary motor cortex and the sensory cortex (Brodmann areas 4 and 3) (Fig. 2). The border be-

* Corresponding author. Tel.: +35 1253209000.

E-mail address: beleza.76@gmail.com (P. Beleza).

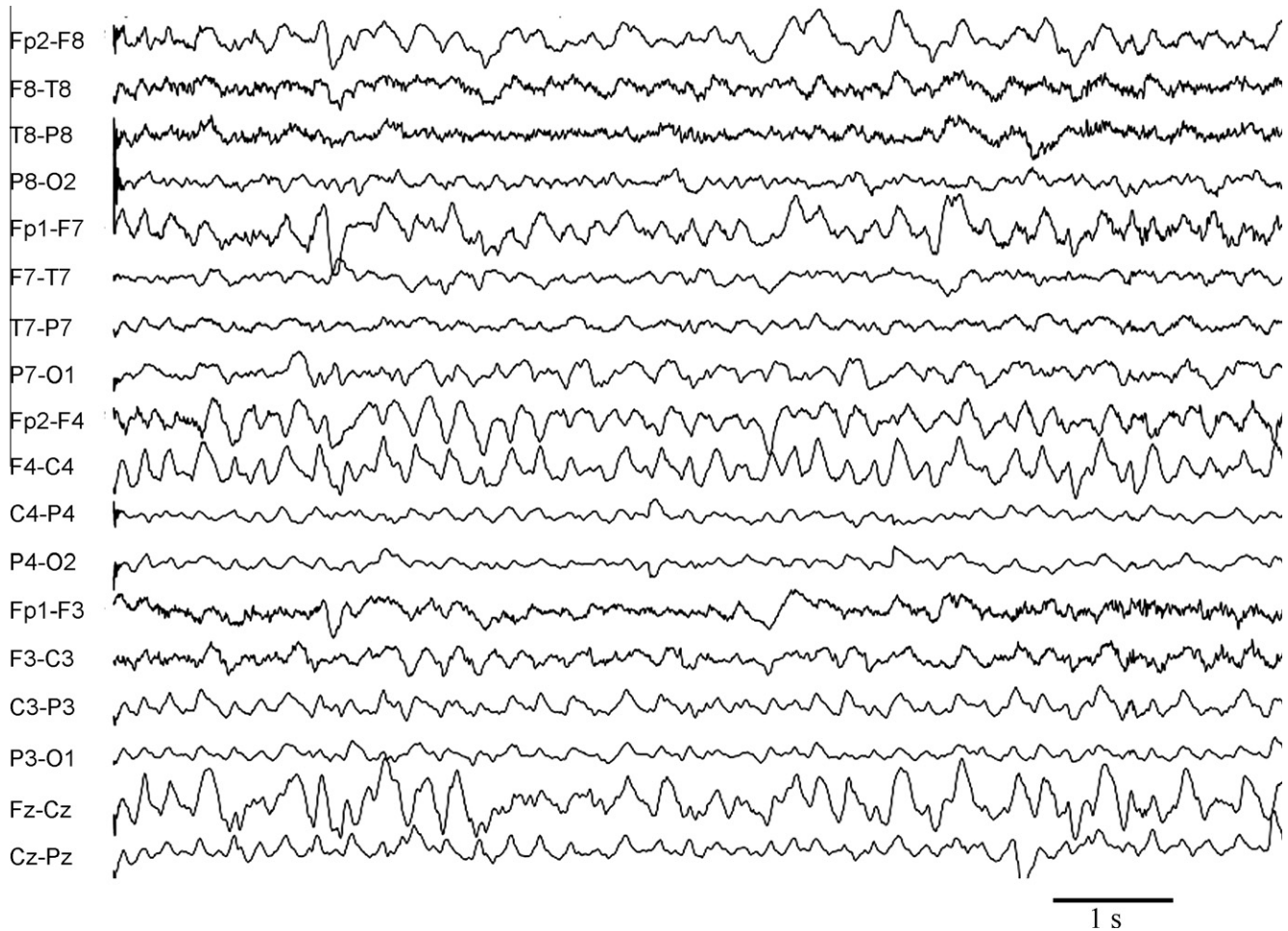


Fig. 1. Ictal electroencephalogram (EEG) in longitudinal bipolar montage of a 16-year-old female with a ring chromosome 20 syndrome. The EEG shows a predominantly right frontal seizure pattern occurring during a dyscognitive seizure.

tween these motor and sensory areas was thought to be the central sulcus, but recent studies showed both motor (tonic, clonic or mo-

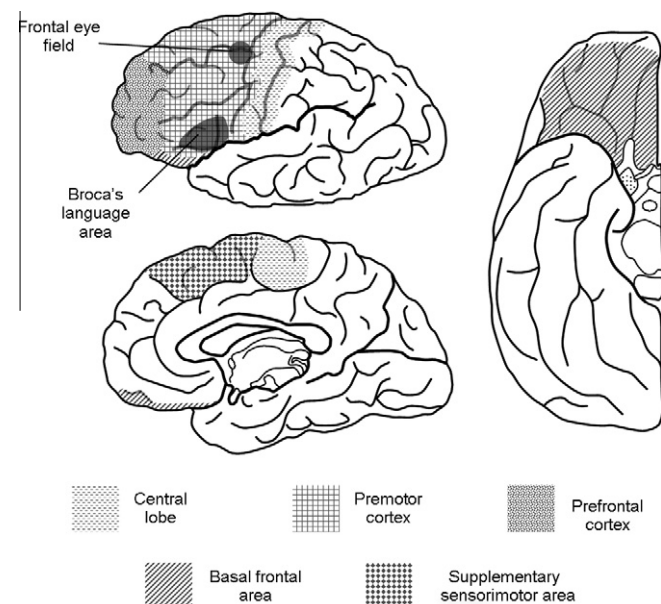


Fig. 2. Brain anatomy diagram (upper left) lateral, (lower left) mesial and (right) inferior views showing the localization of important functional areas of the dominant frontal lobe.

tor arrest) and sensory responses after electrical stimulation of the gyrus precentralis and gyrus postcentralis.¹⁷ Functionally, the premotor cortex (Fig. 2) includes the secondary motor area (posterior parts of the frontal gyri), the frontal eye field (intersection of sulcus precentralis and superior frontal sulcus) and Broca's language area (opercular and triangular parts of the inferior frontal gyrus in the dominant hemisphere). The premotor cortex projects to the primary motor cortex and, less extensively, to the motor systems of the spinal cord, and there is evidence in animal studies supporting its role in motor preparation and motor learning.¹⁸ Extensive frontal lobe resections up to the precentral sulcus, sparing the supplementary motor area, do not lead to any permanent or even transient motor disturbance.¹⁹ The prefrontal cortex (Fig. 2) is involved in emotion processing, moral behaviour, executive control, monitoring in working memory, learning and temporal structuring of behavior by context.²⁰ Even though some hypotheses propose that individualized tasks are carried out by the prefrontal cortex, this brain region might be responsible for the coordination of information processing and transfer, required for occurrence of multiple high-level cognitive operations.²¹

2.1. Seizure semiology

2.1.1. Central lobe

Although non-specific auras occur in most patients with FLE, focal somatosensory auras, more commonly unilateral paresthesias ("tingling", "numbness" or "strange feeling" sensations) restricted to the hand, the face/tongue or the foot, are specific to contralateral

involvement of the central lobe.⁴ Likewise, unilateral myoclonic or clonic seizures, more frequently affecting distal segments of the body (such as the face or tongue), are generally also the expression of the epileptic activation of the contralateral central lobe. As for electrical stimulation of the primary motor area, it usually does not cause tonic contractions, but rather clonic twitching of the affected muscles. The pathogenesis of clonic seizures, which consists primarily of repetitive myoclonic jerks, is probably very similar to that of myoclonic seizures.²² Typical seizure evolution includes: (i) focal clonic seizures with Jacksonian march without secondary generalization, usually accompanied by ipsilateral head version and followed by postictal paresis; and (ii) somatosensory aura often followed by tonic posturing and head version or clonic seizures; automatisms and vocalization are rare.⁴

2.1.2. Premotor cortex

Typical seizure evolution associated with lesions of the premotor cortex includes early versive seizure, frequently followed by other motor manifestations such as automatisms.

Versive seizures, characterized by lateral deviation of the eyes (tonic or saccadic), version of the head and, frequently, also of the trunk, especially when followed by a secondary generalized tonic-clonic seizure, indicate an epileptic activation of the frontal eye field contralateral to the side of eye deviation.²³ Aphasical seizures may occur if Broca's language area is involved. Long-lasting postictal aphasia is seen in >90% of seizures starting in the frontal lobe of the dominant side that spreads to the ipsilateral temporal lobe.²⁴

2.1.3. Prefrontal cortex

Hypermotor seizures were defined by Lüders et al.²⁵ as complex movements involving trunk and proximal limb segments, usually with the preservation of consciousness, and are considered specific for FLE, in close association with frontopolar and orbitofrontal cortical lesions.⁴ This type of seizure is frequently preceded by an aura (fear, ill-defined feelings, and somatosensory phenomena) and includes bizarre gestures, repetitive movements, bicycle peddling, pelvic thrusting and shouting, often charged with emotional and aggressive features. Hypermotor seizures are usually short and tend to occur during sleep. Unlike seizures involving the central lobe, the complex semiology of prefrontal seizures may be caused by disruption of neuronal synchrony between different brain regions rather than by excitation of single areas of the cortex.²⁶

2.2. Interictal EEG

A concordant EZ and irritative zone was found in 72% of patients with dorsolateral FLE compared to 33% with mesial FLE (Fig. 3).²⁷ Possible reasons for this difference are the smaller distance between lateral cortex and scalp electrodes and that the dipoles tangential to the scalp in mesial FLE cannot be detected by EEG. The sensitivity of interictal EEG is higher in intracranial subdural than in scalp recordings. Due to the closer distance to the cortex, subdural electrodes may reveal a smaller irritative zone in some patients, when compared to surface electrodes. However, a sampling bias remains in invasive monitoring studies.²⁸

2.3. Ictal EEG

Ictal scalp EEG in 127 seizures of 15 patients with dorsolateral FLE showed correct localization of the EZ in 65% of patients, while 26% of seizures started with generalized EEG activity and 3% were mislateralized in EEG analysis.²⁹ In this study only 1.5% of the seizures was obscured by artifacts or did not show EEG changes. The most frequent EEG patterns at seizure onset were repetitive epileptiform activity (36%), rhythmic delta (26%) and EEG suppression

(14%), in contrast to rhythmical theta activity, the most frequent seizure pattern in TLE, which was seen in only 9% of the 127 seizures. A study comparing medial ($n = 5$) with dorsolateral ($n = 4$) patients with FLE found that absence of focal electrographic seizure activity excluded the possibility of dorsolateral frontal lobe seizures with a negative predictive value of 93%, but this conclusion may be misleading because of the small number of study participants.¹³ Several authors have reported that, although scalp electrodes showed widespread seizure onset and MRI was normal or non-localizing, the use of subdural grid electrodes that extensively covered the frontal areas was able to localize the seizure onset zone in >90% of patients.³⁰

3. Mesial frontal epilepsy

The mesial surface of the frontal lobe includes primary sensory and motor cortex for the lower limb, the supplementary sensorimotor area (SSMA), the anterior cingulate cortex and the prefrontal cortex³¹ (Fig. 2). The SSMA extends anteriorly approximately to the level of the genu of the corpus callosum. SSMA stimulation results in usually bilateral and proximal tonic posturing and motor responses, but frequently show predominance on the contralateral side. Additionally, contralateral sensory phenomena may occur. The SSMA has a somatotopic distribution: the head and upper limbs are represented at the anterior and the lower limbs at the posterior surface of the interhemispheric region. Stimulation of the anterior portion of the SSMA results in arrest or slowing of voluntary motor activity. Furthermore, stimulation of the cingulate gyrus near the SSMA leads to motor responses that overlap those occurring in the SSMA,³² but automatisms, namely oro-alimentary, have also been described.³³

3.1. Seizure semiology

A somatosensory aura consisting of "tingling" or a feeling of tension, pulling or heaviness in a limb or the impression of impending movement of the limb may precede the tonic seizure. The sensation may be relatively focal, involving a portion of a limb, lateralized with both upper and lower limbs involved simultaneously, or a poorly defined bilateral sensation in the head or body.³⁴ The symptoms may arise from the sensory representation within the SSMA³² or may be the awareness of tension developing in muscle groups involved in the tonic contraction. Bilateral asymmetric tonic seizures are characterized by an abrupt onset of tonic posturing maintained for 10 s to 40s and absence of any postictal stupor or confusion.³⁵ Penfield and Jasper described "the arm being raised and the head and eyes turned as though to look at the hand", which is called the "fencing posture".³⁶ Moreover, Ajmone-Marsan and Ralston created the term "M2e" to describe tonic abduction and external rotation of the shoulder with flexion of the elbow. They described SSMA involvement if M2e posturing occurred without loss of consciousness and without progression into a secondarily generalized tonic-clonic seizure.³⁷ Although asymmetric tonic seizure is typically associated with mesial FLE, it is not specific.³⁸ Tonic seizures arising from the SSMA preferentially affect muscle groups on both sides of the body, yet, they more often predominate in the contralateral musculature.³⁹ In most patients with focal epilepsy, consciousness remains unclouded during tonic seizures, at least at the onset of seizures.³⁹ Strictly unilateral tonic seizures have a highly lateralizing significance, pointing to a contralateral seizure onset.³⁹ Other distinct semiologies may also be associated with mesial frontal lobe onset, including: hypermotor seizures, dialeptic seizures, focal clonic seizures of the lower limb and negative myoclonus. However, hypermotor seizures do not have a highly localizing value in the frontal lobe, since orbitofrontal,⁴⁰

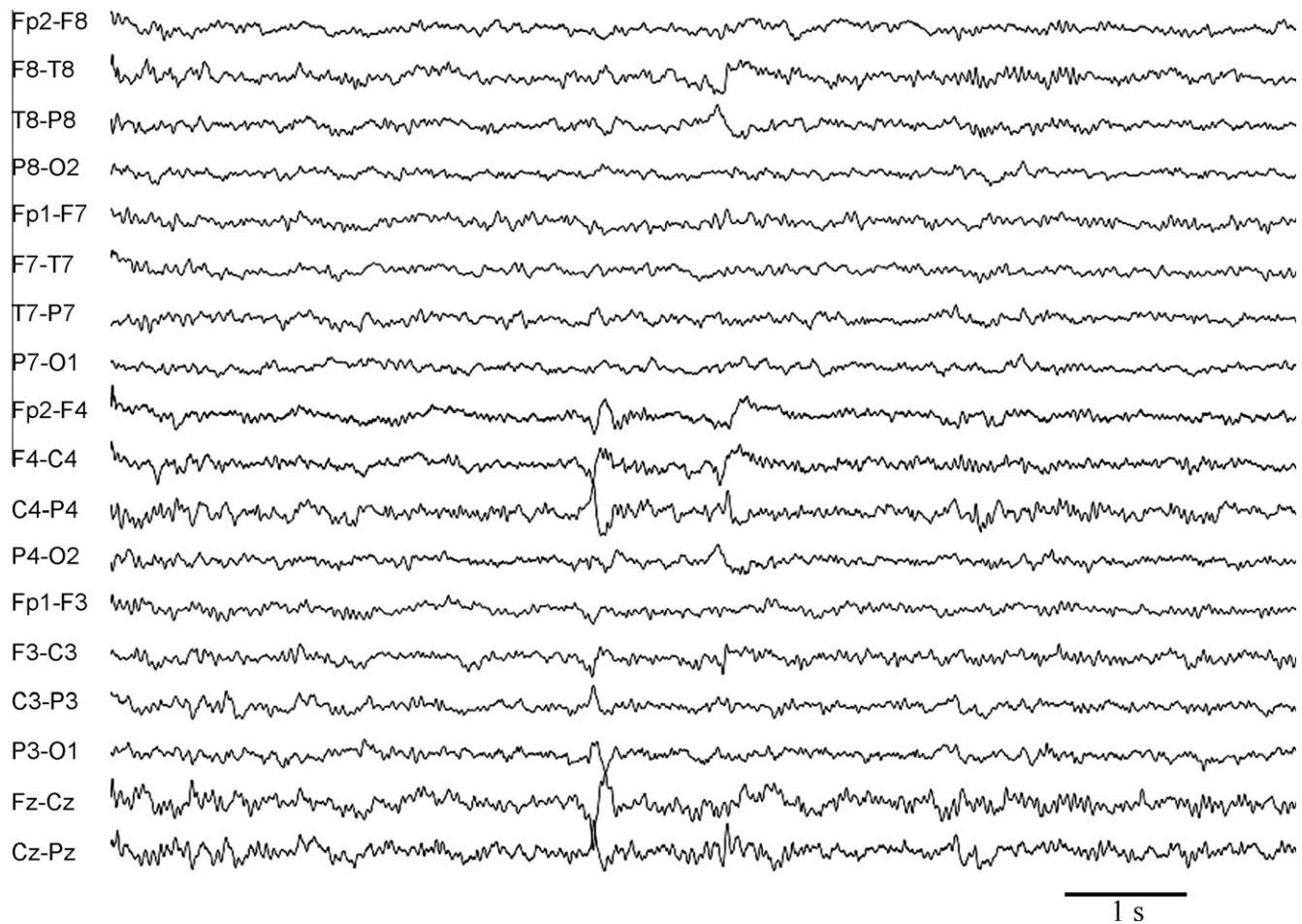


Fig. 3. Interictal electroencephalogram (EEG) in longitudinal bipolar montage of a 16-year-old female with a right frontal epilepsy due to right inferior frontal gyrus cortical dysplasia. The EEG shows sharp waves involving right central and midline central regions.

dorsolateral frontal,¹¹ frontopolar and opercular–insular⁴¹ seizure onset have all been reported. While seizure onset in several frontal regions may produce this seizure semiology, the anterior cingulate region has been frequently proposed as the cortical region responsible for the clinical signs and symptoms. Dialeptic seizures, as defined by Lüders et al.,²⁵ consist of episodes with loss of consciousness, during which a patient cannot react or reacts only to a limited extent to external stimuli and shows minimal motor activity. Dialeptic seizures are rare in patients with FLE and were termed “frontal absences” due to their resemblance to dialeptic seizures in patients with generalized epilepsies (“absence”). In contrast to childhood absences, patients with frontal lobe absences may have subtle repetitive vocalizations, rocking movements, small degrees of head and eye turning, report awareness of a motor arrest without loss of consciousness and have brief postictal confusion.⁴¹ Staring may evolve into a generalized tonic–clonic seizure via version of the head and eyes, focal tonic posturing of an upper limb or bilateral tonic posturing. Patients with dialeptic seizures in FLE seem to have a more anterior EZ than those with bilateral asymmetric tonic seizures.⁴¹ This clinical semiology has been ascribed to bilateral cingulate gyrus involvement via the callosal route.⁴² Negative myoclonic seizure consists of short phases of muscle atonia (30–400 ms), which are preceded by epileptiform discharges in the central region (20–30 ms). Generalized and focal negative myoclonic seizures have also been reported.⁴³ Several reports indicate that these seizures are caused by the sudden inhibition of tonic innervation of motor neurons, as evidenced by the silent electromyogram (EMG) period. Recent studies showed that

SSMA stimulation induces silent periods only, regardless of the stimulus intensity, whereas occurrence of silent periods following stimulation of the premotor cortex, primary motor cortex or primary somatosensory area depended mainly on the intensity of stimulation.⁴⁴ Gelastic seizures are seizures characterized by ictal laughing, sometimes accompanied by mirth, that frequently occur in patients with hypothalamic hamartomas.⁴⁵ The anteromesial superior frontal gyrus and anterior cingulate gyrus have been described as involved in motor aspects of laughter,⁴⁶ while the temporal lobes, particularly the basal regions, seem to be mainly involved in the processing of mirth.⁴⁷

3.2. Interictal EEG

The interictal EEG in patients with mesial FLE generally shows either abundance of non-lateralised epileptiform activity or none at all.⁴⁸ Focal IED at or adjacent to the midline have been reported in patients with tonic postural seizures.³⁵ Blume and Oliver⁴⁹ found that about 50% of patients ($n = 13$) with “supplementary motor area epilepsy” show midline (Fz, Cz) (five patients) or frontal (F4, F3) (two patients) spike foci. EEG analysis with transverse montages and using midline electrodes Fz, Cz and Pz is essential, as maximal discharges at these electrodes may have a limited field.⁴⁹ In addition, bilateral frontal synchronous discharges are characteristic, but not specific, of mesial FLE.⁴⁰ A recent study showed that all mesial FLE patients ($n = 4$, established by invasive EEG recordings) were characterised by interictal RMT, but this finding was less frequent in other FLE patients (44%, 22 of 50), pro-

viding evidence that RMT may be a neurophysiological marker for mesial frontal lobe abnormality.¹² Nevertheless, replication of these results by further studies with a larger cohort of patients is needed. RMT is seen in patients with bilateral asymmetric tonic seizures and in patients with midline parasagittal epileptic discharges.⁵⁰

3.3. Ictal EEG

Muscle activity is prominent from the onset of bilateral asymmetric tonic seizures and the EEG is frequently contaminated with considerable EMG and movement artifacts. Seizure patterns may still be evident at the vertex, where EMG activity is minimal. Absence of any ictal or immediate postictal EEG slowing has been reported in patients with mesial FLE.¹³ In the study by Foldvary et al., just over 50% of the seizures analyzed were obscured or showed no EEG change in the mesial frontal lobe epilepsy patients, an uncommon occurrence in the other focal epilepsy groups.²⁹ Characteristic findings include an initial high amplitude slow wave transient or midline sharp wave, followed by bilateral frontocentral low voltage fast activity or electrodecreeent.⁵¹ Accordingly, one study reported that seizures from the mesial frontal lobe more frequently showed paroxysmal fast activity (33%) or electrodecreeent (29%) as the initial ictal pattern.²⁹ Electrodecreeent will usually evolve into low voltage fast activity and then bilateral frontocentral or generalized rhythmic theta slowing.⁵² The low voltage fast activity and the rhythmic slow activity may be either localized in the vertex or be more diffuse. Subtle lateralization of these rhythms may occur but, in general, the lateralizing information from ictal EEG is minimal. Indeed, it has been shown that only 25% of mesial FLE seizures correctly localized or lateralized on EEG and 75% had non-lateralised patterns.²⁹ When indicated, intracranial EEG with depth electrodes, usually placed bilaterally, provides greater accuracy for lateralization and localization, but also carries a significant risk of parenchymal hemorrhage.

4. Basal frontal lobe epilepsy

On the basal (orbital) surface of the frontal lobes, five gyri can be identified: lateral orbital gyrus, anterior and posterior orbital gyri, medial orbital gyrus and gyrus rectus¹⁹ (Fig. 2). The posterior part of the orbitofrontal region is continuous with the rostral part of the agranular insula, and is hence regarded as more “limbic” in character. However, the rostrally placed isocortical orbitofrontal region has features of granular isocortex and blends into the dorso-lateral heteromodal components of the prefrontal cortex.⁵³

4.1. Seizure semiology

Olfactory auras, usually described by patients as unpleasant, are frequently an expression of epileptic activation of the orbitofrontal part of the gyrus rectus.⁵⁴ Autonomic seizures may also occur, and consist of ictal events during which the main abnormality is an objective autonomic change including cardiovascular (tachycardia, bradycardia, asystole, arrhythmia), respiratory (hyperventilation, apnea, dyspnea and stridor), gastrointestinal (epigastric aura, vomiting, spitting, defecation), cutaneous (piloerection, pallor, flushing), papillary (mydriasis, miosis) or urogenital (urinary urge, sexual/orgasmic aura, genital aura, sexual and genital automatisms) manifestations. To document its epileptic nature, a simultaneously recorded EEG seizure pattern is usually required. Ictal “vegetative” manifestations are thought to result from activation of the orbitofrontal and opercular insular regions.⁴¹ Hypermotor seizures are also common, although not specifically associated with this region.

4.2. Interictal and ictal EEG

Typically, abnormalities detected by scalp EEG do not allow for topographic localization of foci residing in the basal frontal lobe, mostly due to the inaccessibility of the basal frontal surface to scalp electrodes. When present, IED may have a regional distribution or appear generalized as a result of secondary bilateral synchrony. Case reports by Ludwig and co-workers highlighted the occurrence of bilaterally synchronous epileptiform discharges, with a bifrontal or frontopolar maximum, as well as discharges involving one anterior quadrant, with or without evidence of additional temporal lobe involvement.⁵⁵ In a single patient with orbitofrontal epilepsy described by Chang et al., the use of invasive recordings showed that sphenoidal recordings were able to lateralize the EZ, and the infraorbital scalp electrodes added to the scalp EEG revealed that the observed bisynchronous discharges had a more basal distribution with a maximum in the infraorbital regions.⁵⁵ False localization to the anterior temporal region is not uncommon in patients with basal frontal epilepsies.⁵⁶ Occasionally, propagated epileptiform activity can be present over central or frontolateral regions. Moreover, epileptiform abnormalities may have a misleadingly widespread appearance because of the large distance and intervening cortical area that separates the EZ from the scalp EEG electrodes.⁵⁴

5. Etiology

In a study of 68 patients with FLE who underwent frontal lesionectomy, the histopathological findings were: tumors in 24 patients (35%) (glioneural tumors, 8; astrocytic tumors, 15; and osteoma, 1), dysgenetic lesions in 18 patients (26%) (glioneural hamartoma, 15; cortical dysplasia, 1; cortical subcortical disorganization, 1; ectopic cortical neurons, 1), gliosis in 14 patients (21%), vascular malformations in 10 patients (15%) (cavernomas, 6; arteriovenous malformations, 4), encephalitis in one patient (1.5%) and necrosis in one patient (1.5%).⁵⁷ The Cleveland Clinic series included 70 patients with FLE who underwent a frontal lobectomy between 1995 and 2003. Based on MRI and surgical pathology, patients were divided into the following etiological subgroups: (i) malformation of cortical development (MCD) with abnormal MRI (41% of patients); (ii) MCD with normal high-resolution MRI (17%); (iii) tumor (19%); (iv) vascular malformation (3%); (v) cryptogenic with normal MRI and histology (10%); and (vi) encephalomalacia following stroke or trauma (10%).⁵⁸ MRI-negative MCD as a disease etiology proved to be an independent predictor of seizure recurrence after frontal lobectomy.⁵⁸ Another study found that of a total of 21 patients with refractory nocturnal FLE submitted to surgery, 20 (95%) patients had focal cortical dysplasia detected on histological examination (including one patient with familial pedigree suggestive of autosomal dominant nocturnal FLE) and only 11 (52%) patients showed frontal lobe abnormalities on MRI. Invasive recording by stereo-EEG was performed in 18 (86%) patients.⁵⁹ The main genetic cause of FLE is autosomal dominant nocturnal FLE (ADNFLE), a channelopathy inherited with incomplete (70%) penetrance resulting from mutations in genes coding for subunits of the nicotinic acetylcholine receptor.⁶⁰ Clinically available molecular genetic testing reveals mutations in *CHRNA4* or *CHRNA2* in approximately 10% to 20% of individuals with a positive family history and in fewer than 5% of individuals with a negative family history of ADNFLE.⁶⁰ Ring chromosome 20 should be suspected in patients with recurrent frontal status and normal MRI.⁶¹ Slight mental retardation or dysmorphism may also be found.⁶² A recent report described a patient with a ring chromosome 17 who presented with an epileptic syndrome similar to the

ring chromosome 20 syndrome, raising the question of overlap of ring chromosome epileptic syndromes.⁶³

6. Additional and experimental methods

Despite its low spatial resolution, MR spectroscopy may help to lateralize and even to localize epileptogenic frontal and central lobe lesions by detection of reduced N-acetylaspartate levels.⁶⁴ The area of decreased N-acetylaspartate concentration frequently exceeds the epileptogenic lesion as seen in MRI.⁶⁵ Diffusion tensor imaging may be helpful for detection of the epileptogenic lesion in patients without structural changes on conventional MRI, especially in patients with focal cortical dysplasia.⁶⁶ Furthermore, multiplanar reconstruction and curvilinear reformatting have been shown to improve the localization of focal cortical dysplasias in the frontal lobe.⁶⁷

7. Treatment of refractory FLE

7.1. Surgery

The algorithm used in our institution for pre-surgical evaluation of patients with FLE is outlined in Fig. 4. A FLE patient with a lesion not adjacent to the eloquent cortex, with a congruent EEG (ictal and interictal), seizure semiology, and neuropsychology evaluation may be submitted to resective surgery without the need for invasive monitoring if: (i) ictal EEG reveals a lateralized or localized seizure pattern; or (ii) ictal EEG is normal or contains artifacts but PET or ictal SPECT is localized. Invasive monitoring is recommended when there is: FLE without a lesion; a lesion adjacent to an eloquent cortex; no congruence between the different zones; or congruence but the ictal EEG is normal and the PET and ictal SPECT are not localized.³

Extratemporal lobe surgery for focal epilepsy accounts for less than 50% of all epilepsy surgeries.⁶⁸ In FLE surgery the probability of becoming seizure-free is 55.7% at 1 year, 45.1% at 3 years, and 30.1% at 5 years.⁵⁸ Mesial temporal lobe epilepsy (MTLE) associated with hippocampal sclerosis is the most common form of focal epilepsy, with around 60% of patients having anterior temporal lobe resections, of whom 60–70% are seizure free at 1–2 years of follow-up⁶⁹ but only 58% are seizure free at 10 years.⁷⁰ Patients with FLE and favorable prognostic factors (MRI lesion restricted

to one frontal lobe, complete resection, regional or lateralized ictal scalp EEG pattern) show a seizure-free outcome comparable to MTLE patients after temporal lobectomy, with 50% to 60% being seizure free at 3 years. Regarding etiology, patients with low-grade tumors have the best outcome (62%) followed by patients with MRI visible malformations of cortical development (52%).

7.2. Palliative interventions

Complete seizure control is virtually unachievable for some patients, but useful palliation can sometimes be achieved with techniques such as vagal nerve stimulation or multiple subpial transections.

Vagal nerve stimulation is indicated in adults with focal epilepsies who are not surgical candidates or who have had surgery performed without success. On average, a 50% reduction of seizure frequency has been reported in about one-third of patients, the same range of expected benefit if a new AED is added, with the advantage of lower adverse effects. However, seizure freedom is rare.⁷¹

Multiple subpial transections use radially oriented incisions in the grey matter at 4-mm intervals to limit propagation of epileptic activity within eloquent cortex and to reduce seizure spread without disturbing functional integrity. A significant seizure reduction has been reported.⁷²

A ketogenic diet, high in fat and low in carbohydrate, is mainly used in pediatric patients (due to questions of tolerability) as a second line treatment in focal non-surgical refractory epilepsy. A recent randomized controlled trial showed a reduction of seizure frequency of more than 50% in 38% of children with drug-resistant epilepsy.⁷³

In chronic epilepsies (more than 5 years) the addition of a previously unused AED provided seizure freedom in 17% and a 50% to 99% seizure reduction for 25%. For non-responders to the first trial, a similar benefit might be expected for at least two more trials. At the end, 28% of patients were seizure free.⁷⁴ Zonisamide (100–400 mg id), levetiracetam (1000–3000 mg id), lamotrigine (300–500 mg id), topiramate (300–1000 mg id) and gabapentine (600–1800 mg id) have demonstrated efficacy (evidence level A) as add-on therapy in patients with refractory focal epilepsy.⁷⁵ Even though the methodology was similar for all studies, a direct comparison between outcomes does not allow determination of the relative efficacy, because populations differed and some drugs were not used in maximum doses, whereas others appear to have been administered above the ideal dose. For essentially all drugs, efficacy as well as side effects increased with increasing doses.⁷⁵ In refractory epilepsy it is convenient to manage AED by: (i) increasing the dosage up to the maximum tolerable dose; (ii) if the patient is non-responsive, then replace the AED; if the patient responds partially, then add on an AED chosen according to the mechanism of action of the first AED (e.g. lamotrigine and valproate are synergistic), efficacy and adverse effects.⁷⁶

8. Conclusion

FLE is an important cause of refractory focal epilepsy and represents a substantial group of patients referred for epilepsy surgery. Seizure semiology, MRI, ictal EEG, interictal EEG and PET/SPECT should be judiciously analyzed to further classify the FLE as central, premotor, prefrontal, frontal mesial or frontal basal epilepsy. Accurate localization of the EZ and recognition of prognostic factors further contribute to the success in FLE surgery. Antiepileptic drugs, vagal nerve stimulation, a ketogenic diet and multiple subpial transections are beneficial in patients not eligible for resective surgery.

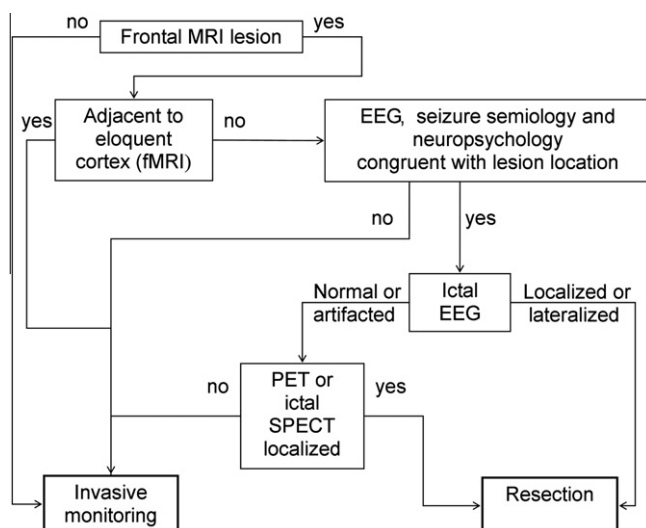


Fig. 4. Algorithm of investigations used in our institution for the pre-surgical evaluation of patients with frontal lobe epilepsy.

Acknowledgement

The authors acknowledge Dr. A. S. Costa for helpful English language editing assistance.

References

- Belezá P. Refractory epilepsy: a clinically oriented review. *Eur Neurol* 2009;**62**:65–71.
- Rasmussen T. Tailoring of cortical excisions for frontal lobe epilepsy. *Can J Neurol Sci* 1991;**18**:606–10.
- Rosenow F, Lüders H. Presurgical evaluation of epilepsy. *Brain* 2001;**124**:1683–700.
- Manford M, Fish DR, Shorvon SD. An analysis of clinical seizure patterns and their localizing value in frontal and temporal lobe epilepsies. *Brain* 1996;**119**:17–40.
- Quesney LF, Constain M, Fish DR, et al. The clinical differentiation of seizures arising in the parasagittal and anterolaterodorsal frontal convexities. *Arch Neurol* 1990;**47**:677–9.
- Henkel A, Noachtar S, Pfander M, et al. The localizing value of the abdominal aura and its evolution: a study in focal epilepsies. *Neurology* 2002;**58**:271–6.
- Noachtar S, Peters AS. Semiology of epileptic seizures: a critical review. *Epilepsy Behav* 2009;**15**:2–9.
- Lee SK, Kim JY, Hong KS, et al. The clinical usefulness of ictal surface EEG in neocortical epilepsy. *Epilepsia* 2000;**41**:1450–5.
- Benbadis SR, O'Neill E, Tatum WO, et al. Outcome of prolonged video-EEG monitoring at a typical referral epilepsy center. *Epilepsia* 2004;**45**:1150–3.
- Benbadis S. The differential diagnosis of epilepsy: a critical review. *Epilepsy Behav* 2009;**15**:15–21.
- Laskowitz DT, Sperling MR, French JA, et al. The syndrome of frontal lobe epilepsy: characteristics and surgical management. *Neurology* 1995;**45**:780–7.
- Belezá P, Bilgin O, Noachtar S. Intercital rhythmic midline theta differentiates frontal from temporal lobe epilepsies. *Epilepsia* 2009;**50**:550–5.
- Bautista RE, Spencer DD, Spencer SS. EEG findings in frontal lobe epilepsies. *Neurology* 1998;**50**:1765–71.
- Lee SK, Lee SY, Yun CH, et al. Ictal SPECT in neocortical epilepsies: clinical usefulness and factors affecting the pattern of hyperperfusion. *Neuroradiology* 2006;**48**:678–84.
- Rylyin P, Bouvard S, Le Bars D, et al. Clinical utility of flumazenil-PET versus [18F]fluorodeoxyglucose-PET and MRI in refractory partial epilepsy. A prospective study in 100 patients. *Brain* 1998;**121**:2067–81.
- Hamer HM, Morris HH, Mascha EJ, et al. Complications of invasive video-EEG monitoring with subdural grid electrodes. *Neurology* 2002;**58**:97–103.
- Nii Y, Uematsu S, Lesser RP, et al. Does the central sulcus divide motor and sensory functions? Cortical mapping of human hand areas as revealed by electrical stimulation through subdural grid electrodes. *Neurology* 1996;**46**:360–7.
- Kandel ER, Schwartz JH, Jessell TM. *Principles of neuroscience*. 3rd ed. New York: McGraw-Hill; 2000.
- Tamraz JC, Comair YG. *Atlas of regional anatomy of the brain using MRI*. Berlin: Springer; 2006.
- Bechara A, Damasio H, Tranel D, et al. Deciding advantageously before knowing the advantageous strategy. *Science* 1997;**275**:1293–5.
- Ramrani N, Owen AM. Anterior prefrontal cortex: insights into function from anatomy and neuroimaging. *Nat Rev Neurosci* 2004;**5**:184–94.
- Noachtar S, Lüders HO. Classification of epileptic seizures and epileptic syndromes. In: Giltenberg PL, Tasker RR, editors. *Textbook of stereotactic and functional neurosurgery*. New York: McGraw-Hill; 1997. p. 1763–74.
- Rheims S, Demarquay G, Isnard J, et al. Ipsilateral head deviation in frontal lobe seizures. *Epilepsia* 2005;**46**:1750–3.
- Goldberg-Stern H, Gadoth N, Cahill W, et al. Language dysfunction after frontal lobe partial seizures. *Neurology* 2004;**62**:1637–8.
- Lüders H, Acharya J, Baumgartner C, et al. A new epileptic seizure classification based exclusively on ictal semiology. *Acta Neurol Scand* 1999;**99**:137–41.
- Bartolomei F, Trebuchon A, Gavaret M, et al. Acute alteration of emotional behaviour in epileptic seizures is related to transient desynchrony in emotion-regulation networks. *Clin Neurophysiol* 2005;**116**:2473–9.
- Vadlamudi L, So EL, Worrell GA, et al. Factors underlying scalp-EEG interictal epileptiform discharges in intractable frontal lobe epilepsy. *Epileptic Disord* 2004;**6**:89–95.
- Salanova V, Morris 3rd HH, Van Ness PC, et al. Comparison of scalp electroencephalogram with subdural electrocorticogram recordings and functional mapping in frontal lobe epilepsy. *Arch Neurol* 1993;**50**:294–9.
- Foldvary N, Klem G, Hammel J, et al. The localizing value of ictal EEG in focal epilepsy. *Neurology* 2001;**57**:2022–8.
- Cukiert A, Buratini JA, Machado E, et al. Results of surgery in patients with refractory extratemporal epilepsy with normal or nonlocalizing magnetic resonance findings investigated with subdural grids. *Epilepsia* 2001;**42**:889–94.
- Donoghue JP, Sanes JN. Motor areas of the cerebral cortex. *J Clin Neurophysiol* 1994;**11**:382–96.
- Lim SH, Dinner DS, Pillay PK, et al. Functional anatomy of the human supplementary sensorimotor area: results of extraoperative electrical stimulation. *Electroencephalogr Clin Neurophysiol* 1994;**91**:179–93.
- Unnwongse K, Lachhwani D, Tang-Wai R, et al. Oral automatisms induced by stimulation of the mesial frontal cortex. *Epilepsia* 2009;**50**:1620–3.
- Bleasel AF, Morris HH. Supplementary sensorimotor area epilepsy in adults. In: Lüders HO, editor. *Advances in neurology*. Philadelphia: Lippincott-Raven; 1996. p. 271–84.
- Morris 3rd HH, Dinner DS, Lüders H, et al. Supplementary motor seizures: clinical and electroencephalographic findings. *Neurology* 1988;**38**:1075–82.
- Penfield W, Jasper H. *Epilepsy and the functional anatomy of the human brain*. Boston: Little Brown; 1954.
- Ajmone-Marsan C, Ralston BL. *The epileptic seizure. Its functional morphology and diagnostic significance*. Springfield, IL, USA: Charles C. Thomas; 1957.
- Williamson PD. Frontal lobe epilepsy. Some clinical characteristics. *Adv Neurol* 1995;**66**:127–52.
- Werhahn KJ, Noachtar S, Arnold S, et al. Tonic seizures: their significance for lateralization and frequency in different focal epileptic syndromes. *Epilepsia* 2000;**41**:1153–61.
- Harvey AS, Hopkins IJ, Bowe JM, et al. Frontal lobe epilepsy: clinical seizure characteristics and localization with ictal 99mTc-HMPAO SPECT. *Neurology* 1993;**43**:1966–80.
- Bancaud J, Talairach J. Clinical semiology of frontal lobe seizures. In: Chauvel P, Delgado-Escueta AV, Halgren E, Bancaud J, editors. *Frontal lobe seizures and epilepsies*. New York: Raven Press; 1992. p. 3–58.
- Huck FR, Radvány J, Avila JO, et al. Anterior callosotomy in epileptics with multiform seizures and bilateral synchronous spike and wave EEG pattern. *Acta Neurochir Suppl (Wien)* 1980;**30**:127–35.
- Werhahn KJ, Noachtar S. Epileptic negative myoclonus. In: Lüders HO, Noachtar S, editors. *Epileptic seizures: pathophysiology and clinical semiology*. New York: Churchill Livingstone; 2000. p. 473–83.
- Rubboli G, Mai R, Meletti S, et al. Negative myoclonus induced by cortical electrical stimulation in epileptic patients. *Brain* 2006;**129**:65–81.
- Arroyo S, Santamaria J, Sanmarti F, et al. Ictal laughter associated with paroxysmal hypothalamic dysfunction. *Epilepsia* 1997;**38**:114–7.
- Unnwongse K, Wehner T, Bingaman W, et al. Gelastic seizures and the anteromesial frontal lobe: A case report and review of intracranial EEG recording and electrocortical stimulation case studies. *Epilepsia* 2010;**51**:2195–8.
- Arroyo S, Lesser RP, Gordon B, et al. Mirth, laughter and gelastic seizures. *Brain* 1993;**116**:757–80.
- Williamson PD, Spencer DD, Spencer SS, et al. Complex partial seizures of frontal lobe origin. *Ann Neurol* 1985;**18**:497–504.
- Blume WT, Oliver L. Noninvasive electroencephalography in the evaluation of supplementary sensorimotor area epilepsy. *Adv Neurol* 1996;**70**:309–17.
- Pedley TA, Tharp BR, Herman K. Clinical and electroencephalographic characteristics of midline parasagittal foci. *Ann Neurol* 1981;**9**:142–9.
- Jobst BC, Siegel AM, Thadani VM, et al. Intractable seizures of frontal lobe origin: clinical characteristics, localizing signs, and results of surgery. *Epilepsia* 2000;**41**:1139–52.
- Bleasel A. *Studies in electroencephalography*. Sydney: University of Sydney; 1997. p. 169–74.
- Cavada C, Company T, Tejedor J, et al. The anatomical connections of the macaque monkey orbitofrontal cortex. A review. *Cereb Cortex* 2000;**10**:220–42.
- Ebner A. Epilepsy syndromes in adults. In: Lüders HO, editor. *Epilepsy: comprehensive review and case discussions*. London: Martin Dunitz; 2001. p. 169–79.
- Chang CN, Ojemann LM, Ojemann GA, et al. Seizures of fronto-orbital origin: a proven case. *Epilepsia* 1991;**32**:487–91.
- Walczak T. Intercital EEG. In: Engel Jr J, Pedley TA, editors. *Epilepsy: a comprehensive textbook*, vol. 1. Philadelphia, USA: Lippincott-Raven; 1998. p. 831–48.
- Schramm J, Kral T, Kurthen M, et al. Surgery to treat focal frontal lobe epilepsy in adults. *Neurosurgery* 2002;**51**:644–55.
- Jeha LE, Najm I, Bingaman W, et al. Surgical outcome and prognostic factors of frontal lobe epilepsy surgery. *Brain* 2007;**130**:574–84.
- Nonbili L, Francione S, Mai R, et al. Surgical treatment of drug-resistant nocturnal frontal lobe epilepsy. *Brain* 2007;**130**:561–73.
- Combi R, Dalpra L, Tenchini ML, et al. Autosomal dominant nocturnal frontal lobe epilepsy – a critical overview. *J Neurol* 2004;**251**:923–34.
- Inoue Y, Fujiwara T, Matsuda K, et al. Ring chromosome 20 and nonconvulsive status epilepticus. A new epileptic syndrome. *Brain* 1997;**120**:939–53.
- Garcia DM, Ortiz R, Gomez A, et al. Ring 20 chromosome syndrome with epilepsy and dysmorphic features: a case report. *Epilepsia* 2001;**42**:1607–10.
- Ricard-Mousnier B, N'Guyen S, Dubas F, et al. Ring chromosome 17 epilepsy may resemble that of ring chromosome 20 syndrome. *Epileptic Disord* 2007;**9**:327–31.
- Lundbom N, Gaily E, Vuori K, et al. Proton spectroscopic imaging shows abnormalities in glial and neuronal cell pools in frontal lobe epilepsy. *Epilepsia* 2001;**42**:1507–14.
- Li LM, Cendes F, Andermann F, et al. Spatial extent of neuronal metabolic dysfunction measured by proton MR spectroscopic imaging in patients with localization-related epilepsy. *Epilepsia* 2000;**41**:666–74.
- Walczak TS, Radtke RA, Lewis DV. Accuracy and interobserver reliability of scalp ictal EEG. *Neurology* 1992;**42**:2279–85.
- Dlugos DJ, Sperling MR. Propagation of neocortical extratemporal seizures. *Adv Neurol* 2000;**84**:287–97.
- Mosewich RK, So EL, O'Brien TJ, et al. Factors predictive of the outcome of frontal lobe epilepsy surgery. *Epilepsia* 2000;**41**:843–9.

69. Wiebe S, Blume WT, Girvin JP, et al. A randomized, controlled trial of surgery for temporal-lobe epilepsy. *N Engl J Med* 2001;**345**:311–8.
70. Jeha LE, Najm IM, Bingaman WE, et al. Predictors of outcome after temporal lobectomy for the treatment of intractable epilepsy. *Neurology* 2006;**66**:1938–40.
71. Morris 3rd GL, Mueller WM. Long-term treatment with vagus nerve stimulation in patients with refractory epilepsy. The Vagus Nerve Stimulation Study Group E01-E05. *Neurology* 1999;**53**:1731–5.
72. Spencer S, Huh L. Outcomes of epilepsy surgery in adults and children. *Lancet Neurol* 2008;**7**:525–37.
73. Neal EG, Chaffe H, Schwartz RH, et al. The ketogenic diet for the treatment of childhood epilepsy: a randomised controlled trial. *Lancet Neurol* 2008;**7**:500–6.
74. Luciano AL, Shorvon SD. Results of treatment changes in patients with apparently drug-resistant chronic epilepsy. *Ann Neurol* 2007;**62**:375–81.
75. French JA, Kanner AM, Bautista J, et al. Efficacy and tolerability of the new antiepileptic drugs II: treatment of refractory epilepsy: report of the Therapeutics and Technology Assessment Subcommittee and Quality Standards Subcommittee of the American Academy of Neurology and the American Epilepsy Society. *Neurology* 2004;**62**:1261–73.
76. Brodie MJ. Diagnosing and predicting refractory epilepsy. *Acta Neurol Scand Suppl* 2005;**181**:36–9.