



**Hospital  
Braga**

# 14th EURETINA Congress LONDON

11-14 September 2014

## Methylene Tetrahydrofolate Reductase (MTHFR) Gene Mutations associated with Retinal Vein Occlusion

**Luís Mendonça, Keissy Sousa, Ricardo Dourado Leite, José Carlos Mendes, Fernando Vaz**

Hospital de Braga, Braga, Portugal

**PURPOSE:** Description of two cases of central retinal vein occlusion (CRVO) in young patients with methylene tetrahydrofolate reductase (MTHFR) mutations.

**SETTING:** Department of Ophthalmology, Hospital de Braga, Braga, Portugal

**METHODS:** Retrospective interventional case series. Review of the medical charts of two young patients admitted with CRVO and whose workup was significant for mild hyperhomocysteinemia related to MTHFR gene mutations.

# RESULTS

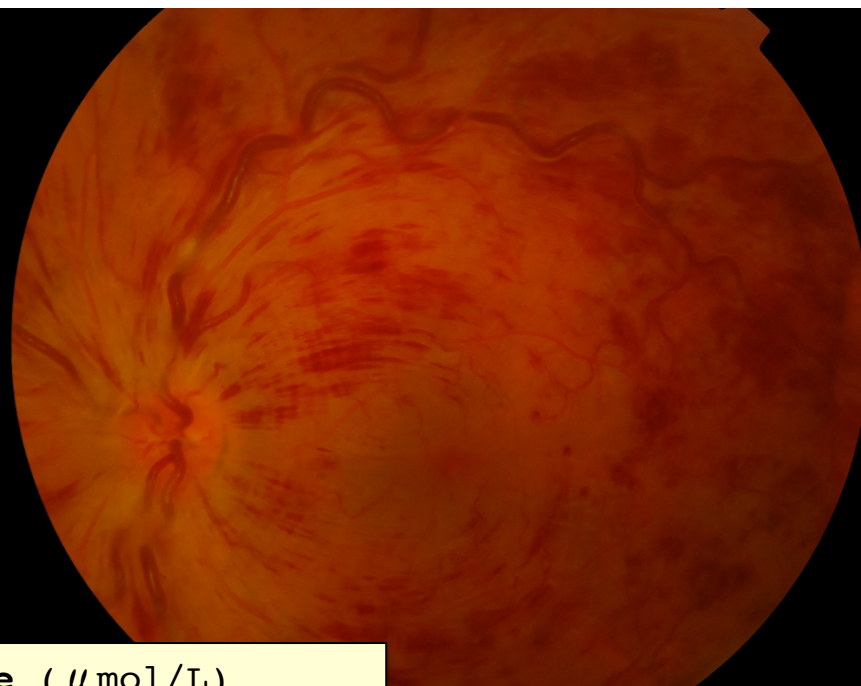
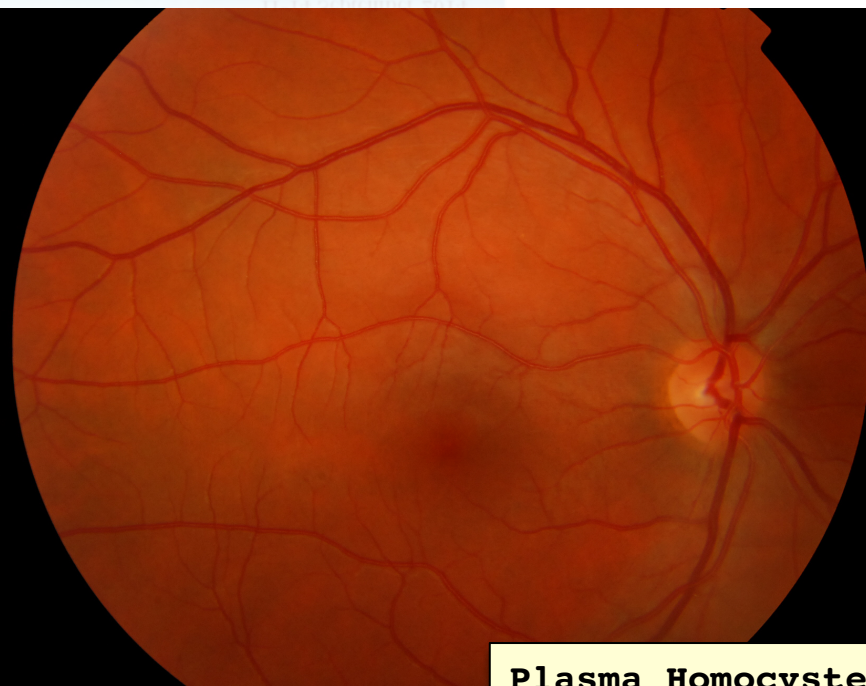**Case I** - 27 year-old, otherwise healthy caucasian male, presented with a sudden decrease visual acuity (VA) OS due to CRVO. He denied any recent strenuous exercise, and a comprehensive ocular and systemic evaluation, including acquired and inheritable prothrombotic risk factors, was unremarkable except for a mild hyperhomocysteinemia associated with homozygous MTHFR A1298C mutation. Macular edema resolved after 3 monthly intravitreal injections of bevacizumab (1.25/0.05 mg/mL). Initial VA of 20/100 improved to 20/25 with treatment. Folic acid and vitamin B complex supplementation was initiated.

---

**Case II** - 44 year-old, caucasian female, with no past medical history, presented with CRVO OD. Apart from the fact that she was on oral contraceptives, her workup was also significant for a mild hyperhomocysteinemia associated with heterozygous MTHFR C677T mutation. VA improved from 20/200 to 20/32, and macular edema resolved after six intravitreal injections of bevacizumab (1.25/0.05 mg/mL).

# RESULTS

## Case I



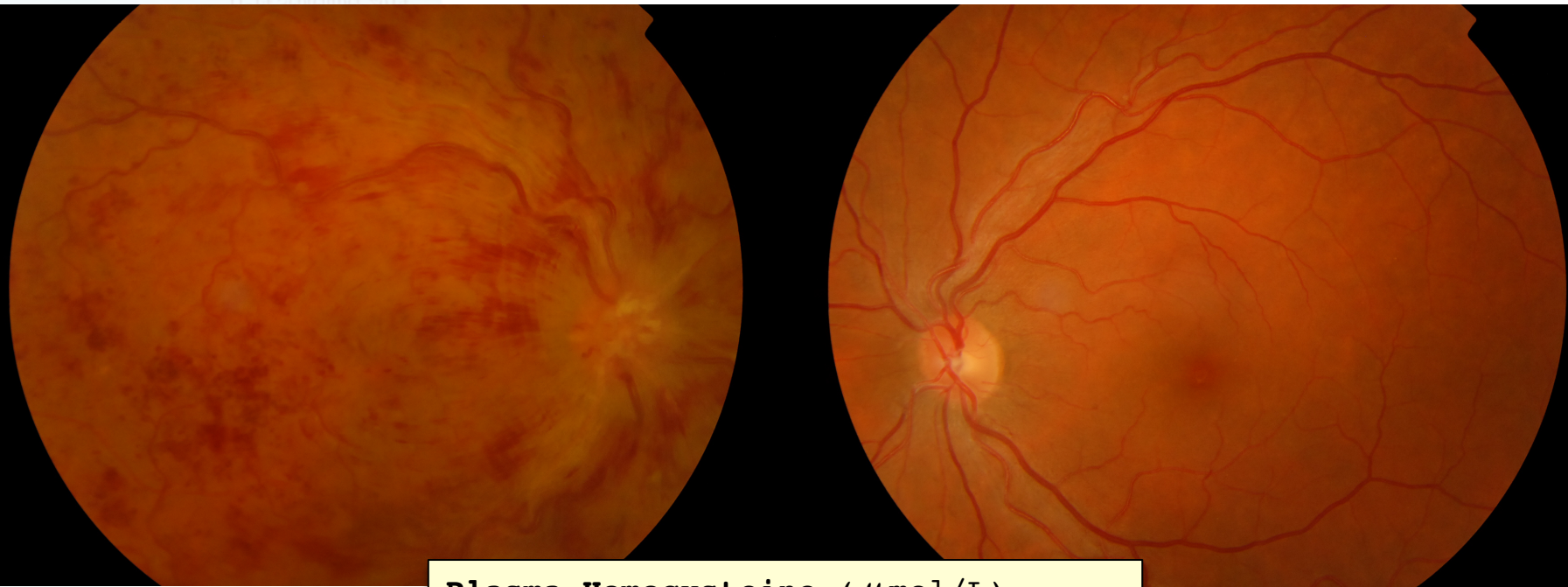
**Plasma Homocysteine** ( $\mu\text{mol/L}$ )  
**30** (ref. range 5-15)

### MTHFR gene Mutations

- C677T (-/-)
- **A1298C** (+/+)

# RESULTS

## Case II



**Plasma Homocysteine** ( $\mu\text{mol/L}$ )  
**23** (ref. range 5-15)

### MTHFR gene Mutations

- **C677T** (+/-)
- A1298C (-/-)

# CONCLUSIONS

*Hyperhomocysteinemia is known to be associated with arterial occlusive vascular disease and venous thrombosis. Genetic mutations in MTHFR are the most commonly known inherited risk factor for elevated homocysteine levels, and should be considered in the etiologic workup of RVO, specially in young patients and/or in the absence of more common ocular and systemic risk factors.*