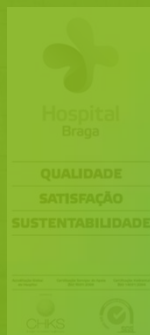




Hospital
Braga



REUNIÃO INTER-SERVIÇOS - CHUC

11 de março de 2015

Margarida Ferreira
Fernando Pardal

- **Identificação:**

- › Homem
- › 31 anos

- **História da doença atual:**

- › Referenciado à consulta de Endocrinologia por “nódulos tireoideus”

- **Antecedentes patológicos:**
 - › Esclerose tuberosa (com crises epiléticas na infância)
 - › Osteotomia direita
- **Antecedentes familiares:**
 - › Mãe e irmão com esclerose tuberosa

- **Ecografia tireoideia (maio 2012)**

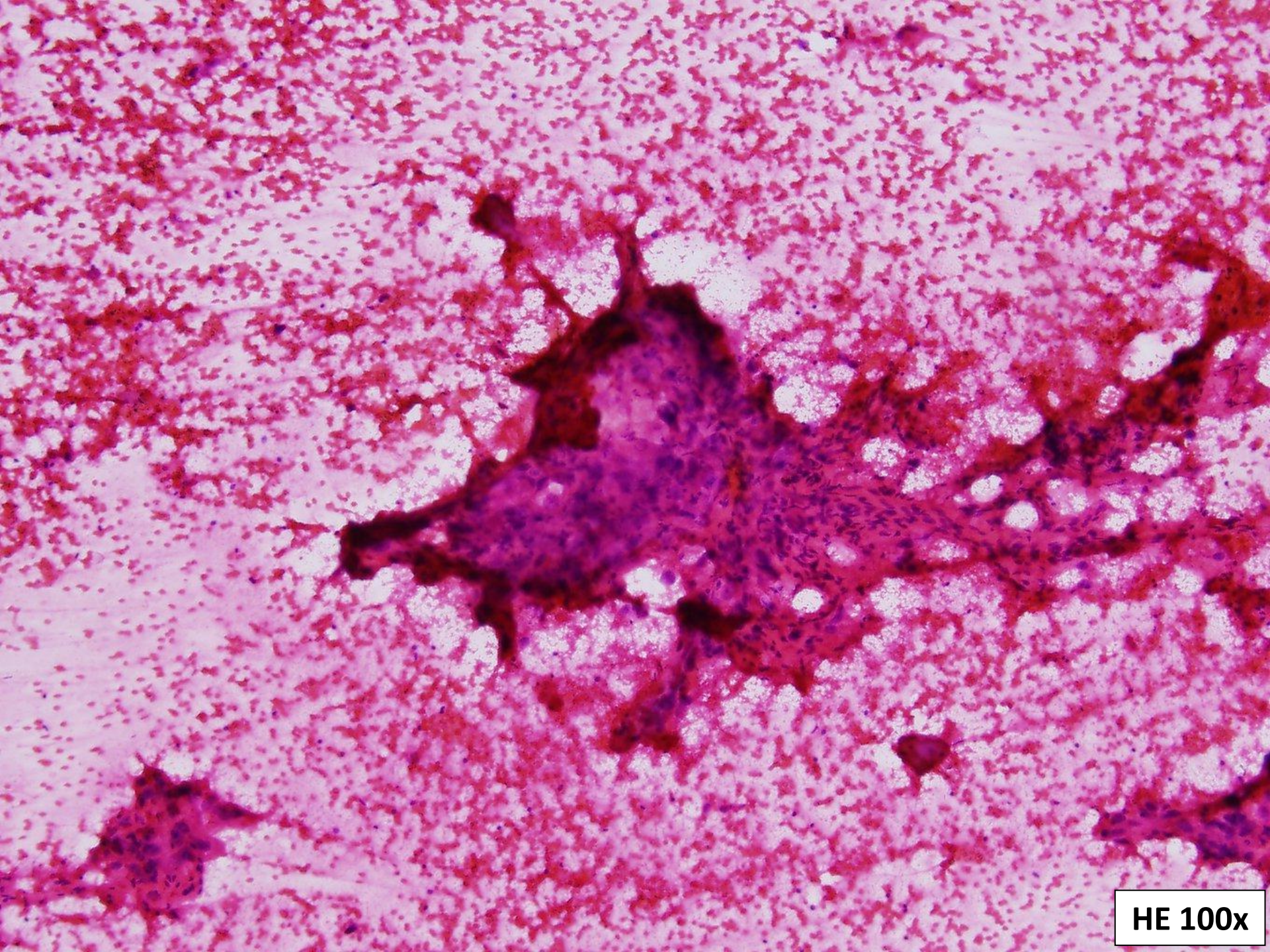
“ (...) nódulo no lobo esquerdo com 7mm (...) outro hipoecoico com 13x6mm.”

- **Ecografia tireoideia (setembro 2013)**

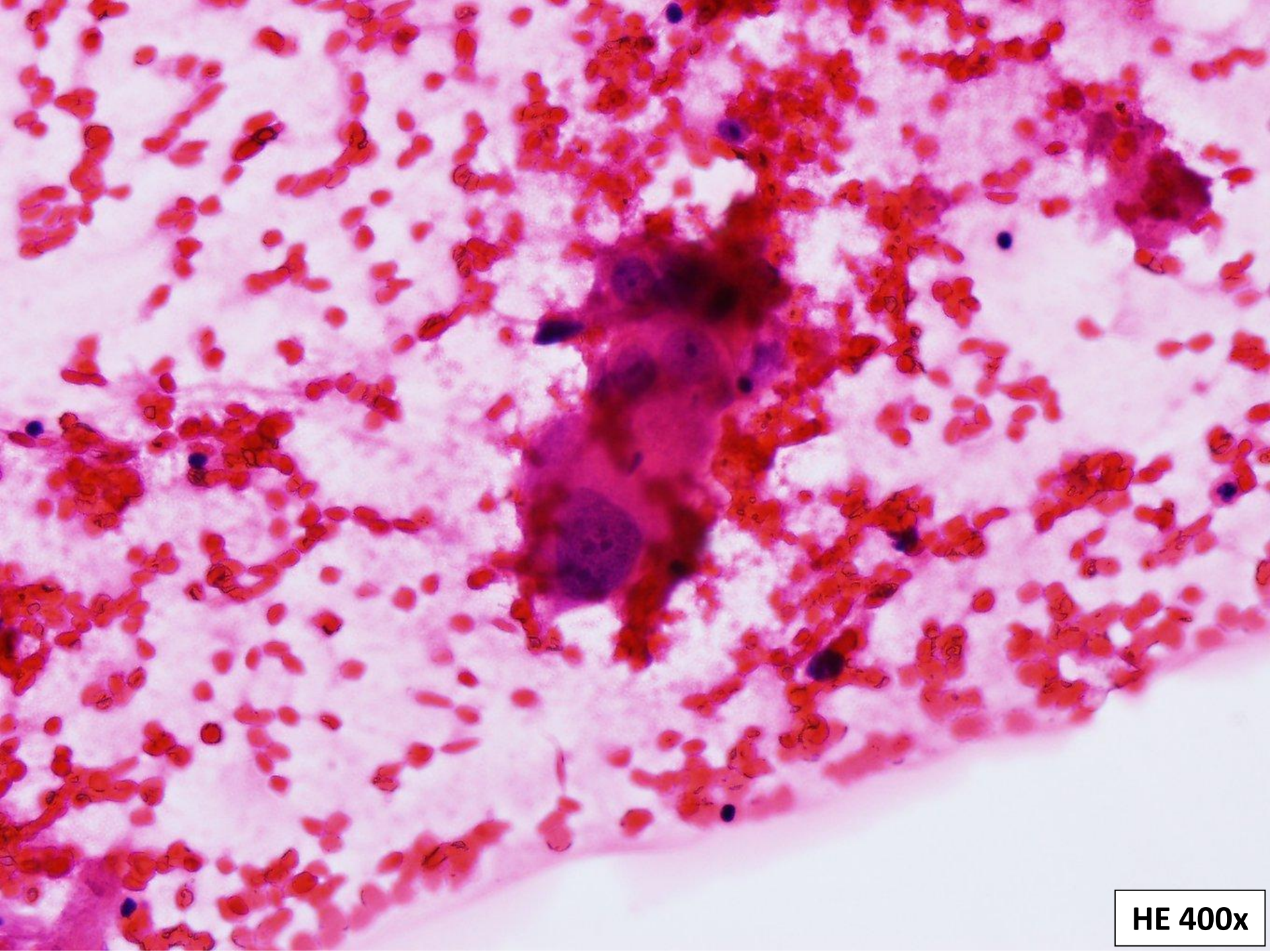
“ (...) textura heterogénea. No lobo esquerdo observam-se dois nódulos sólidos com 12mm e 8mm. Cistos coloides bilaterais que não excedem os 4 mm.(...) ”



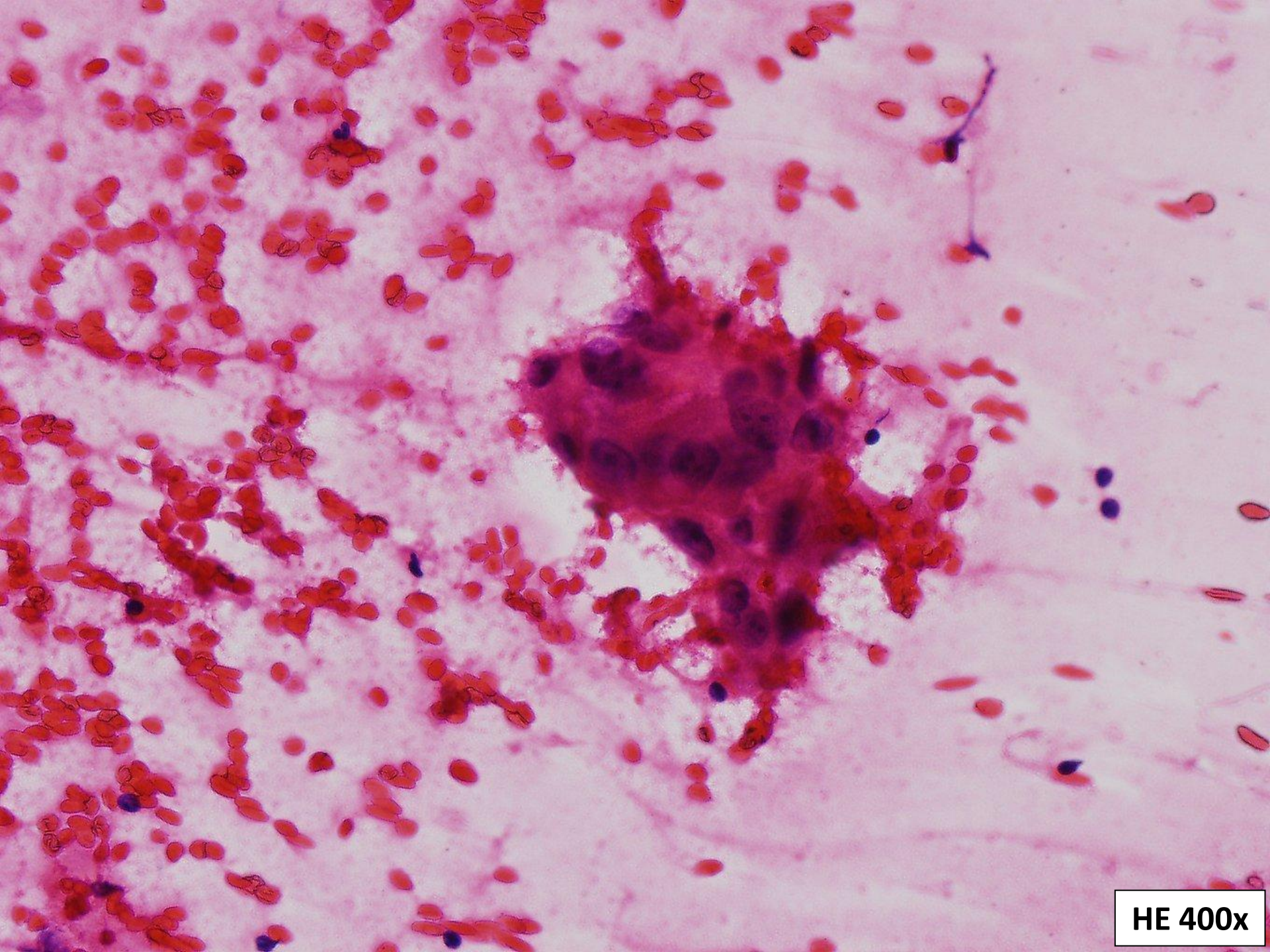
BIÓPSIA ASPIRATIVA



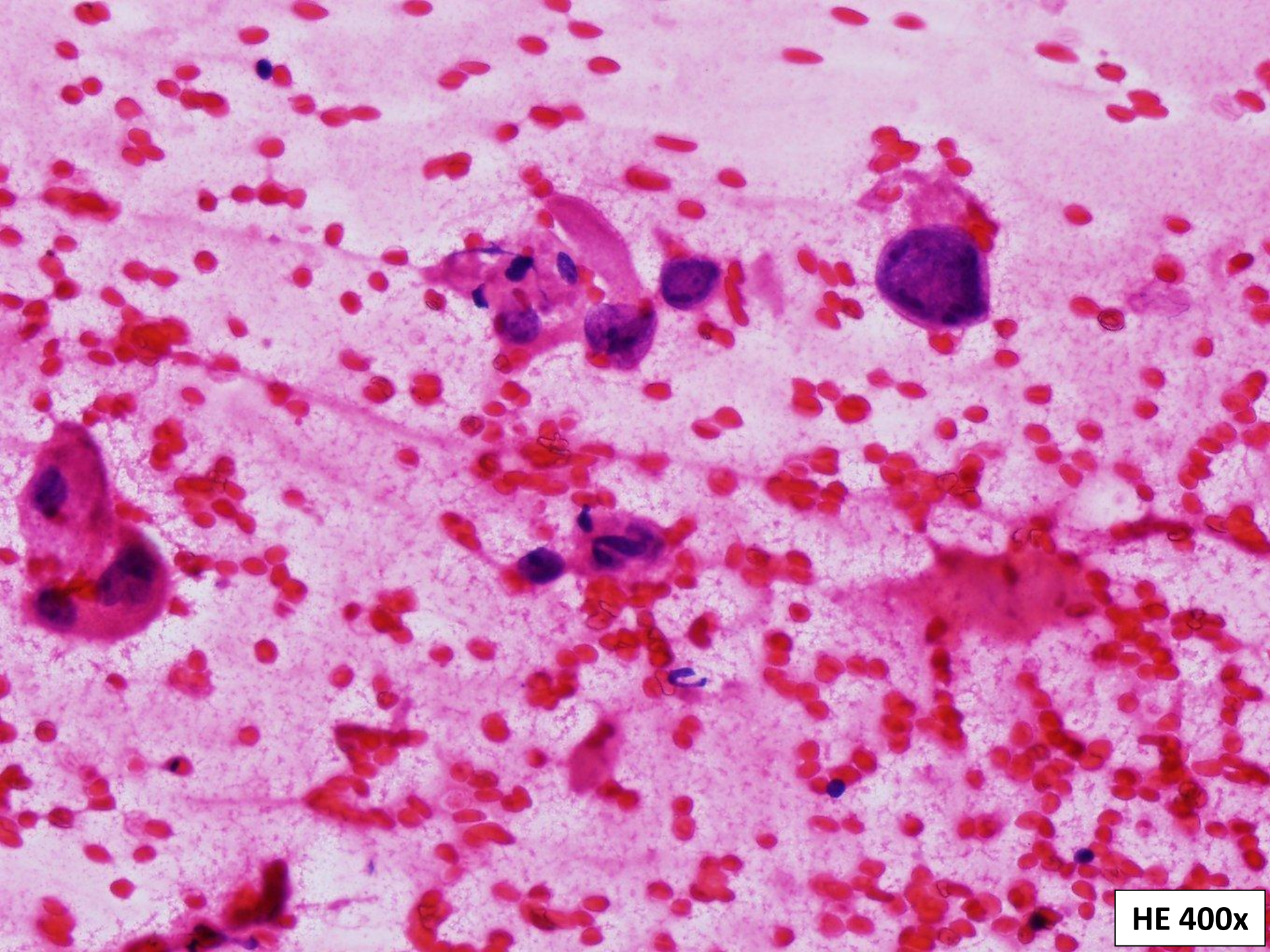
HE 100x



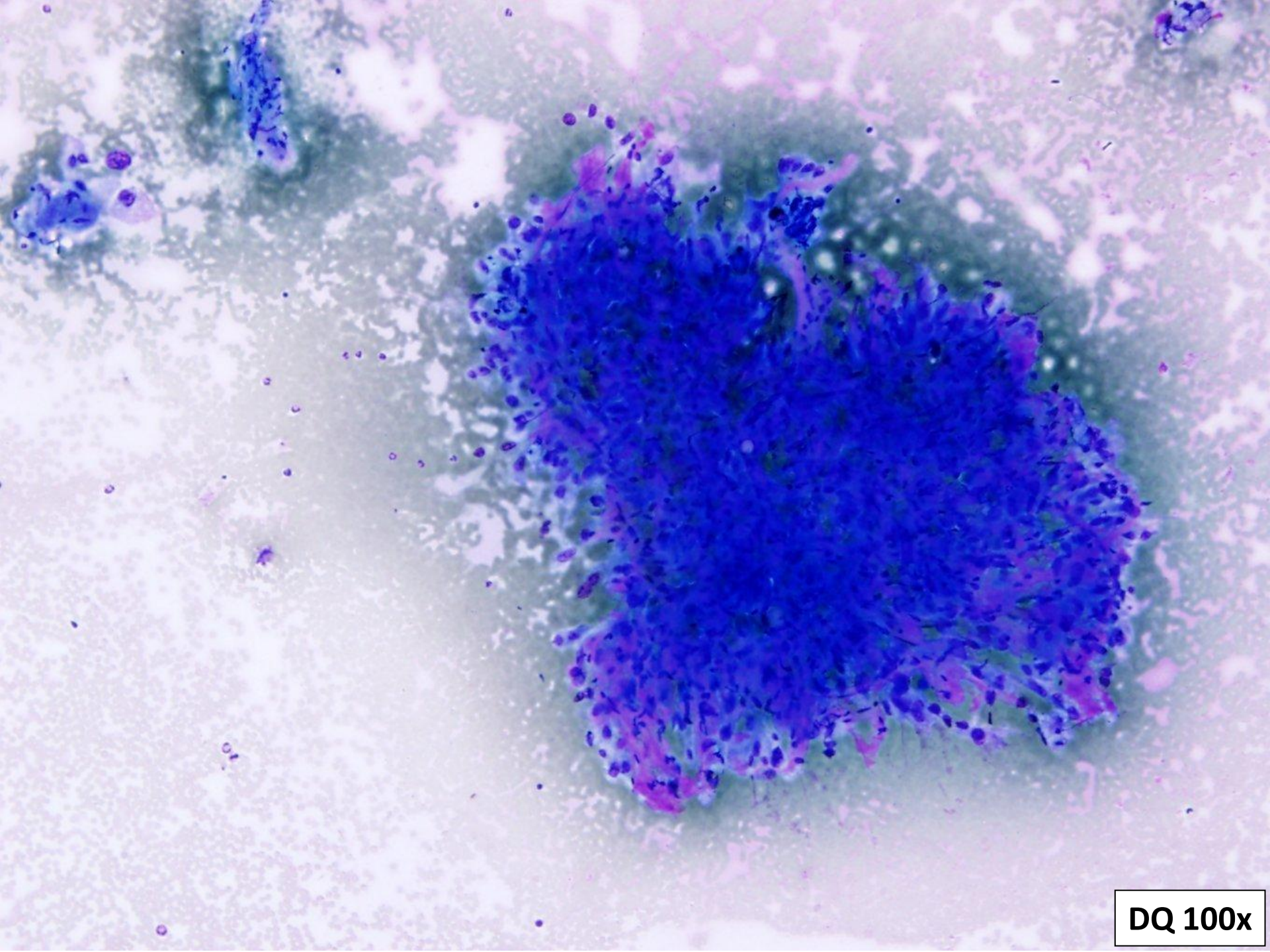
HE 400x



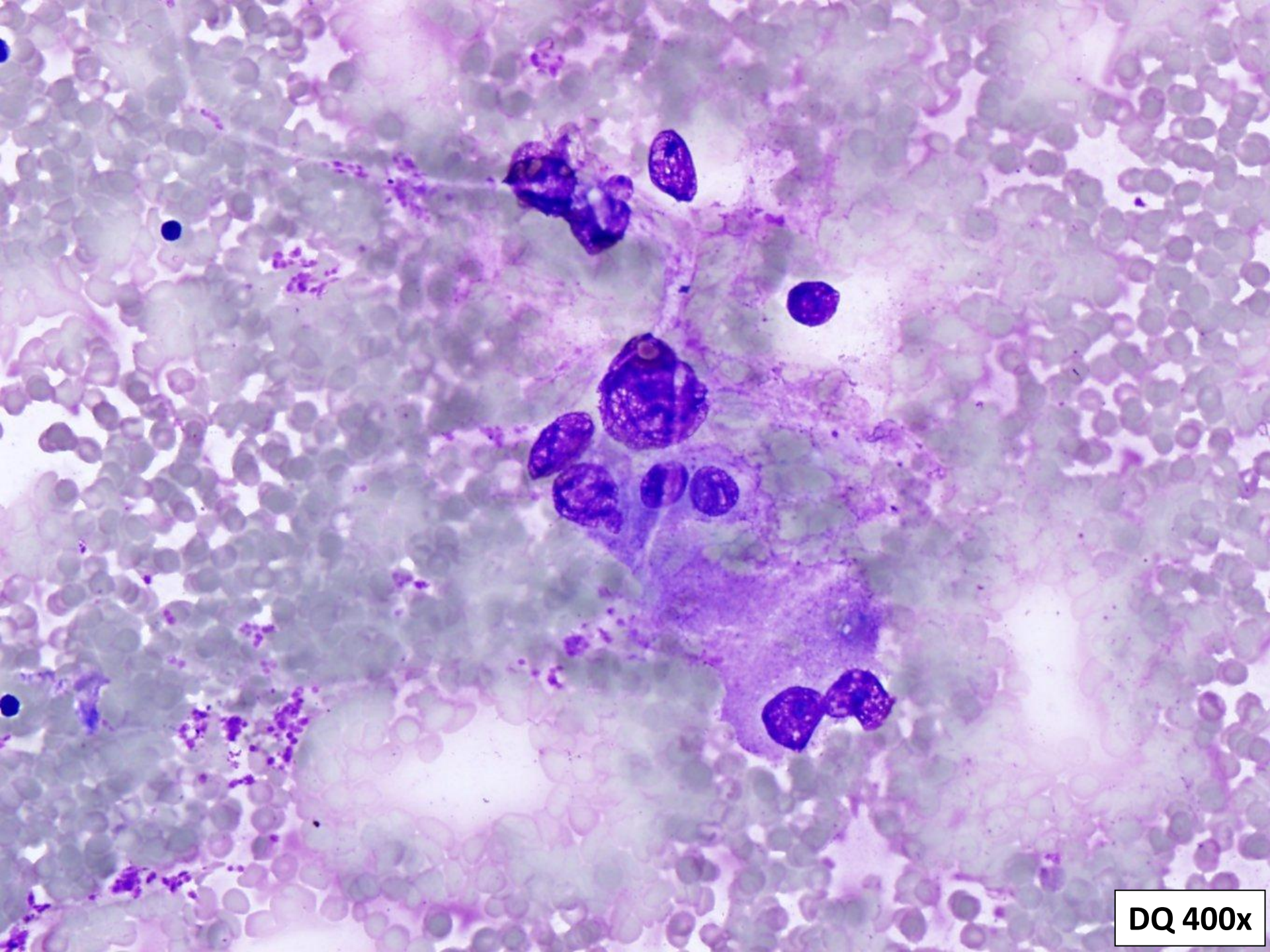
HE 400x



HE 400x



DQ 100x



DQ 400x



- › **SUSPEITO DE MALIGNIDADE, SEGUNDO CLASSIFICAÇÃO DE BETHESDA**

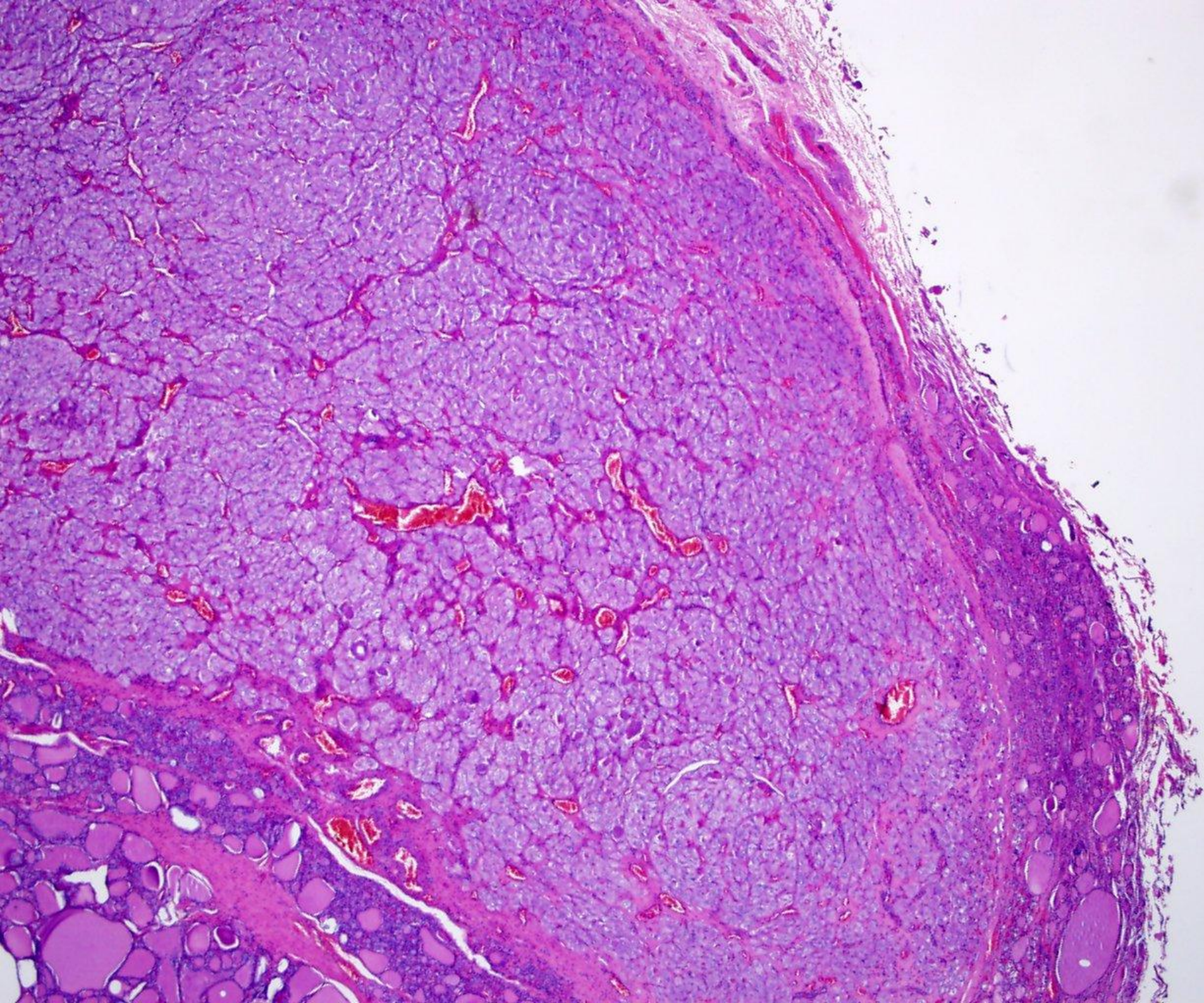
Peça cirúrgica - Macroscopia



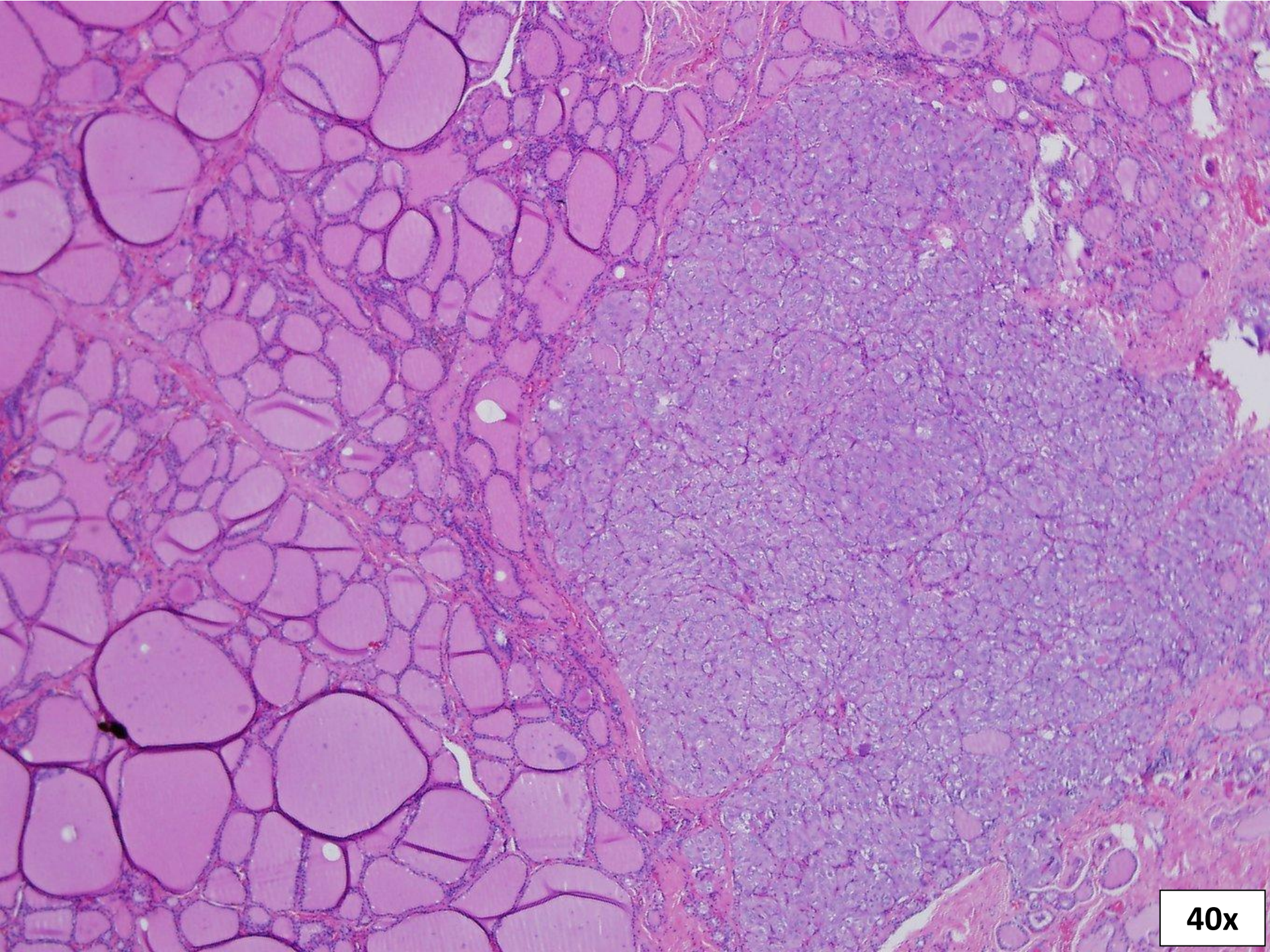
› Glândula tireoide de 24gr e lobos direito e esquerdo de 4,7cm e 6cm, respetivamente.

›Ao corte, identificam-se numerosos nódulos, bem delimitados, esbranquiçados e compactos, o maior com 0,9cm localizado no lobo esquerdo.

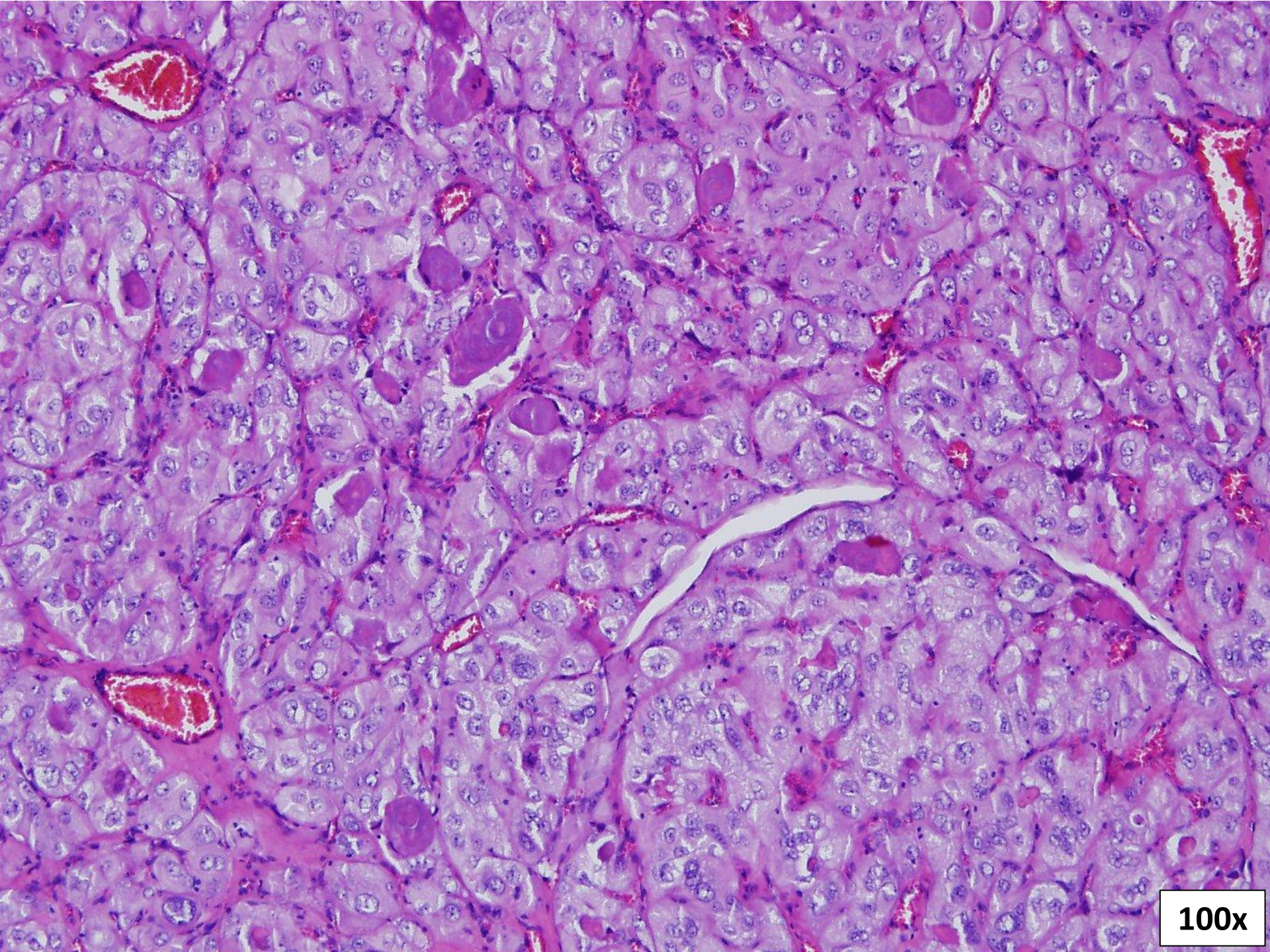
› Isolados seis gânglios linfáticos nos esvaziamentos central e lateral esquerdo seletivo.



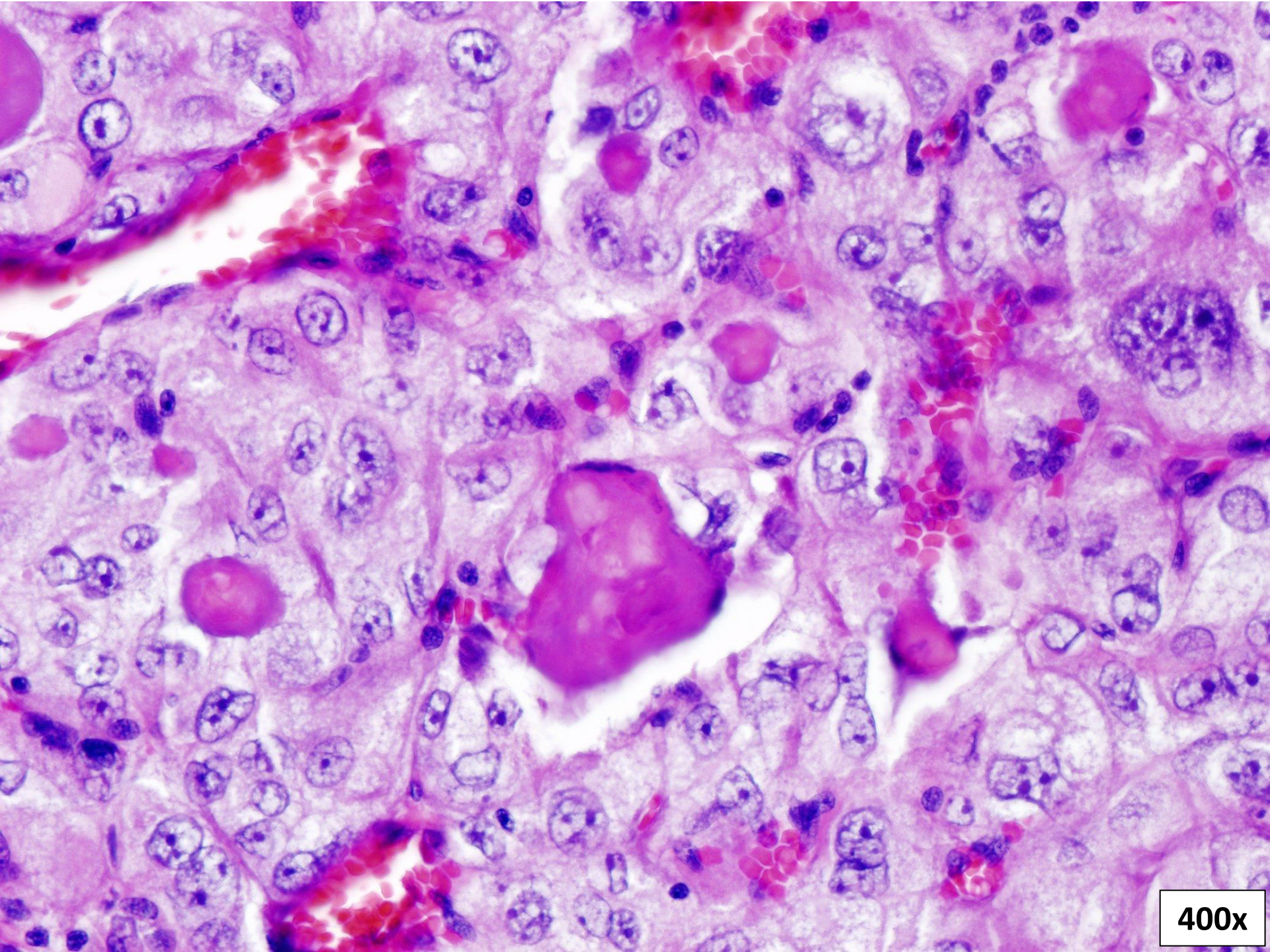
20x



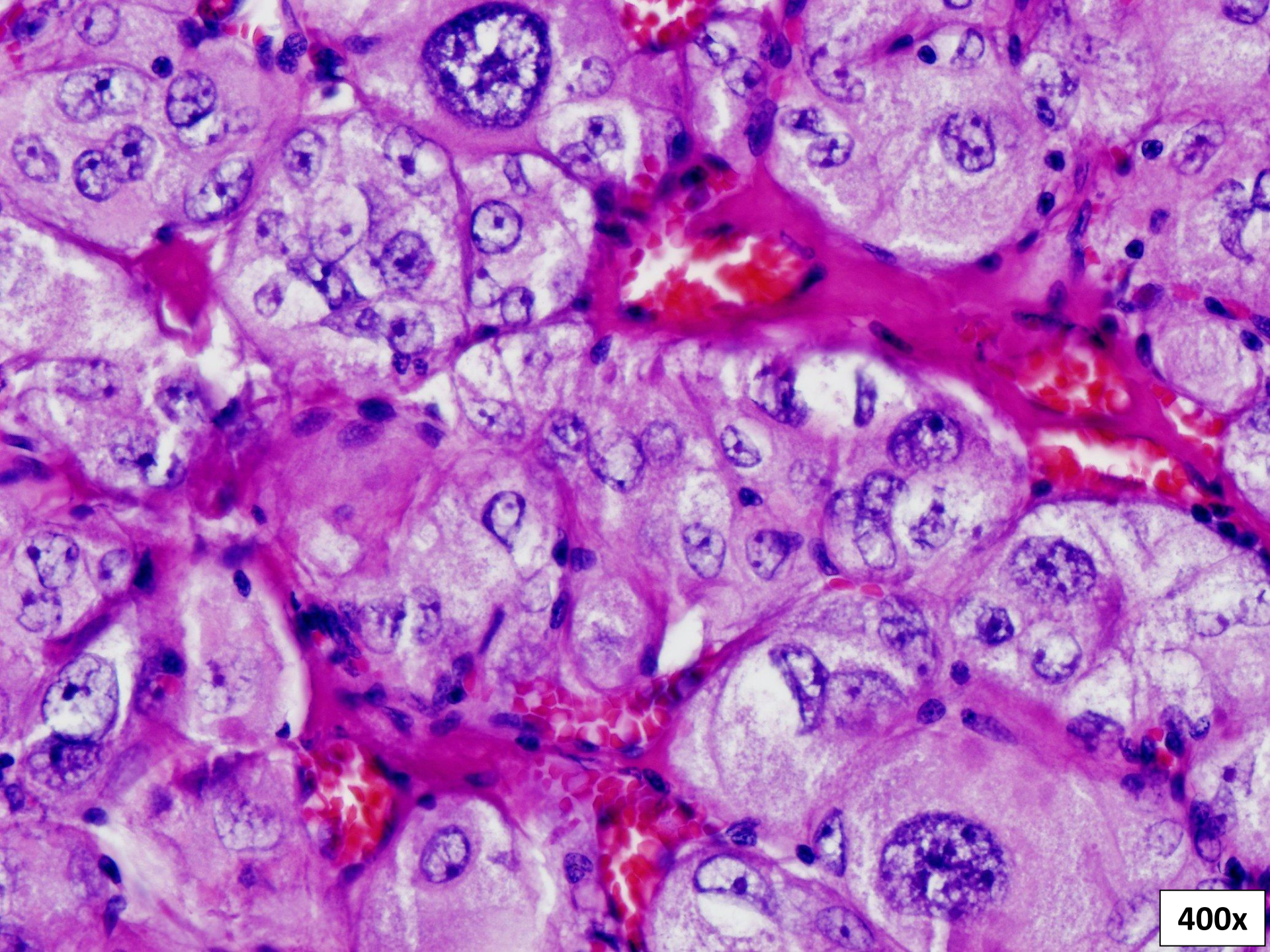
40x



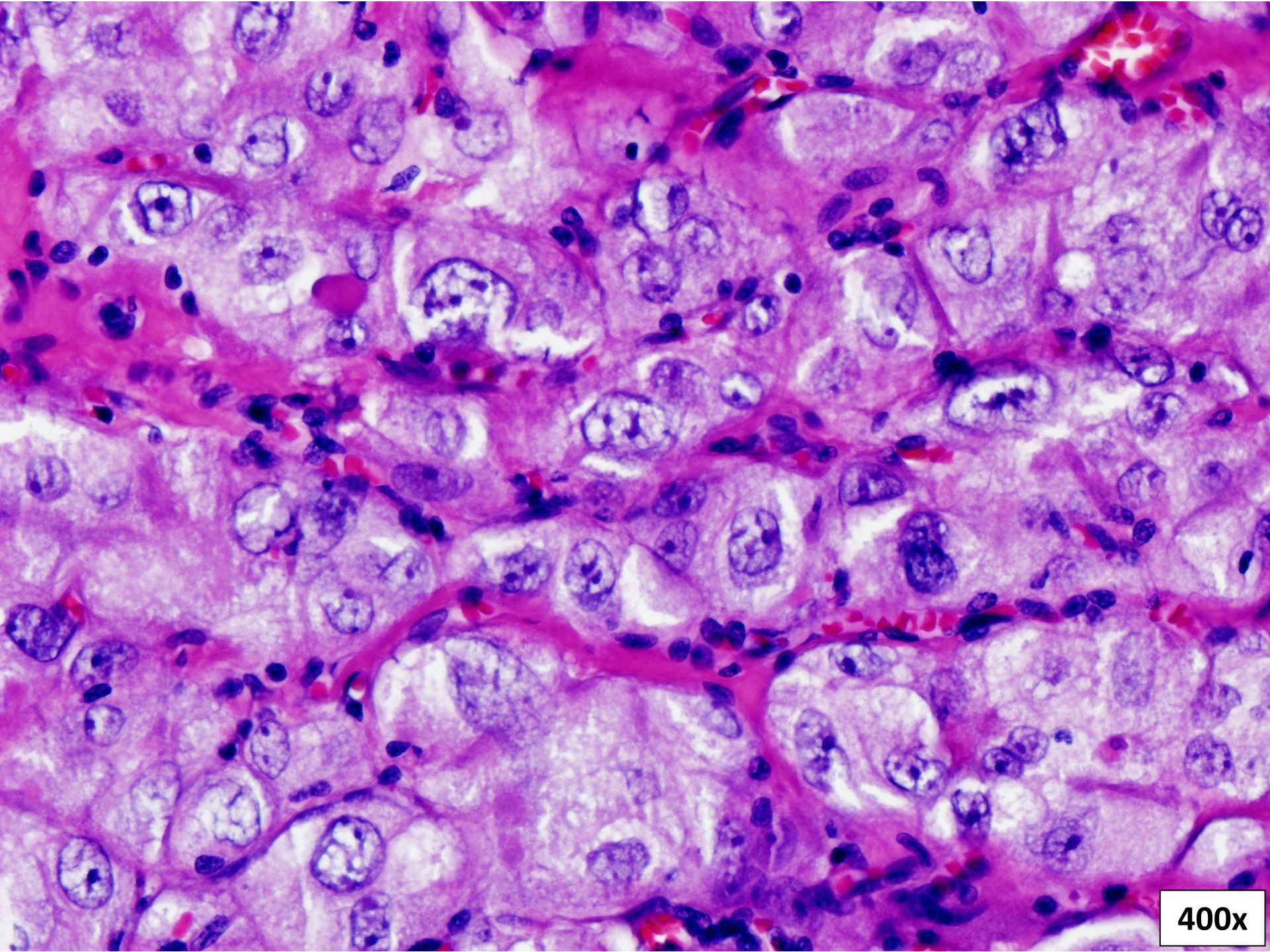
100x



400x



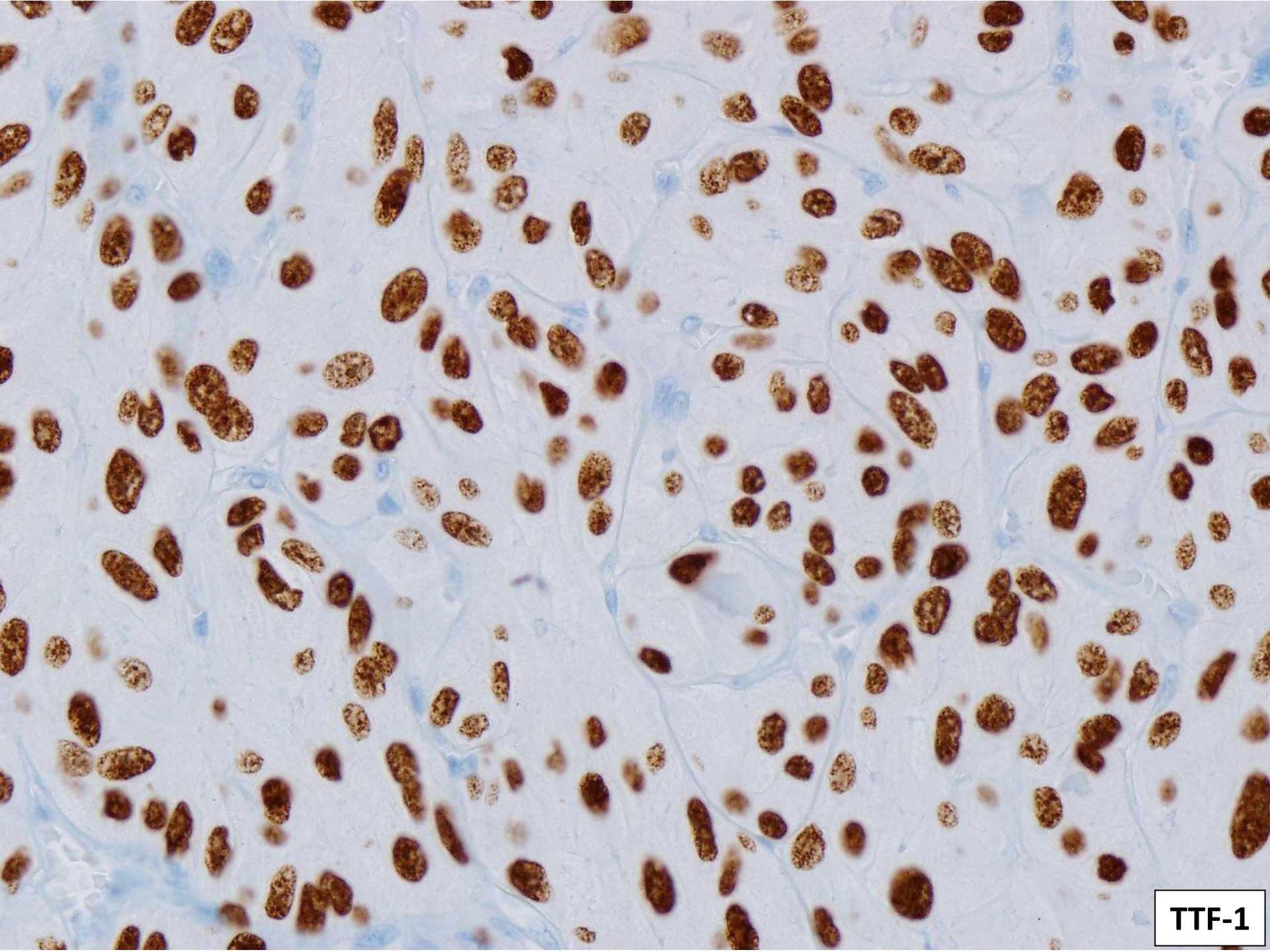
400x



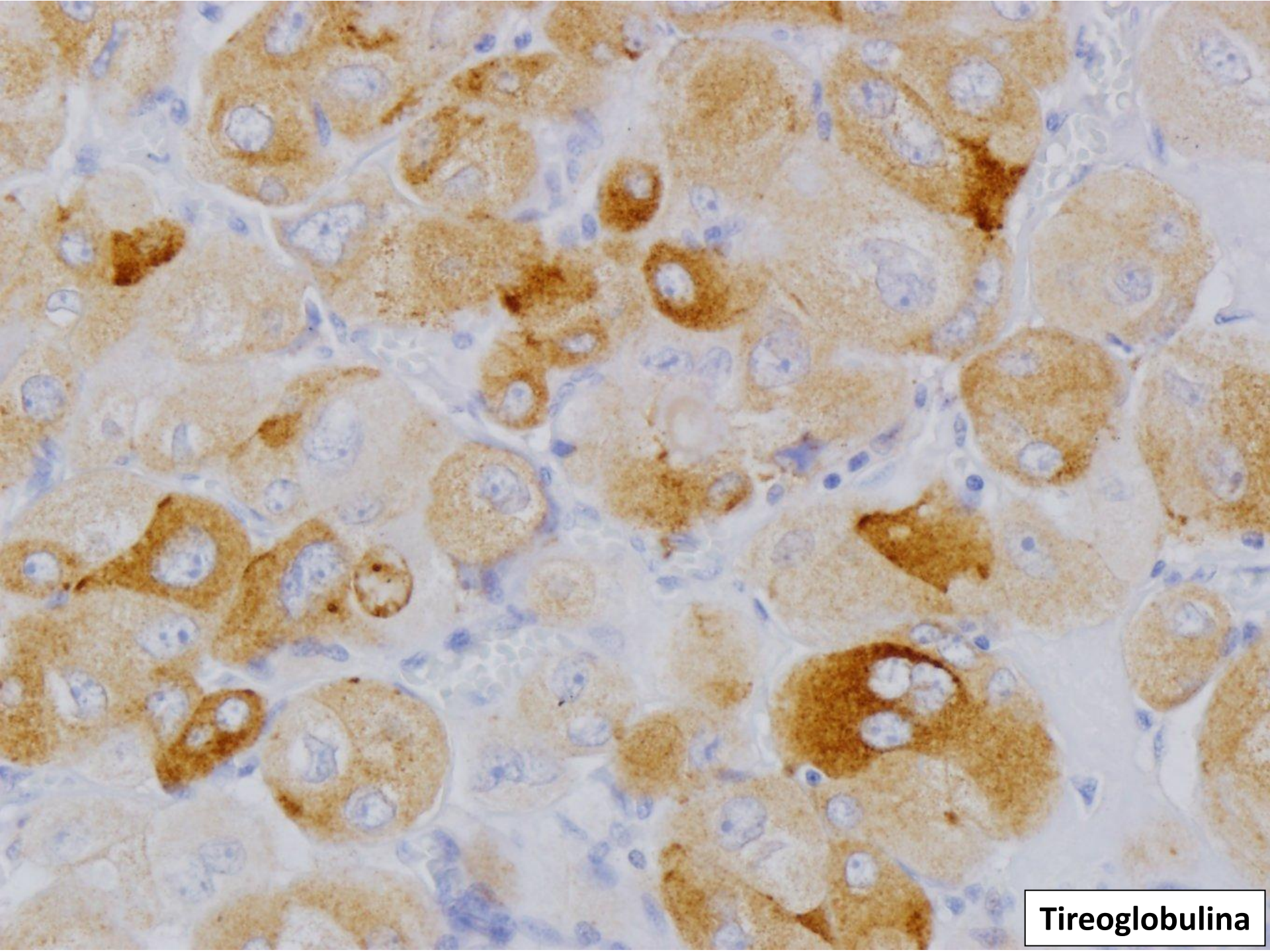
400x

Hipóteses de diagnóstico

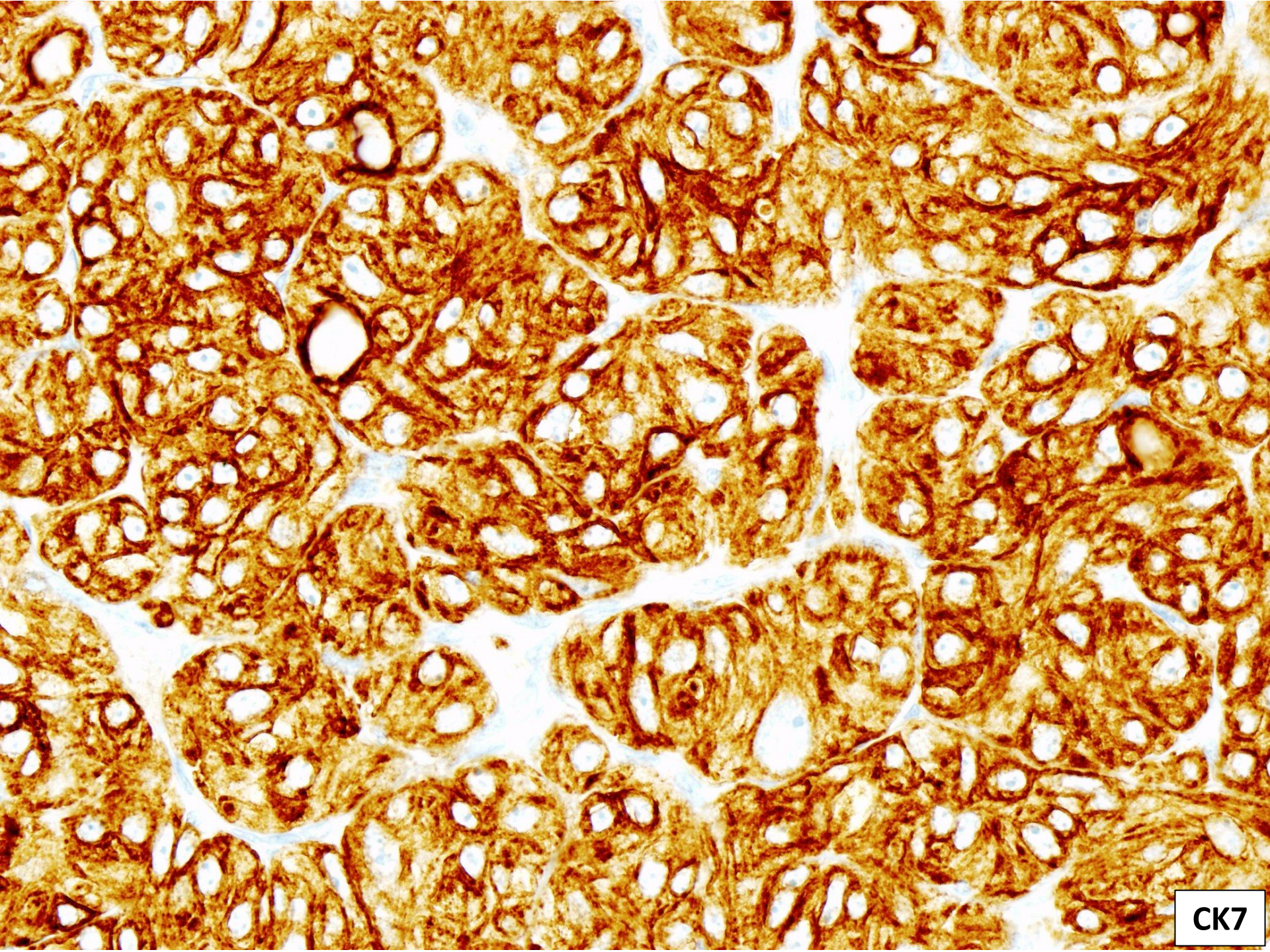
- › Carcinoma medular
- › Carcinoma pouco diferenciado
- › Outros?



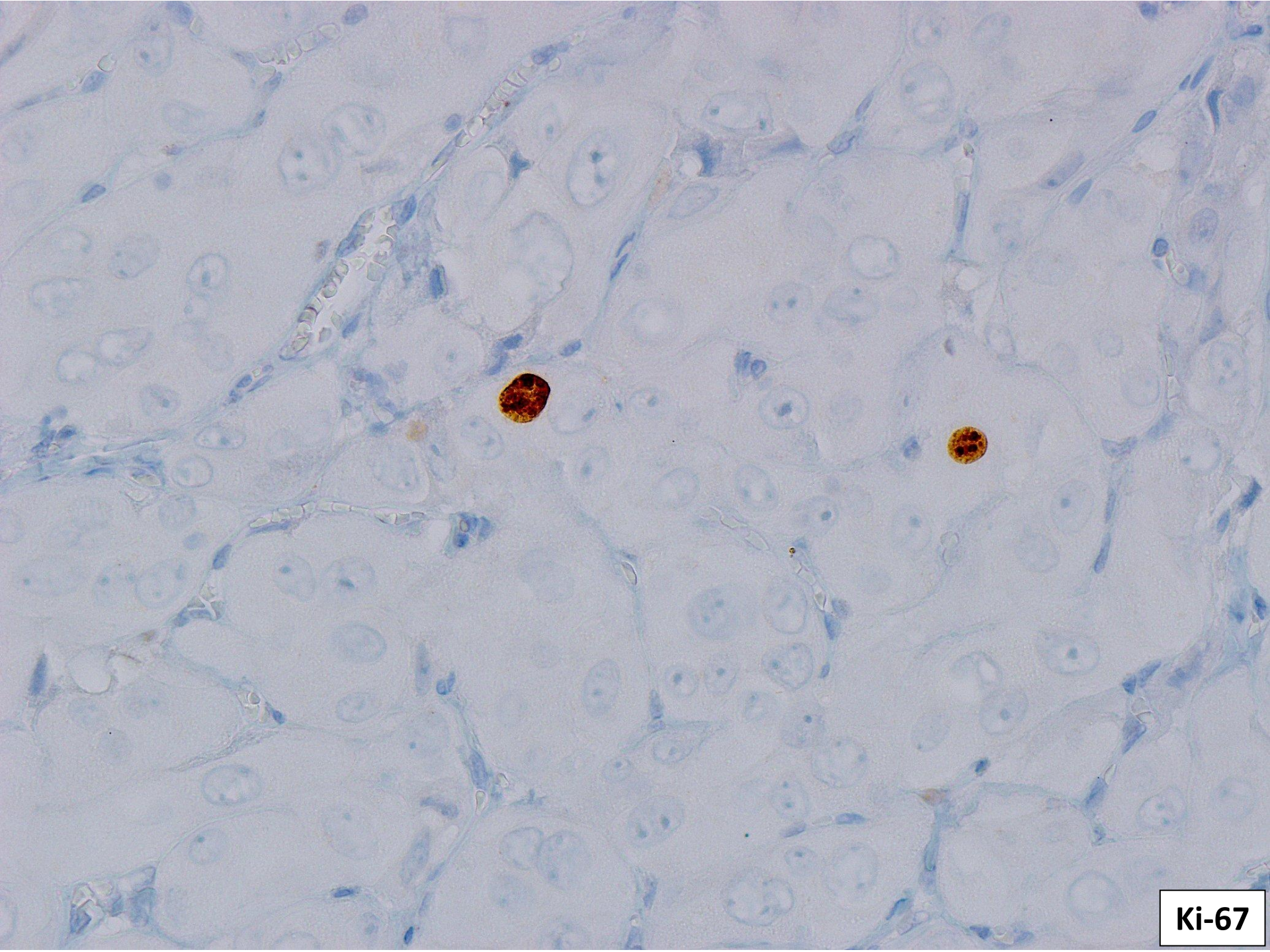
TTF-1



Tireoglobulina

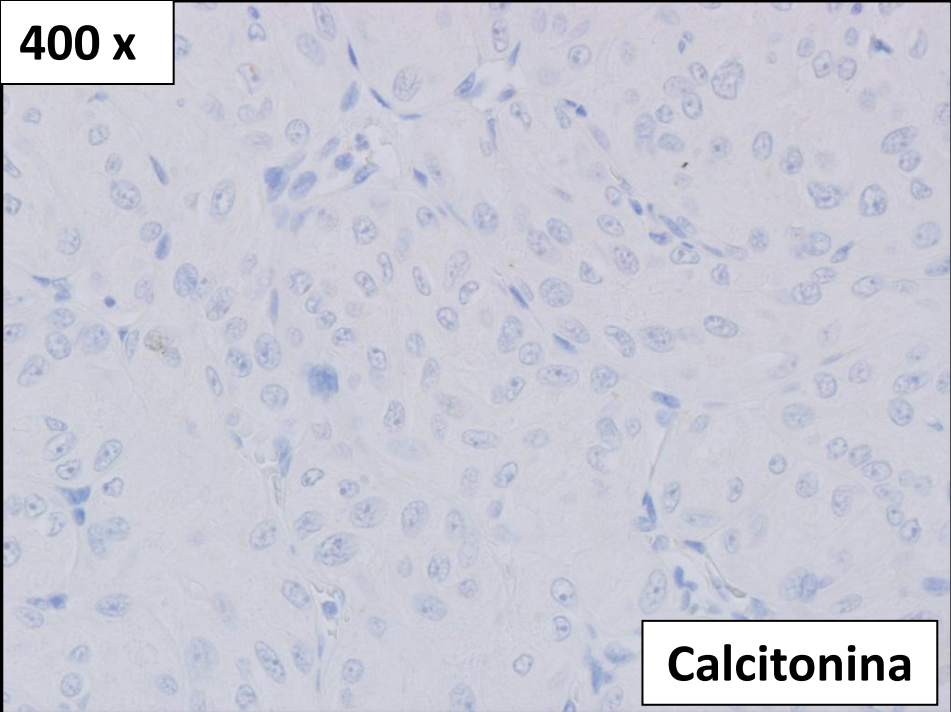


CK7

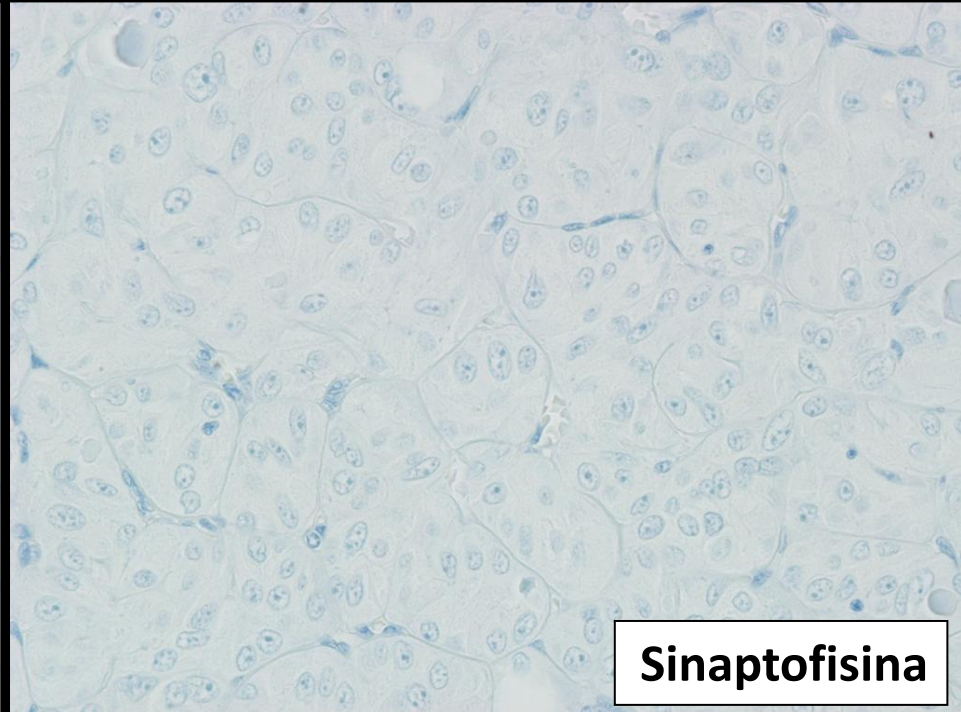


Ki-67

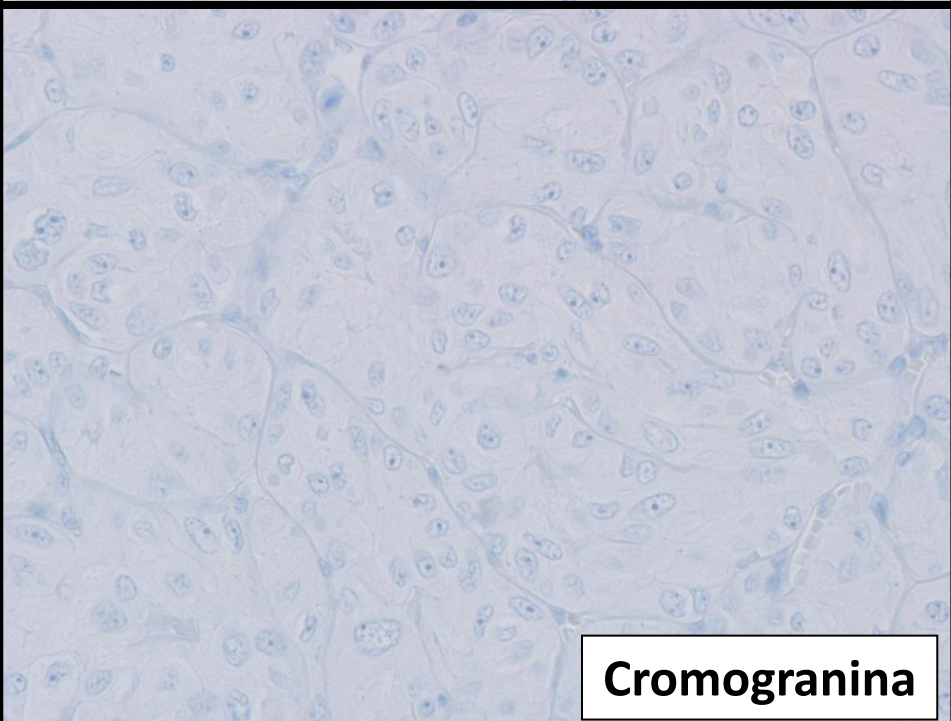
400 x



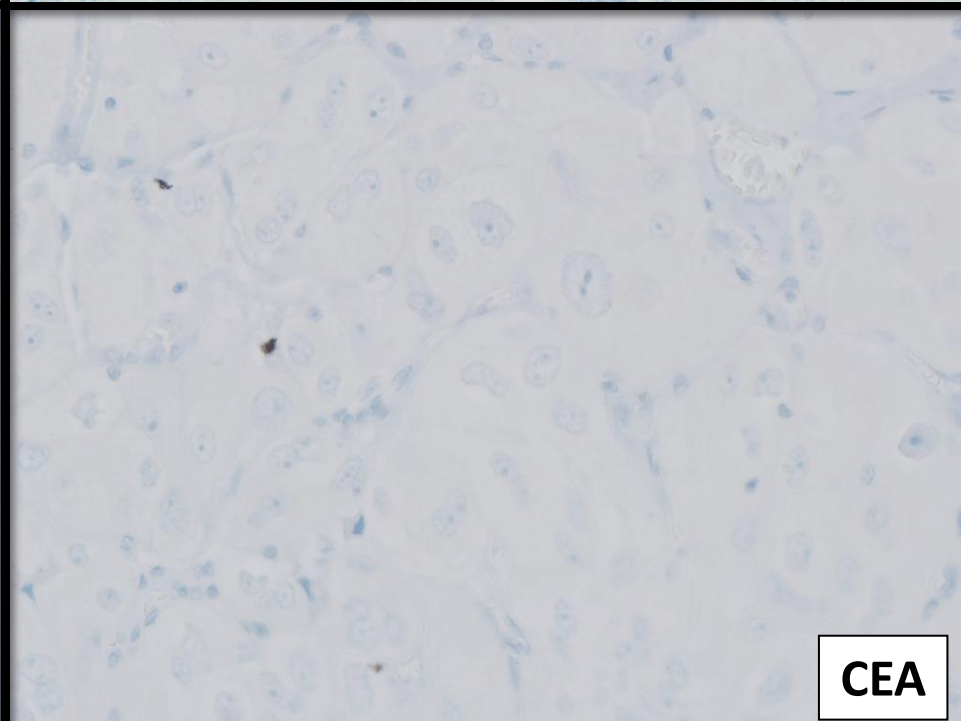
Calcitonina



Sinaptofisina

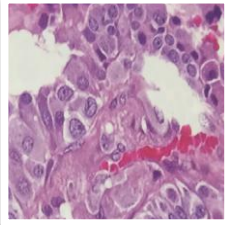


Cromogranina



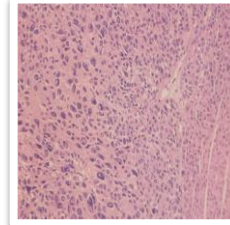
CEA

Hipóteses de diagnóstico



Carcinoma medular

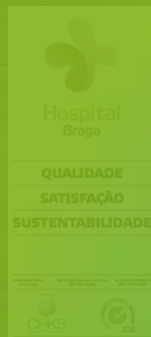
- **Positivo:**
 - Calcitonina
 - Sinaptofisina
 - Cromogranina
 - TTF-1
 - CEA
- **Negativo:**
 - Tireoglobulina



Carcinoma pouco diferenciado

- **Positivo:**
 - Tireoglobulina
 - TTF-1
 - Índice proliferativo (Ki-67)
:10-30%

› CARCINOMA DIFERENCIADO MULTIFOCAL DA GLÂNDULA TIREOIDE



**Hospital
Braga**

Hospital de Braga
Sete Fontes - São Victor
4710-243 Braga

www.hospitaldebraga.pt