

The first case of anesthesia for an awake craniotomy in the Hospital Braga



Celina Oliveira, Celina Gomes, Isabel Cerqueira, Maria José Pereira
Anesthesiology Department - Hospital Braga, Portugal

BACKGROUND AND AIMS

Craniotomies performed in awake patients are becoming increasingly frequent. Using intraoperative mapping to identify the lesion and, as a result, perform an accurate resection of the tumor, minimizing the risk of neurologic damage, has the greatest advantage of using this practice¹. The major anesthetic challenge is to provide an adequate sedation and analgesia, with hemodynamic and respiratory control during dormant and awake stages of the surgery².

We report the first case of anesthesia for an awake craniotomy in the Hospital Braga.

DESCRIPTION OF THE CASE

Man, 56 years old, was submitted to removal of fronto-insular tumor in the left side.

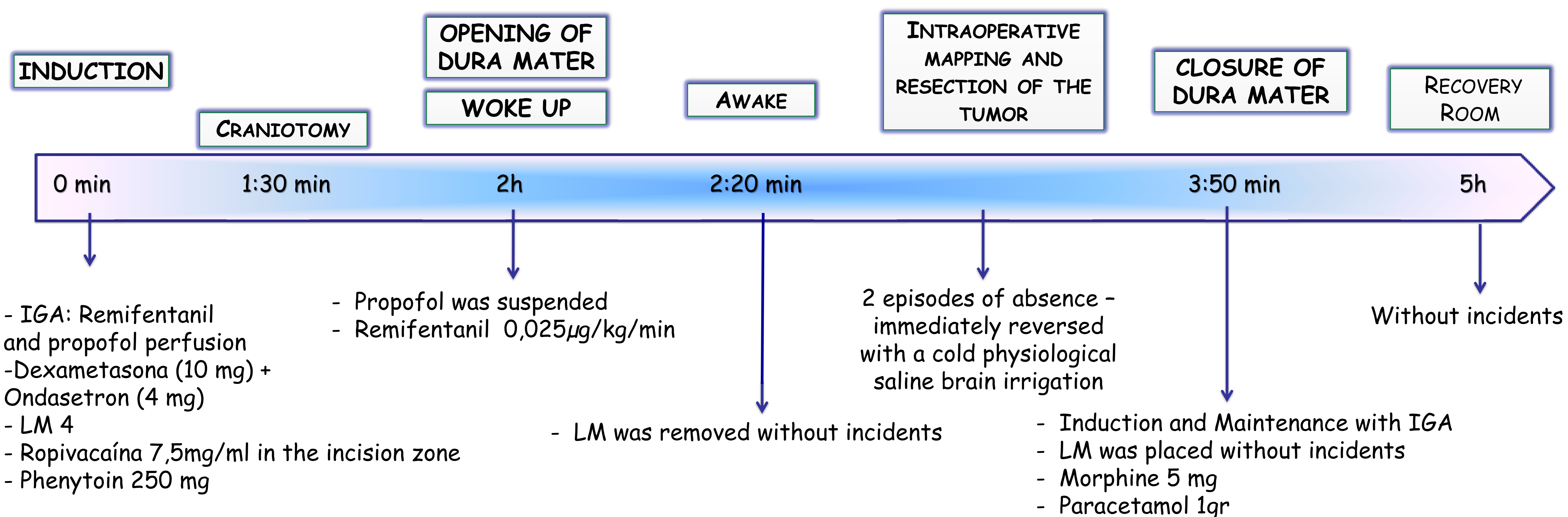
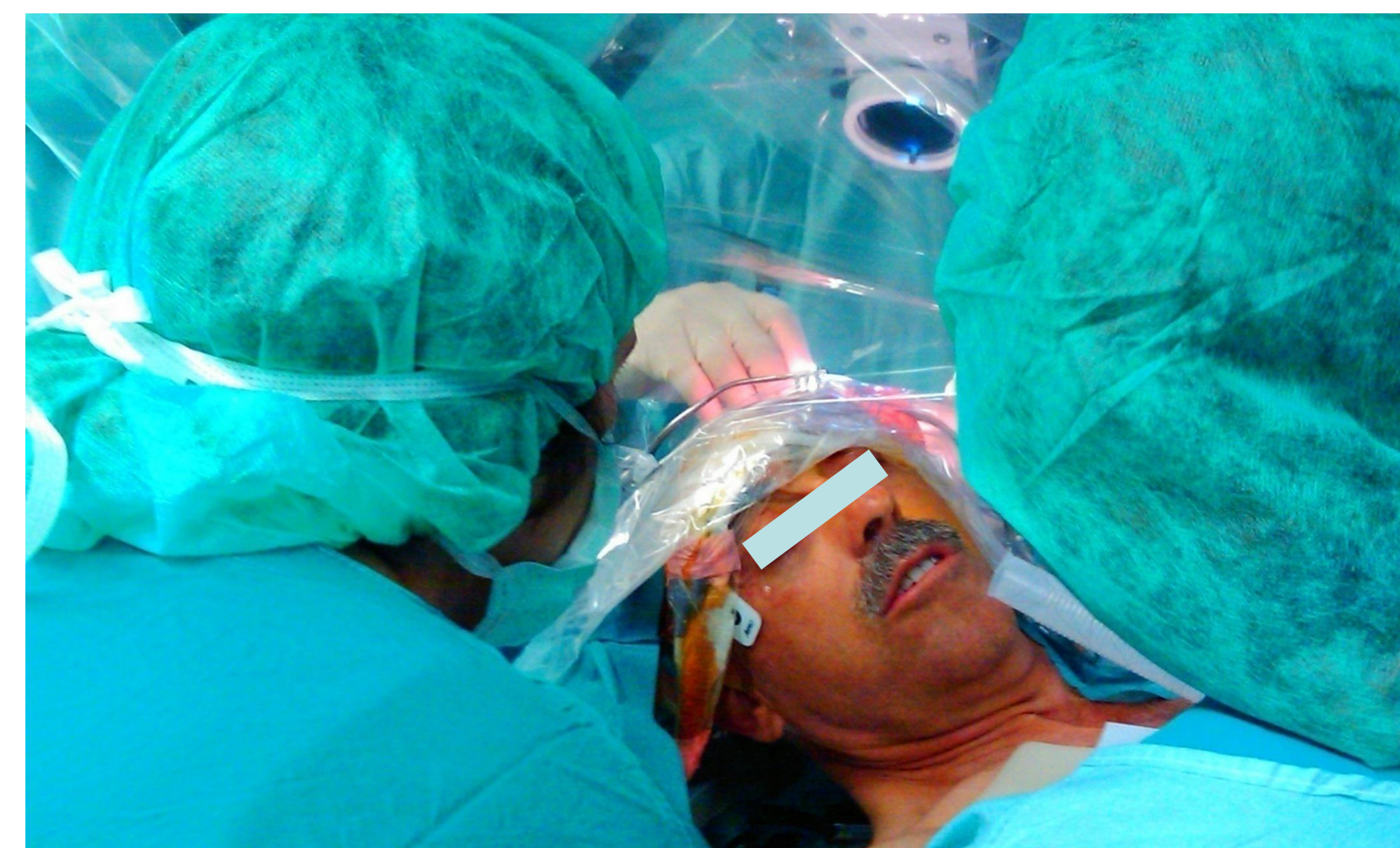ASA II

Asleep-awake-asleep technique: Intravenous General Anaesthesia (IGA) +

Ropivacaine (7,5mg/ml) infiltration was made in the incision zone

Monitorization: ASA standards + invasive arterial blood pressure + BIS®

Airway: Laryngeal Flexible Wire Mask (LM)



DISCUSSION AND CONCLUSIONS

The technique performed was efficient for the attainment of an awake and cooperative patient during the Aphasia test of Aachen. The LM was essential for the permeability of the airway. Part of the success of this procedure is, undoubtedly, the establishment of a stable relationship between the patient and the anesthetic and surgical teams. Furthermore, the success of the surgery is achieved by the prompt cooperation shown by the patient.