

Gliomas de baixo grau em áreas (mais) eloquentes

Nuno Morais
José António Moreira da Costa

Introdução

- Grupo heterogéneo tumores
 - astrocítica
 - oligodendroglial
 - ependimária
 - mista
- 15% tumores cerebrais adultos
- Distribuição bimodal (6-12 a; 20-40 a); >60 a
- , brancos

Introdução

- Astrocitomas (+++); ↑ oligodendrogliomas puros e oligoastrocitomas
- Astrocitomas: áreas funcionais secundárias (ínsula, área motora acessória)
- Oligodendrogliomas (convexidade subcortical, lobo frontal)
- GBG frontal < temporal < parietal

Factores prognóstico

- Pequeno tamanho
- Ausência défices
- KPS > 70%
- Jovens

Criterion	Points (yes/no), n/n
2008 LGG scoring system (UCSF) [7] ^a	
Age >50 y	1/0
KPS ≤80	1/0
Eloquent location (presumed)	1/0
Maximum diameter >4 cm	1/0
2002 LGG scoring system (Pignatti et al.) [4] ^b	
Age ≥40 y	1/0
Astrocytoma histology	1/0
Maximum diameter ≥6 cm	1/0
Tumor crossing midline	1/0
Neurologic deficit	1/0

KPS Karnofsky performance score, *LGG* low-grade glioma, *UCSF* University of California, San Francisco

^a Risk stratification: low = 0–1 points, medium = 2 points, high = 3–4 points

^b Risk stratification: low = 0–2 points, high = 3–5 points

Prognóstico

- Classificação UCSF
 - predição OS e PFS
 - baixo risco: OS 5a= 97%; PFS 5a= 76%
 - médio risco: OS 5a= 81%; PFS 5a= 49%
 - alto risco: OS 5a= 56%; PFS 5a= 18%
- OS média adultos
 - astrocitoma (II): 4.7 a
 - oligoastrocitoma (II): 7.1 a
 - oligodendroglioma (II): 9.8 a

Imagiologia

- Implicação prognóstica captação contraste controversa
- Estudos funcionais
 - activação centros corticais
 - fRMN
 - PET
 - magnetoencefalografia
 - DTI/tractografia
 - pouco fiáveis
- Correlação fRMN e mapeamento intraop
 - 50-66% linguagem
 - 71- 95% motor

Patogénese molecular

- Oligodendroglioma – melhor px e resposta tx
- Delecção 1p/19q
 - melhor px (< OMS III)
 - ↑ OS e PFS
 - PCV e temozolamida

Table 2 Molecular findings in low-grade glioma

IDH isocitrate dehydrogenase

^aPlease see the review by Schiff et al. [9] for a more comprehensive analysis of molecular findings and their prognostic significance

Finding	Astrocytoma, %	Oligoastrocytoma, %	Oligodendroglioma, %
1p/19q Codeletion ^a	7	45	69
p53 Mutation ^a	53	44	13
IDH mutation [17–19, 20•, 21]	59–90	50–83	68–85
MGMT hypermethylation ^a	30–50	Data lacking	85

Tratamento cirúrgico

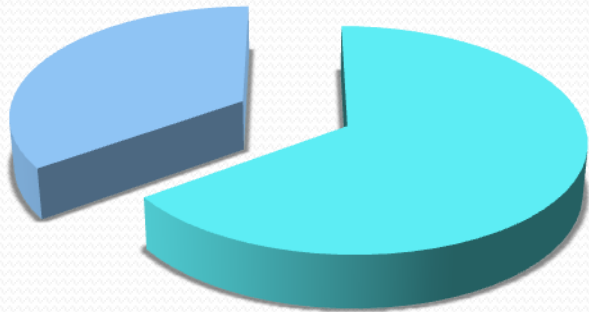
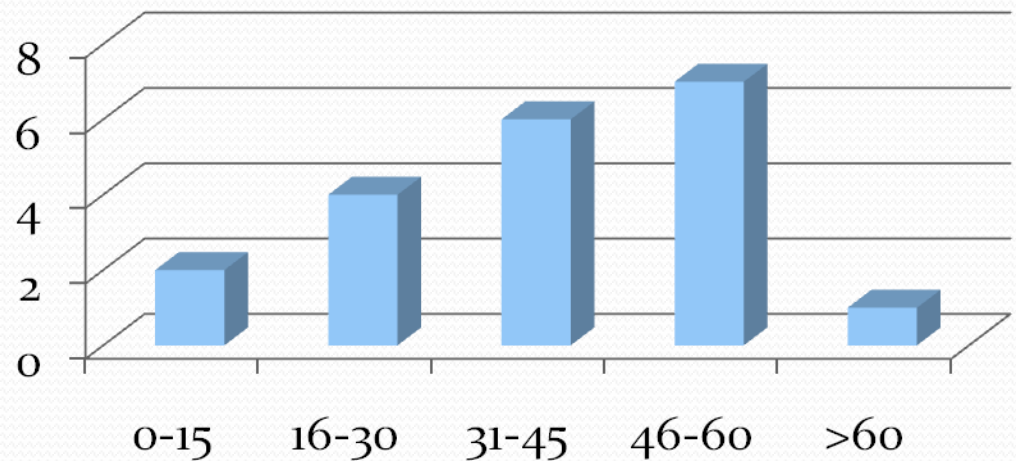
- BSTX >50%
- Extensão ressecção (ER) ↑ OS (Berger et al), mas não PFS
 - ER >90%: OS 5a= 97%
 - ER <90%: OS 5a= 76%
- Melhoria défices pós-op 3 meses
- Tecnologia intraop (neuronavegação) e técnicas pré e intra-op (fRMN, mapeamento)
 - <2% défice permanente (Duffau et al)
 - gliomas insulares: 6% défice pós-op

Tratamentos complementares

- RT
 - única com comprovado benefício (estudos randomizados)
 - EORTC: RT precoce ↑ PFS, mas não OS
 - RT na progressão
 - decisão caso a caso
- QT
 - temozolamida perfil favorável QOL
 - estudos em curso (QT vs RT, QT+RT, etc)
 - papel QT neoadjuvante (Duffau)

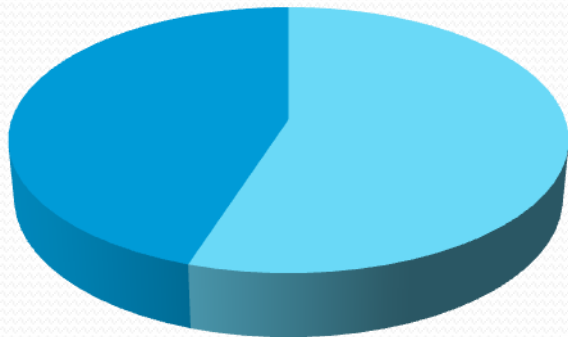
Resultados

- Janeiro 2005 – Dezembro 2010 (n=20)
- 7-64 anos (38,2)



■ Mulheres (13)
■ Homens (7)

Resultados

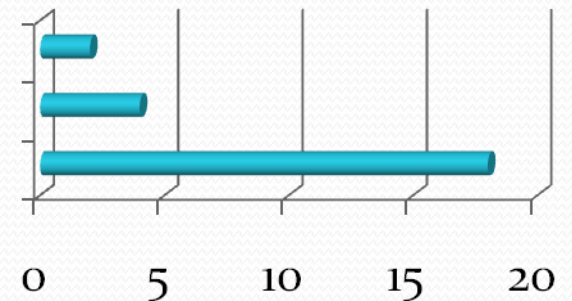


- Direito (11)
- Esquerdo (9)

Alterações comportamento / humor

Cefaleias

Epilepsia



Insular	8
Temporal médio basal	4
Gyrus supramarginal	2
Cíngulo	2
Gyrus temporal superior posterior	1
Gyrus opercularis	1
Pós-central	1
Pré-motor	1

Resultados

- KPS= 87

Oligodendroglioma	12
Astrocitoma fibrilar	2
Astrocitoma difuso	1
Astrocitoma pilocítico	1
Ganglioglioma	1
DNET	3

Disfasia transitória	2
Hemiparésia transitória	2
Fístula LCR	1
Meningite	1

Neuronavegação	6
MEP/SEP	4
<i>Awake surgery</i>	1

>90%	12
<90%	8 (7 > 70%)

1ª cirurgia	15
1ª recidiva	4
2ª recidiva	1

Resultados

- 25% complicações
- Sem défices permanentes
- mRs follow-up= 0.4
- F-U médio= 42.05 meses
- Todos estão vivos
- Sem complicações desde introdução tecnologia e técnicas intra-op (2007)

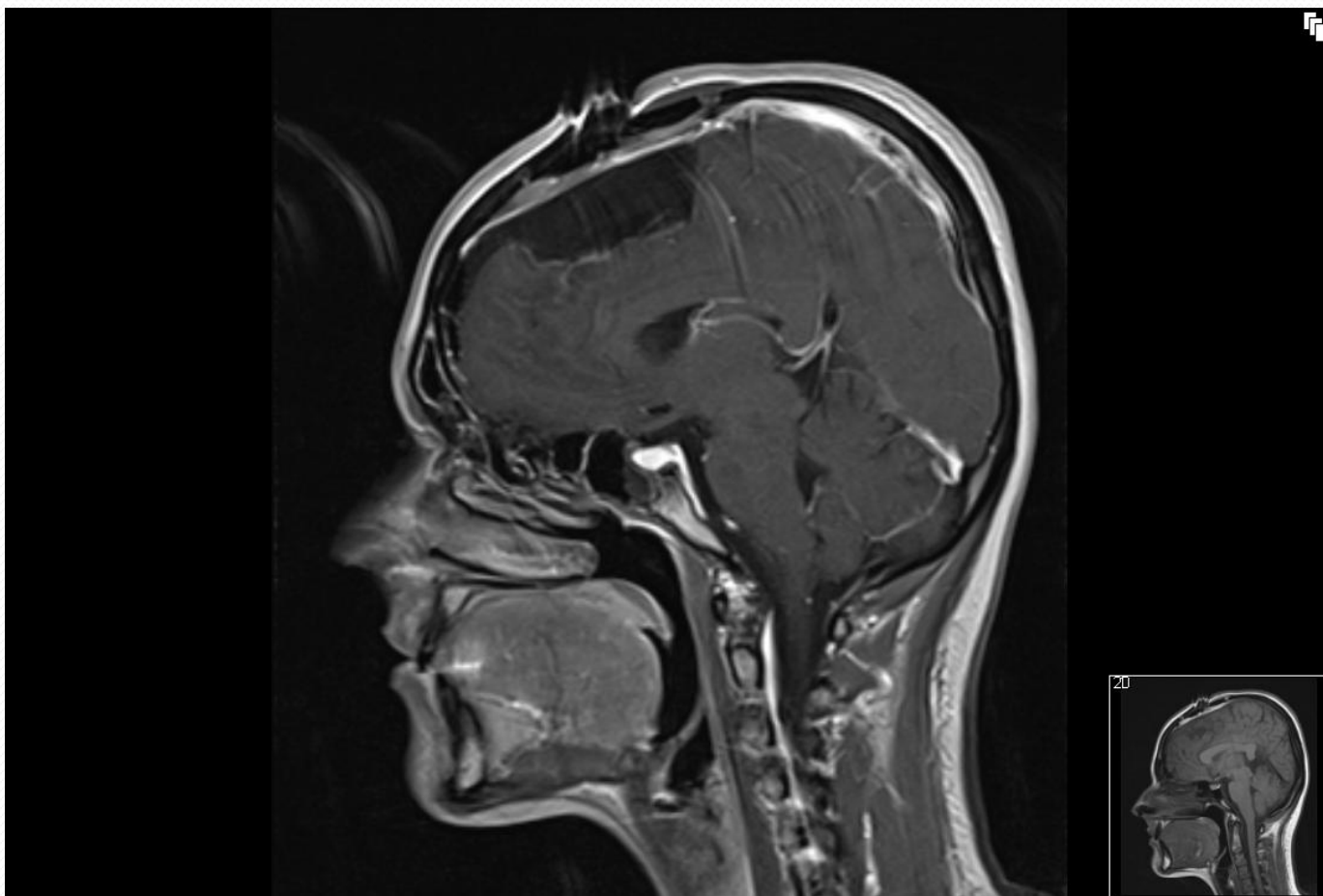
RT	10
QT	1
RT+QT	2
Nenhum	7

Casos clínicos

1 - Oligodendroglioma (II)

Gyrus pré-motor

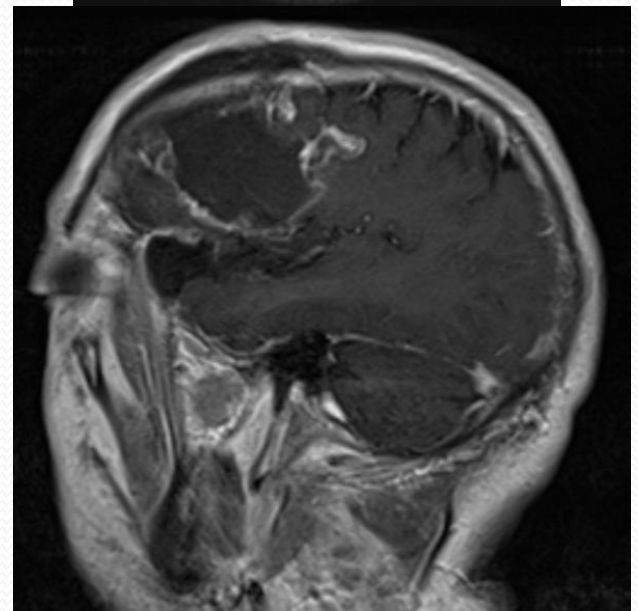
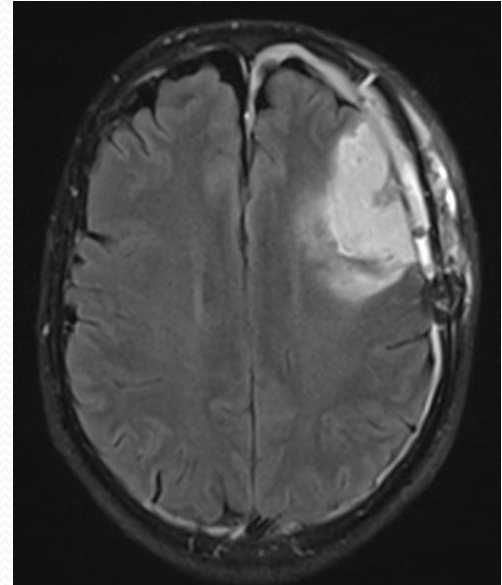
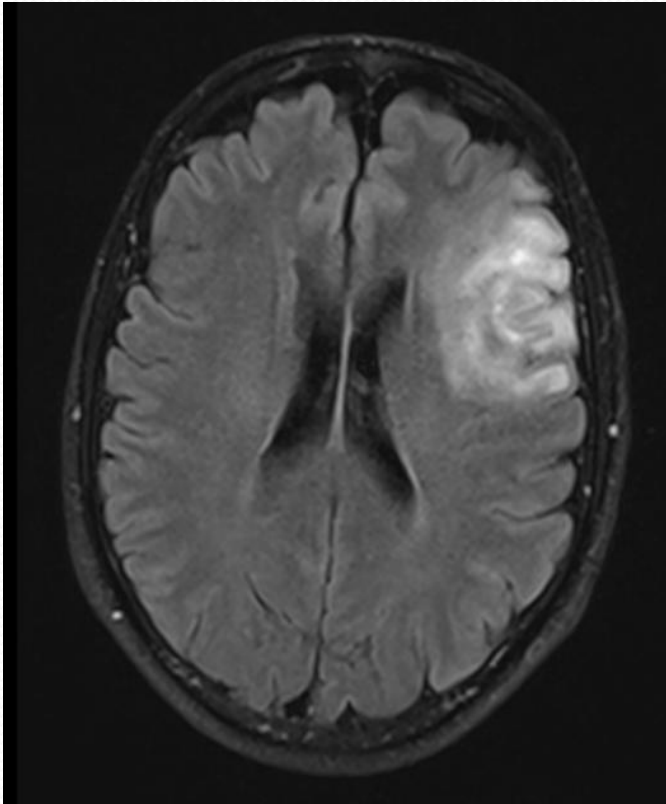
Pós-op >



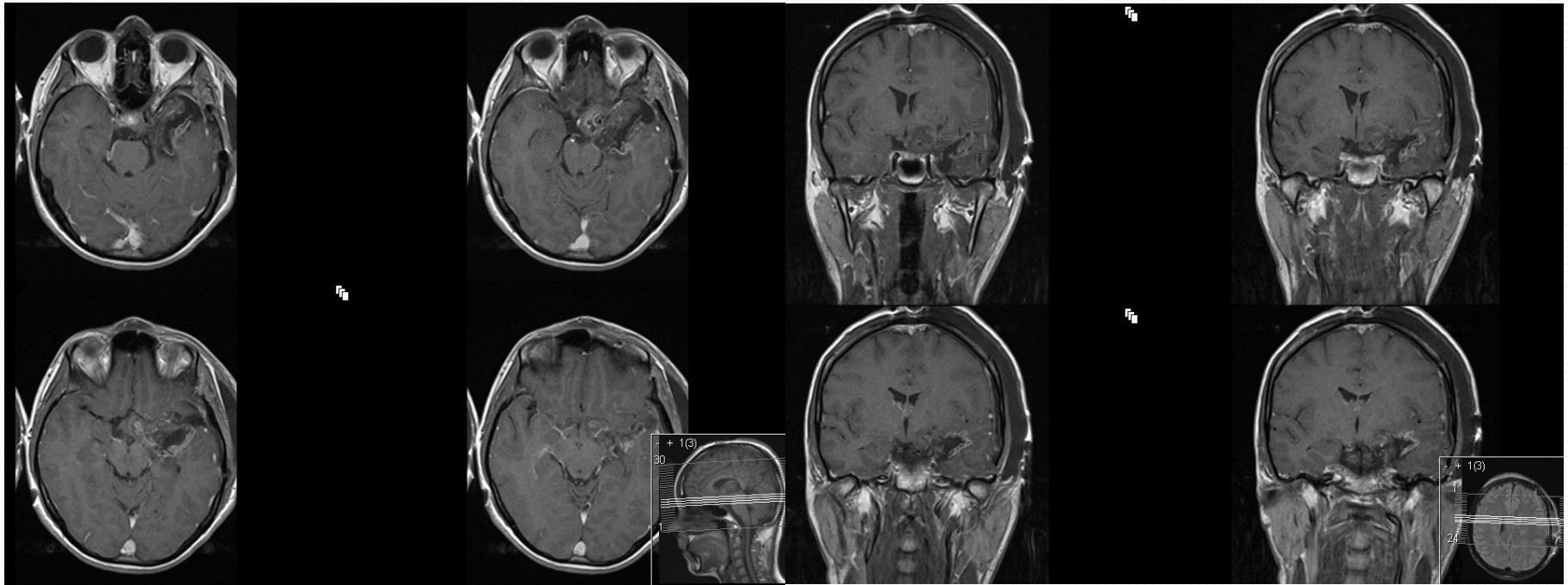
2 - Oligodendroglioma (II)

Fronto-insular >

Awake surgery

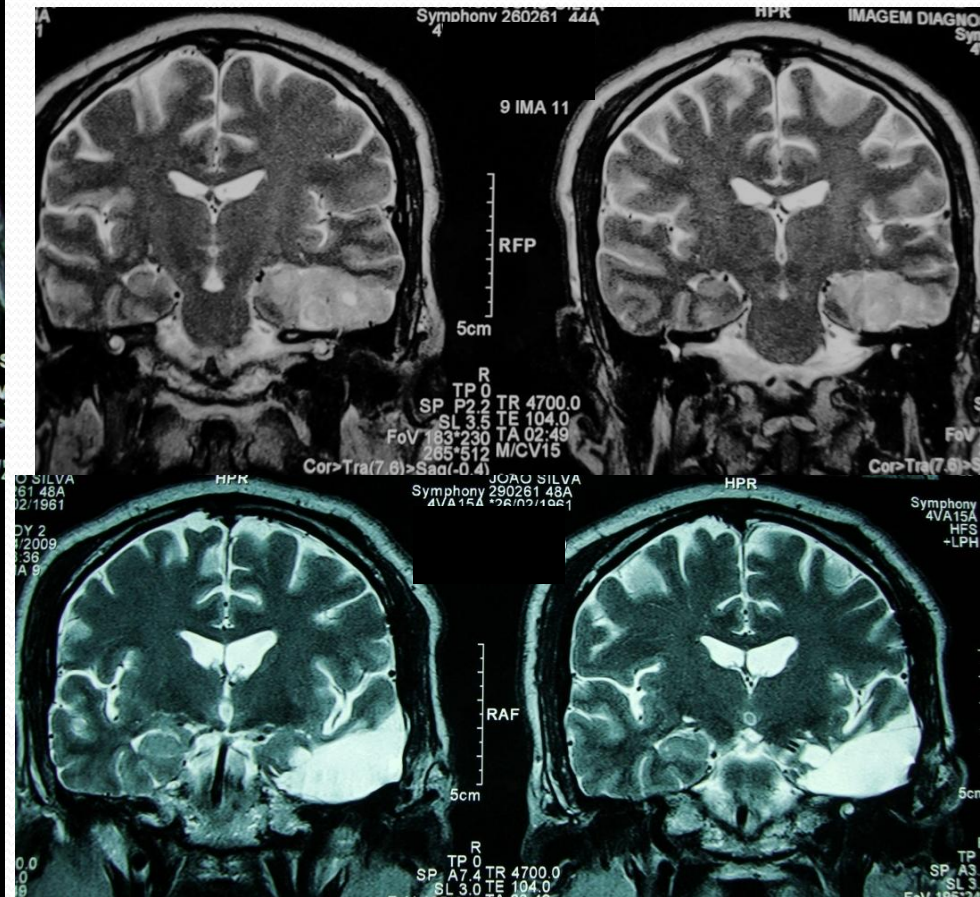
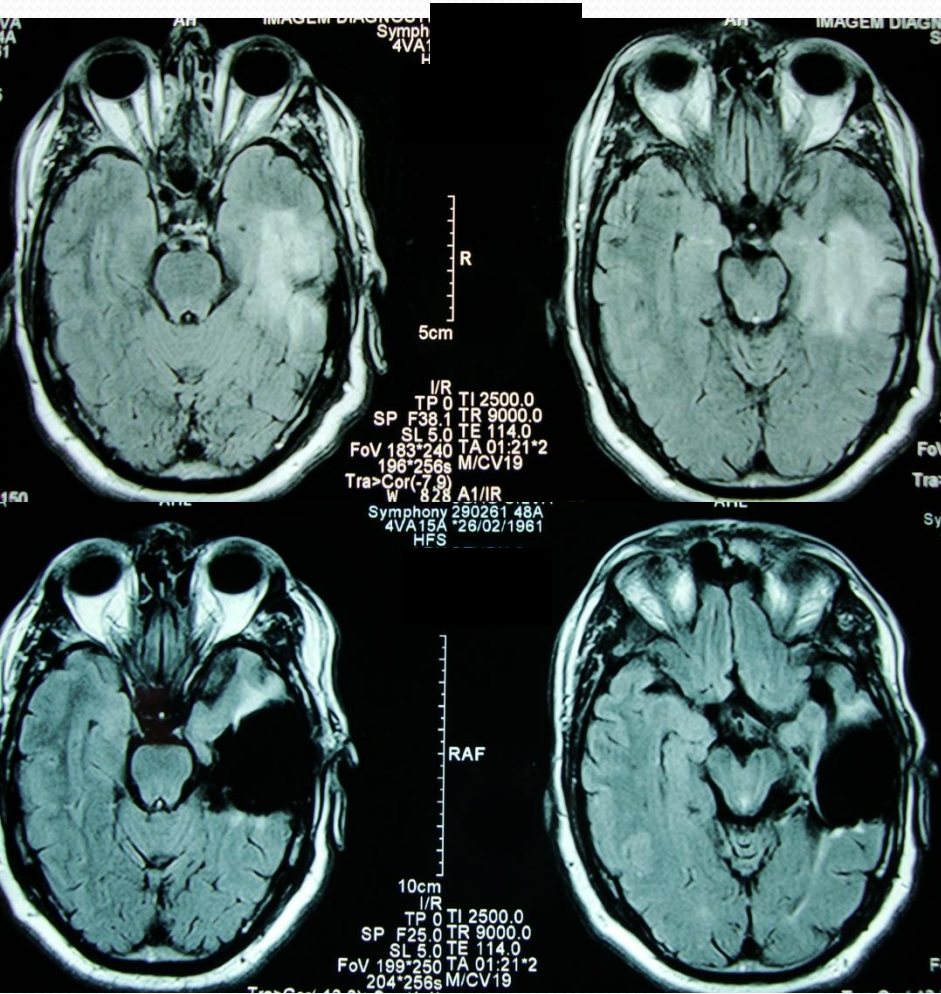


3 – Astrocitoma pilocítico (I) TMB (uncus, hipocampo) Pós-op >



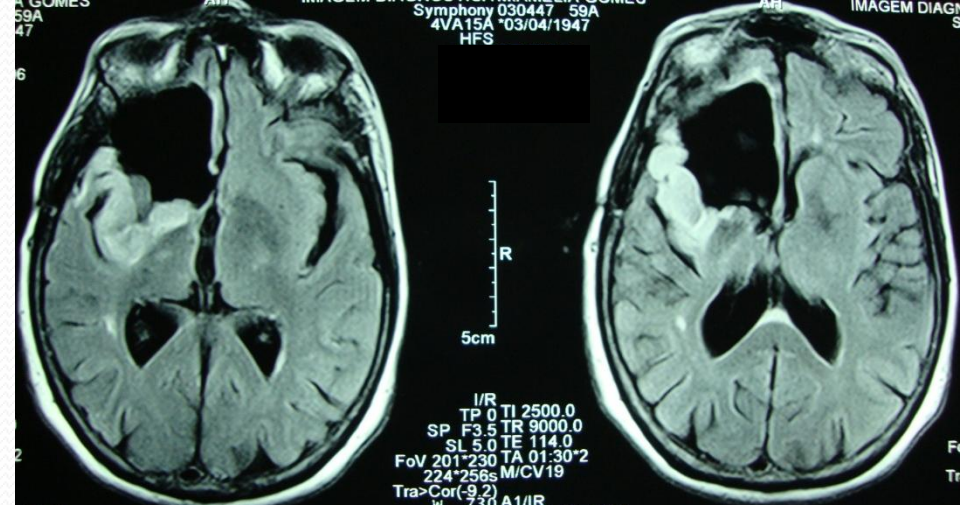
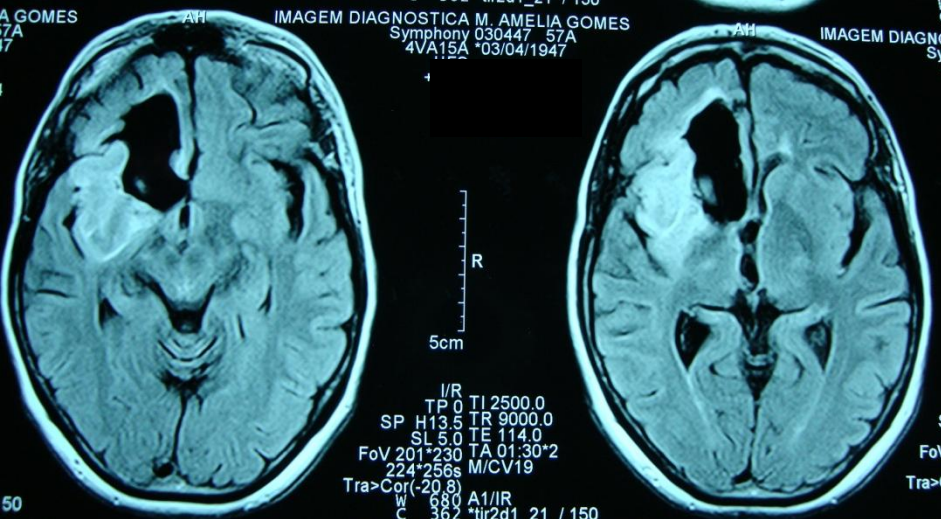
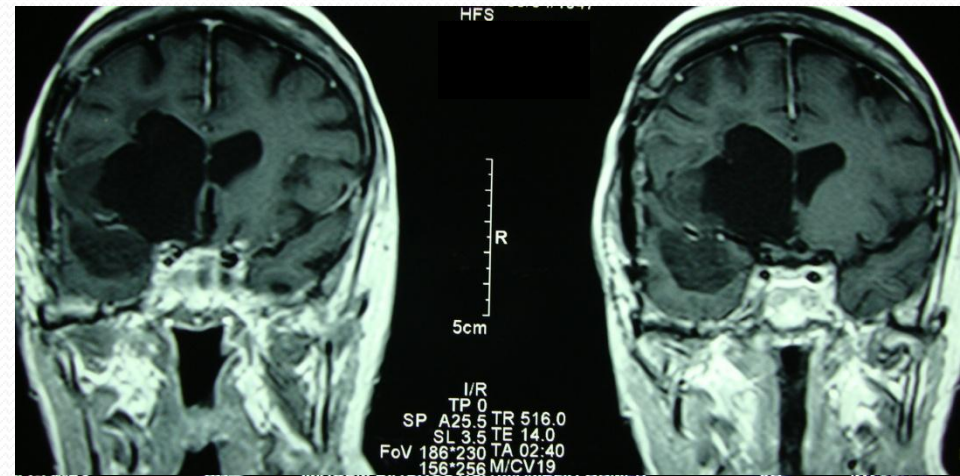
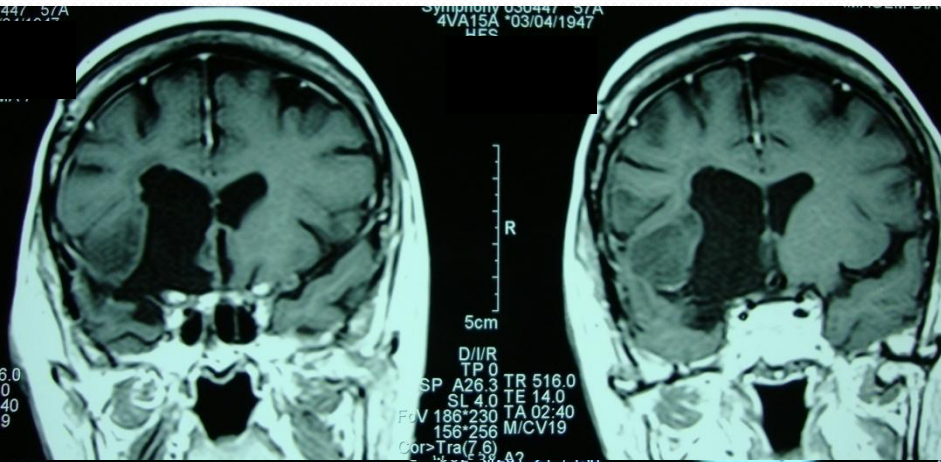
4 – Oligodendroglioma (II)

TMB (hipocampo, para-hipocampo, gyrus ambiens) >

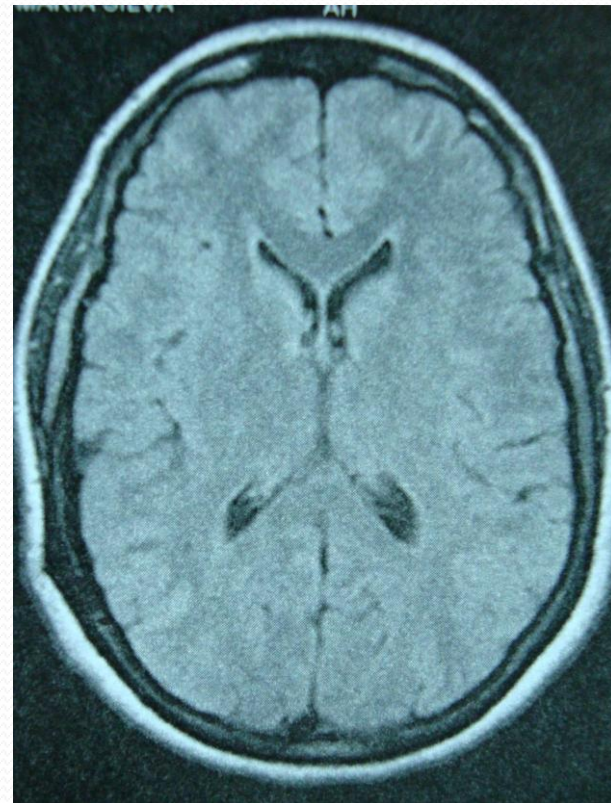
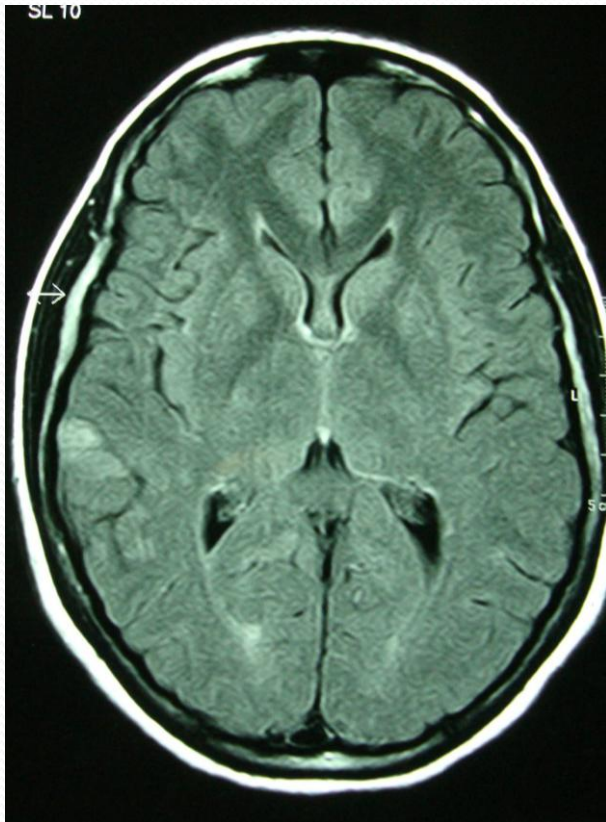


6 – Oligodendroglioma (II)

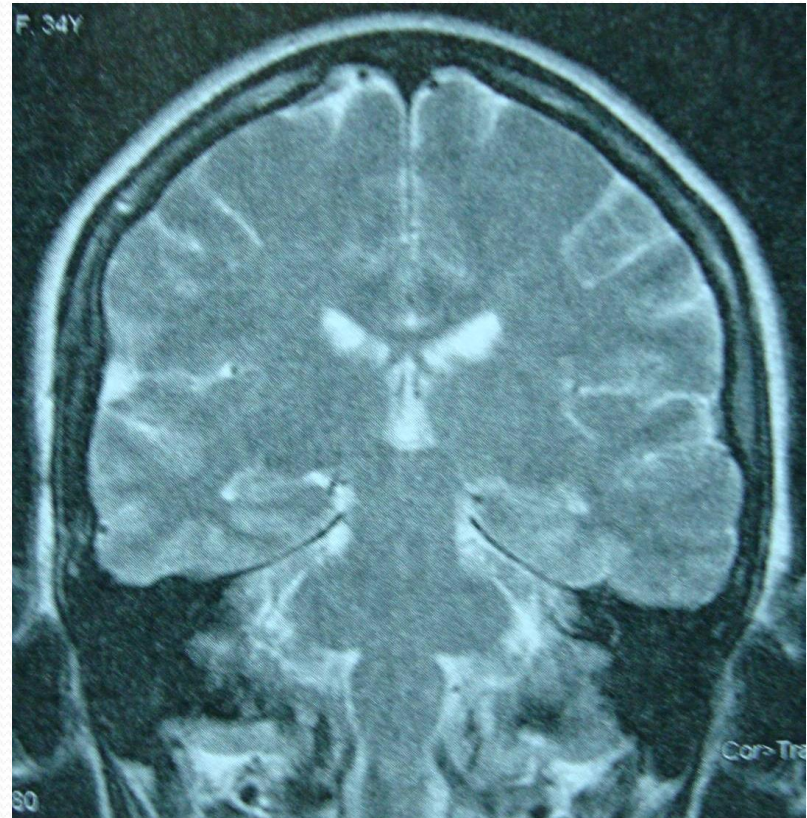
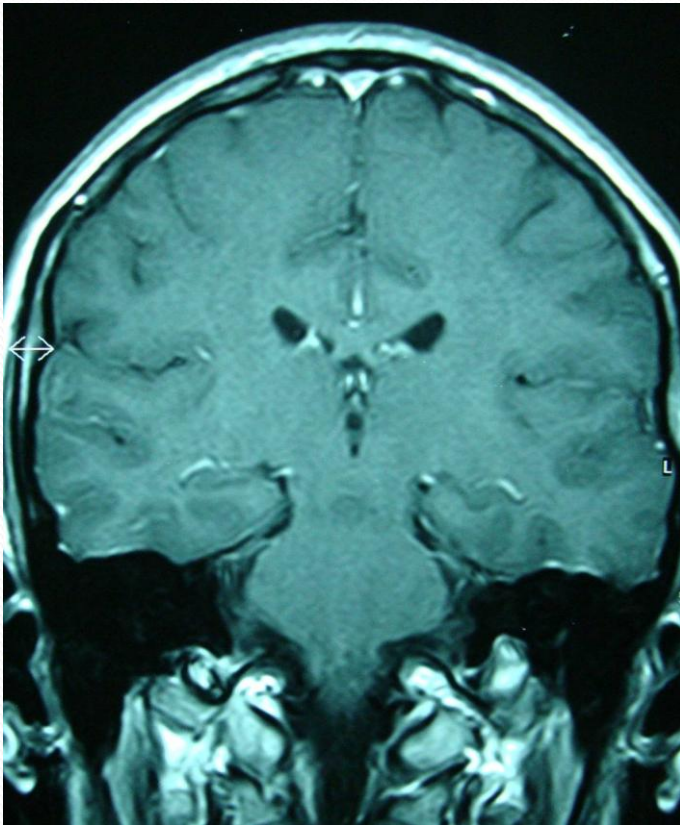
Insular, putámen, cápsula externa (1ª R 5a) <



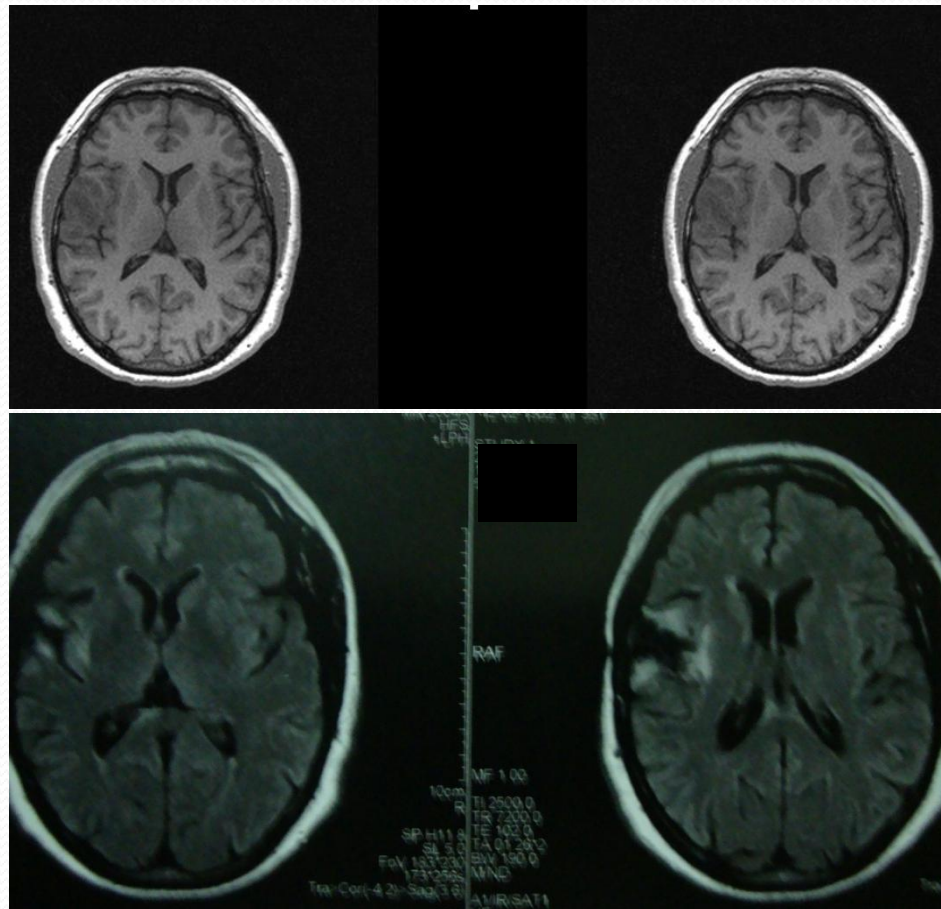
7 – Oligodendroglioma (II) Gyrus temporal superior posterior >



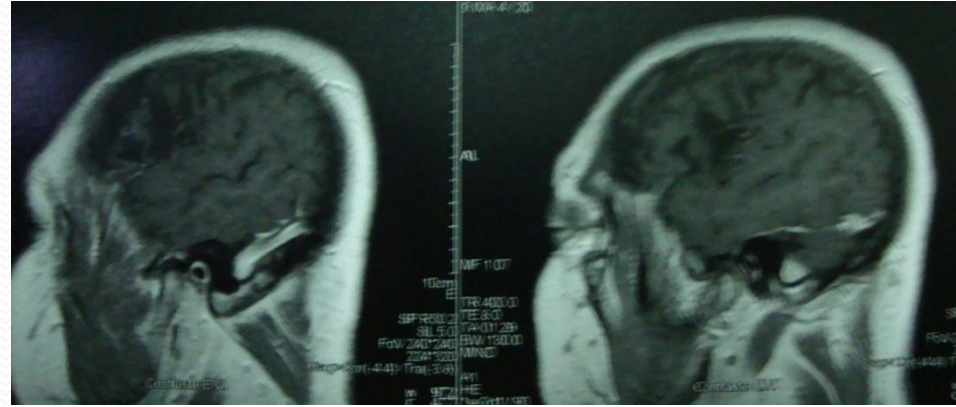
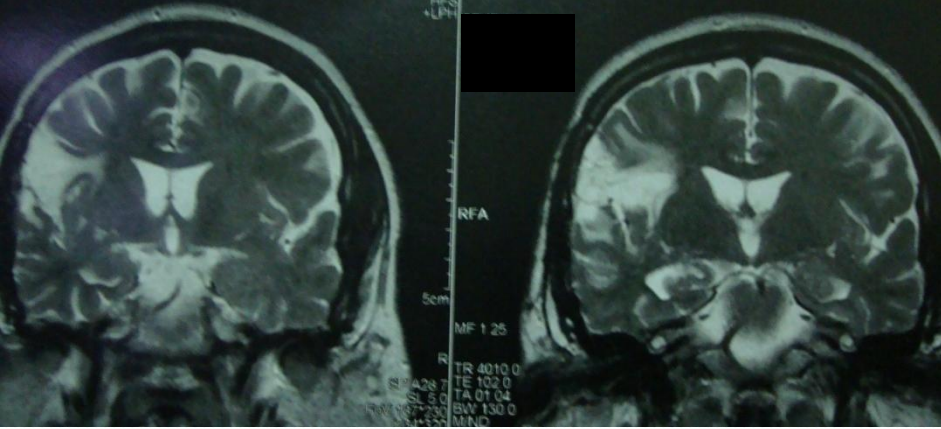
7 – Oligodendroglioma (II) Gyrus temporal superior posterior >



9 – Oligodendroglioma (II) Gyrus opercularis <

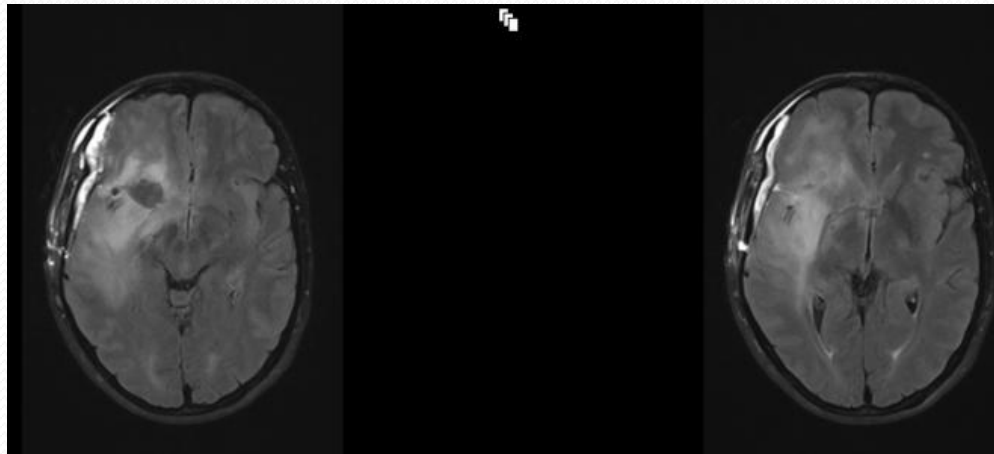
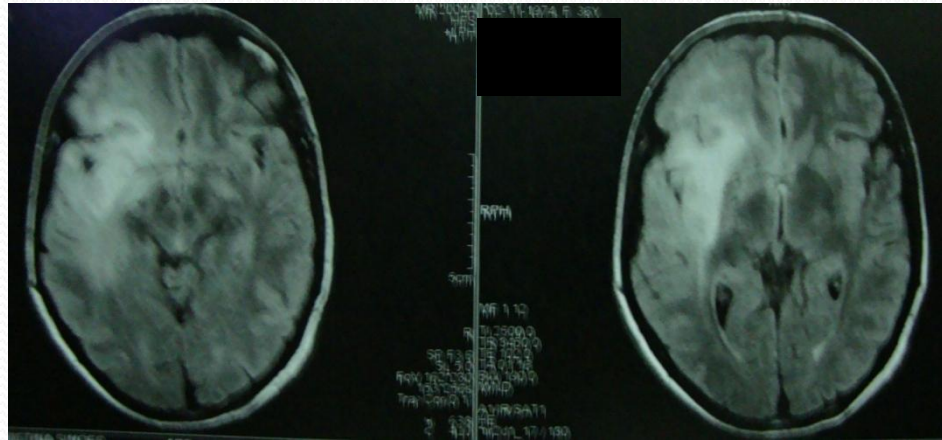


9 – Oligodendroglioma (II) Gyrus opercularis Pós-op <

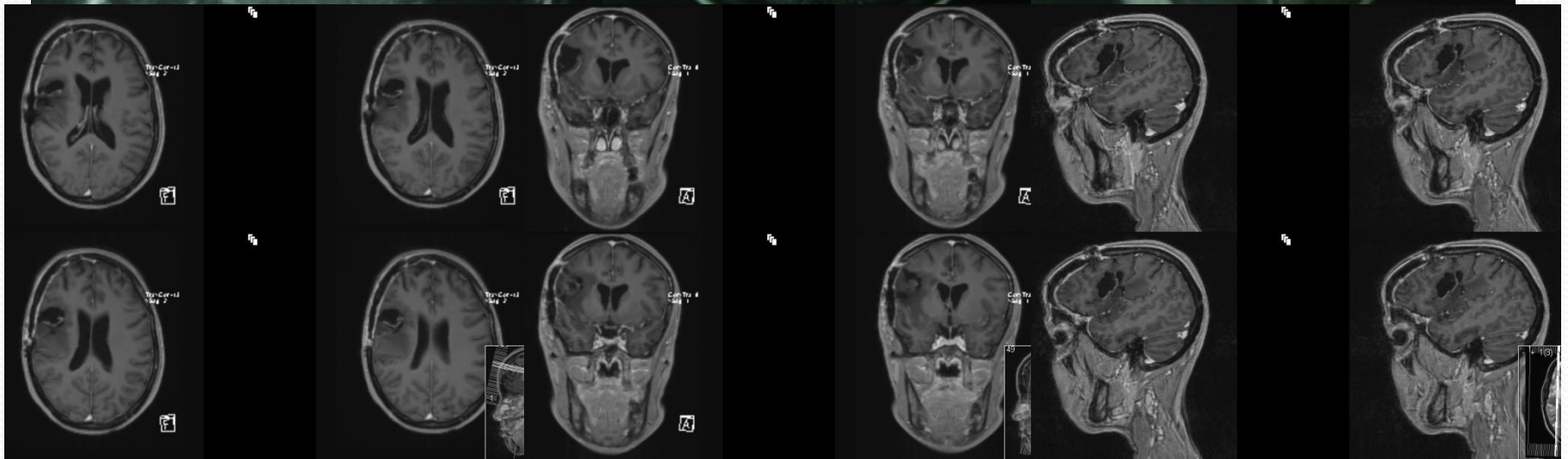
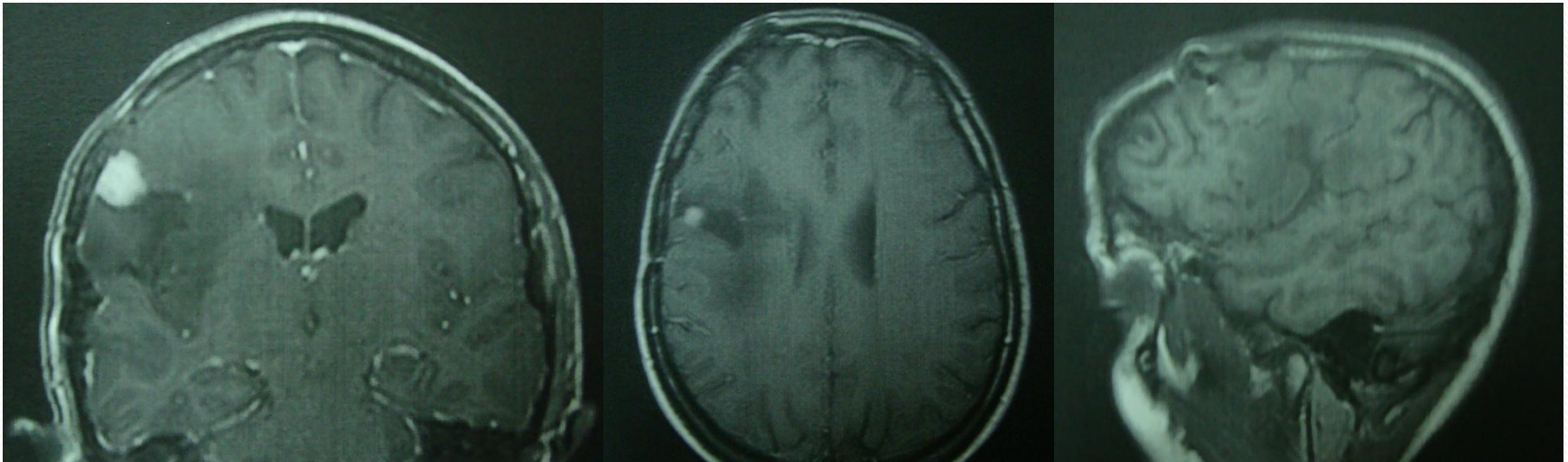


10 – Oligodendroglioma (II)

Insular <

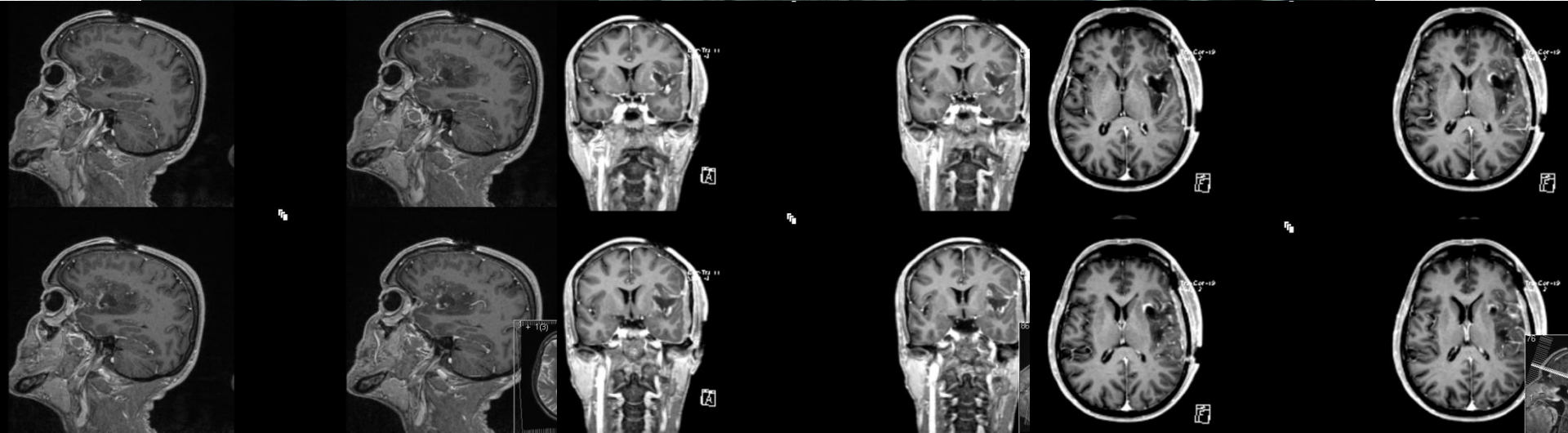
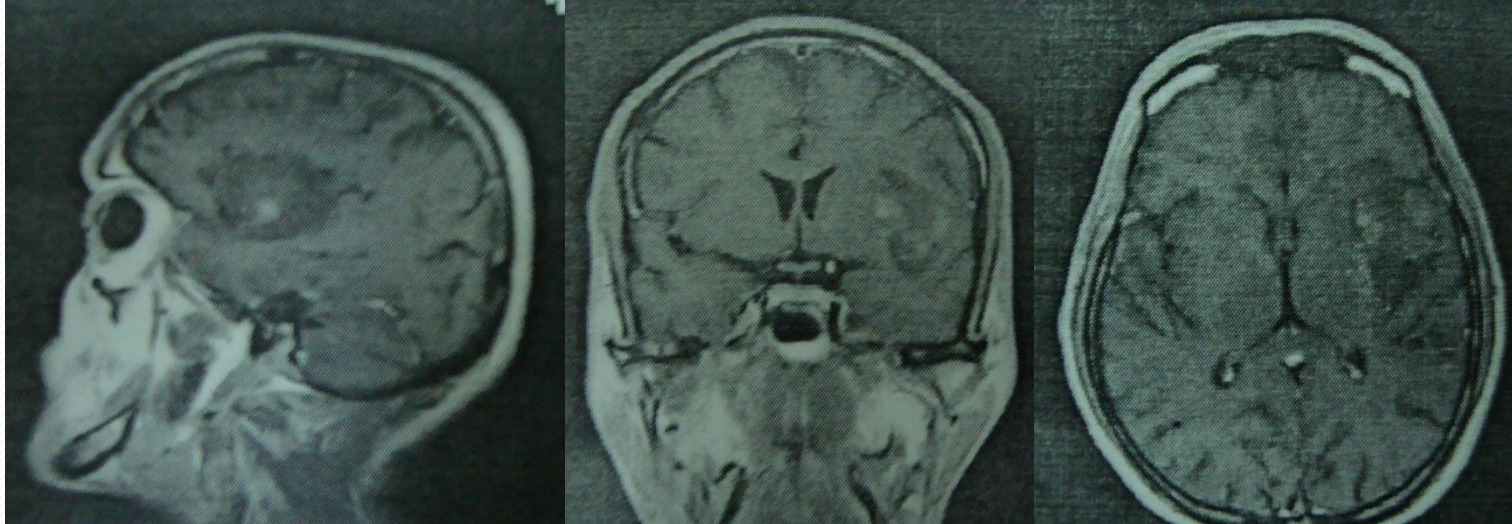


11 - Oligodendroglioma (II) Fronto-insular (1ª R 3a) <



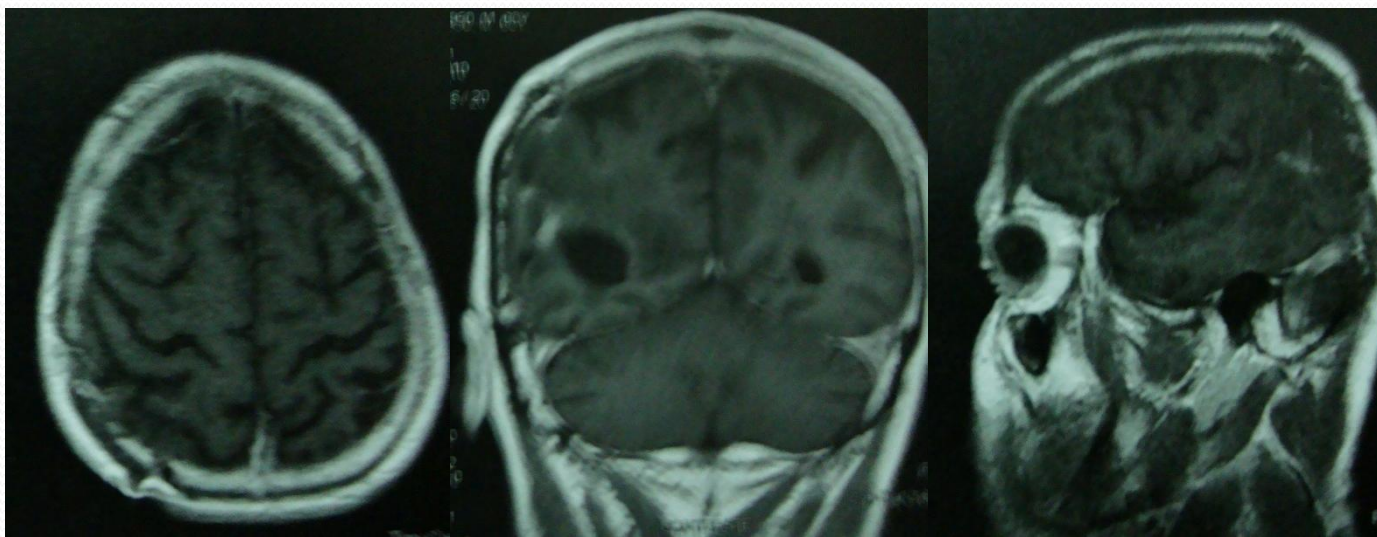
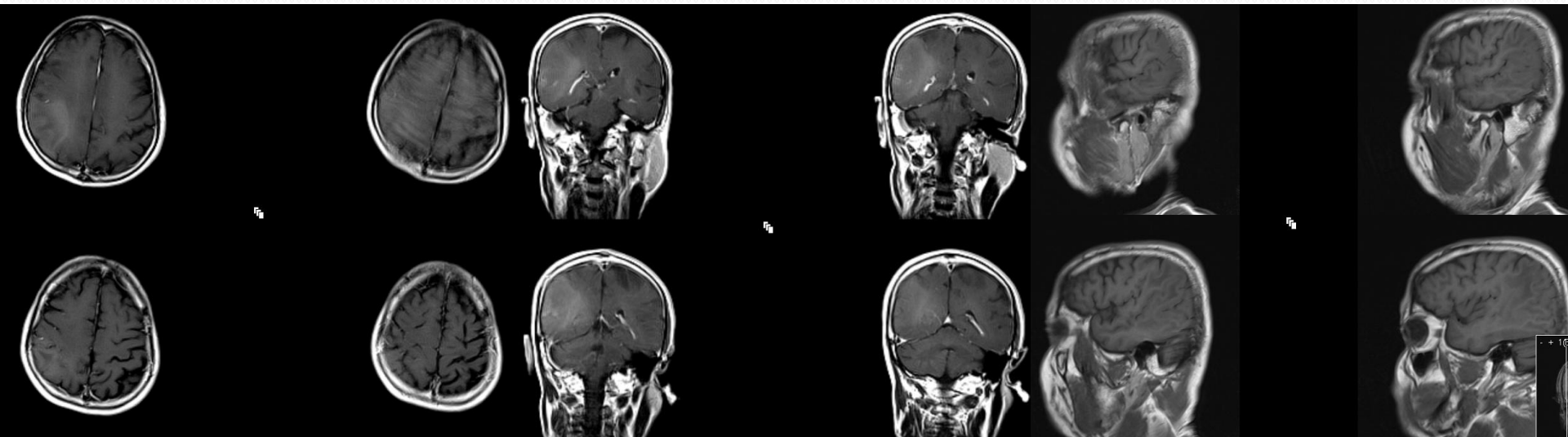
12 - Oligodendroglioma (II)

Insular >

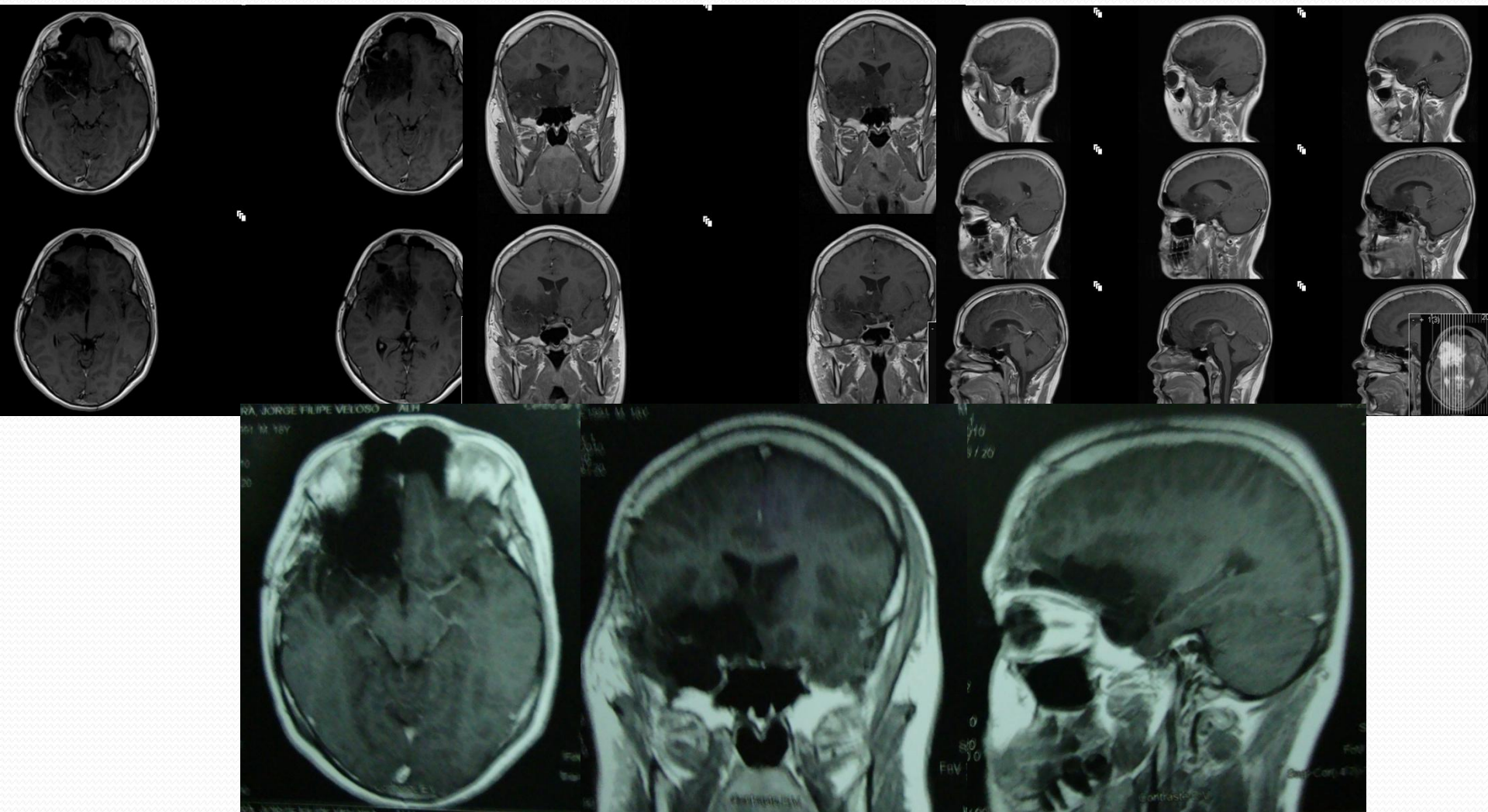


13 – Astrocitoma difuso (II)

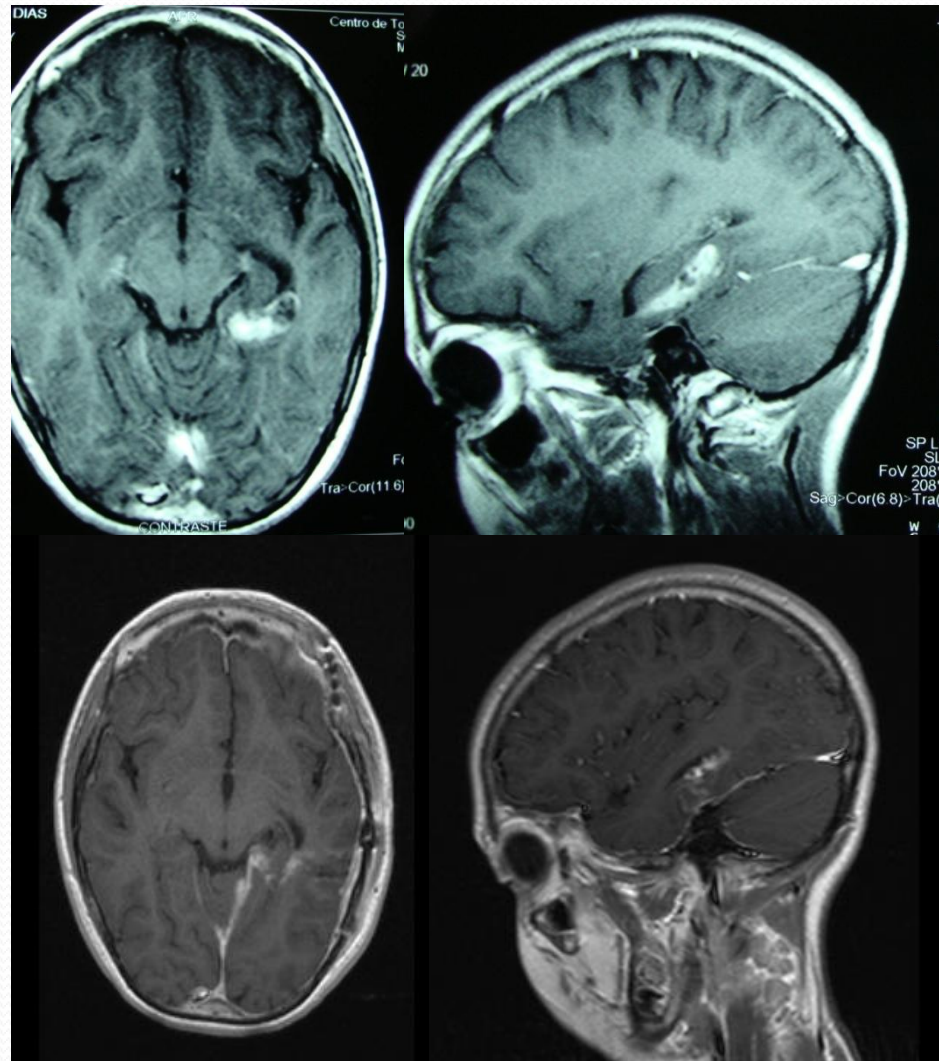
Sulco pós-central >



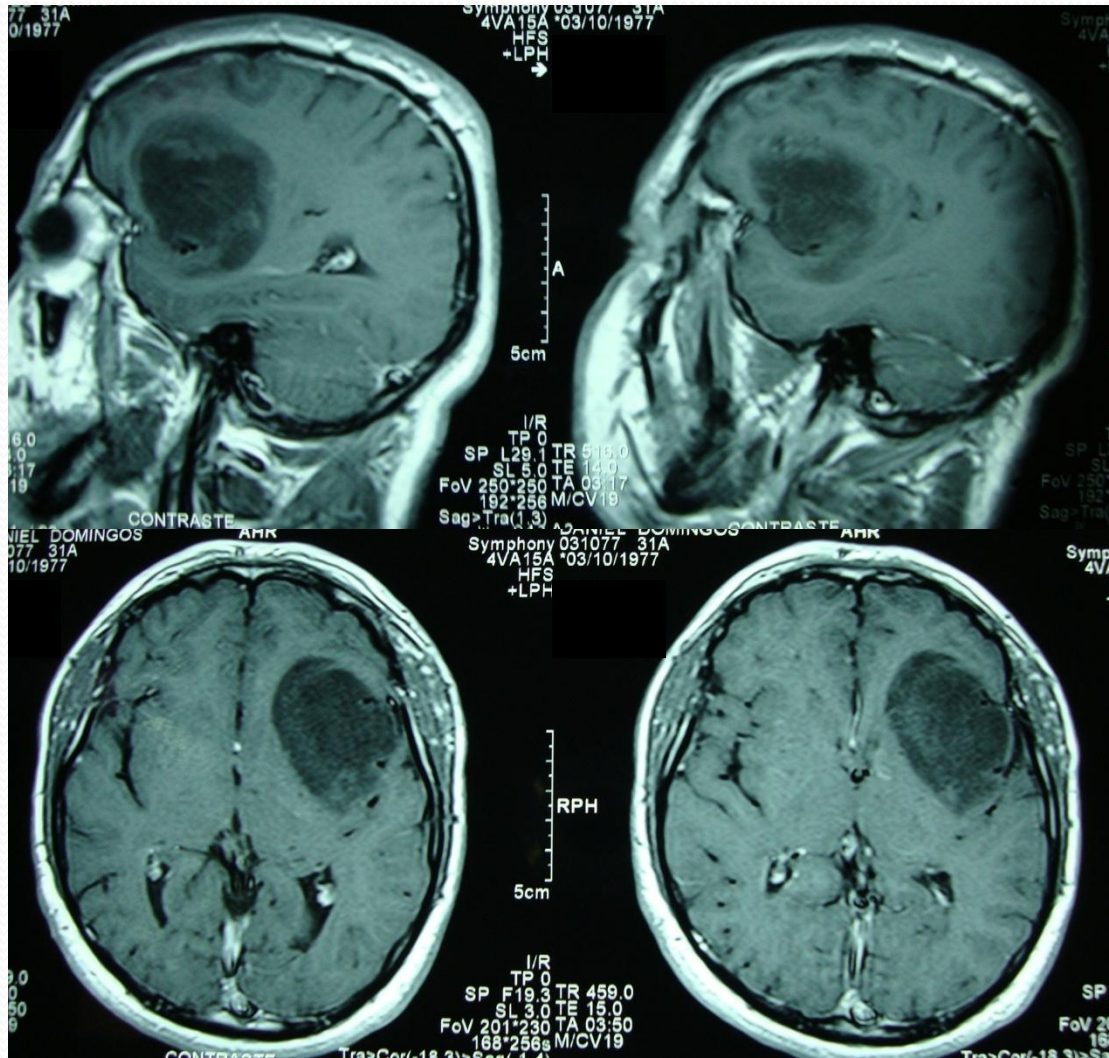
14 – DNET/glioma (I) Insular (2ªR, 1998-2001-2009) >



15 – Ganglioglioma TMB (hipocampo) <

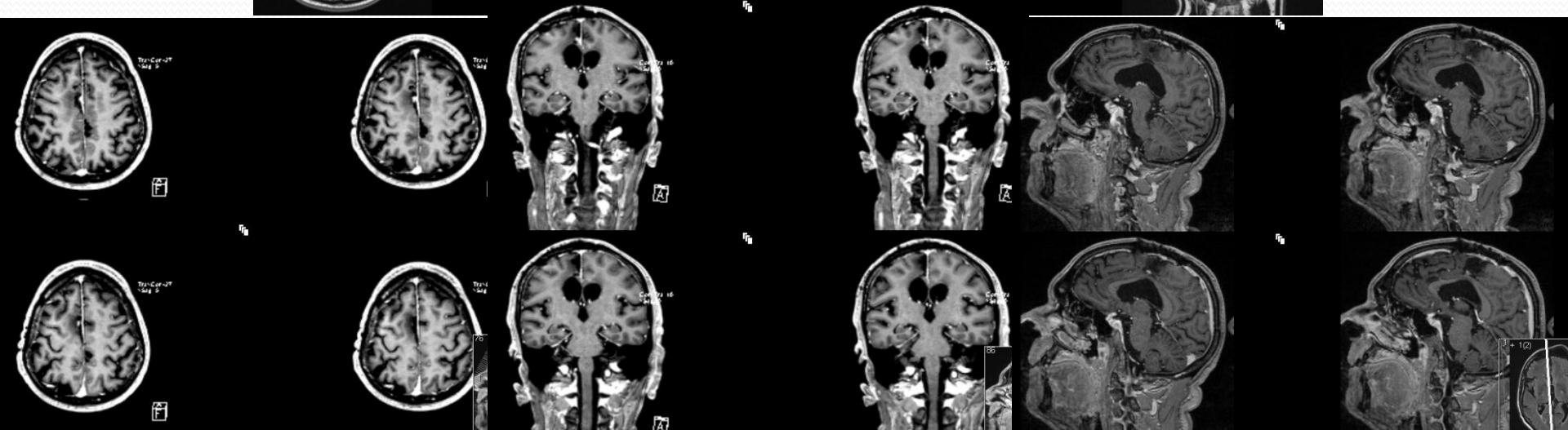
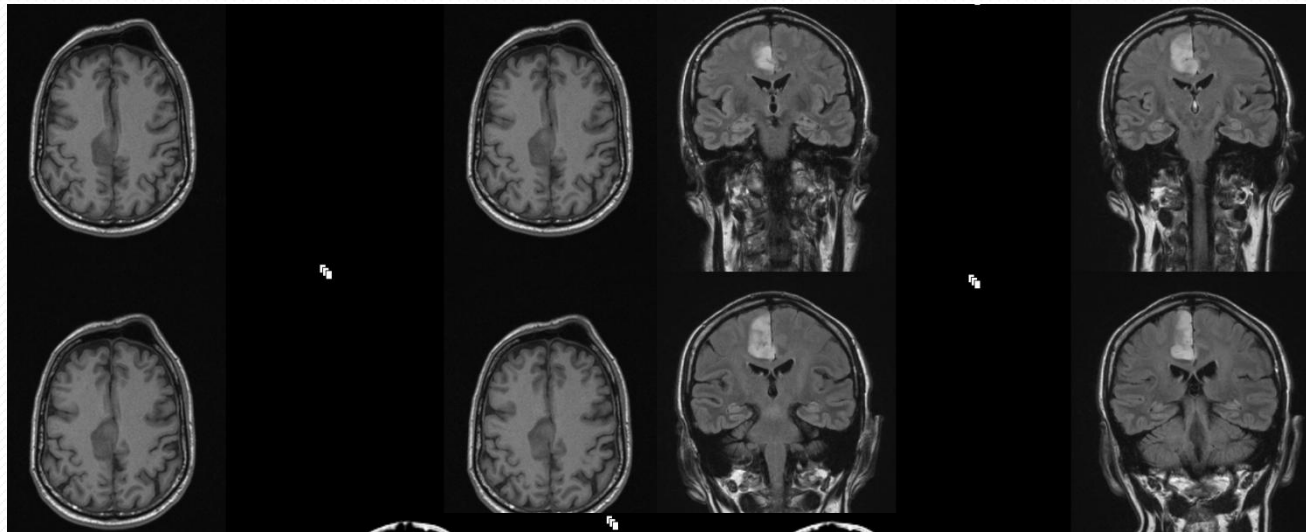


16 – Oligodendroglioma Fronto-insular Pré-op >



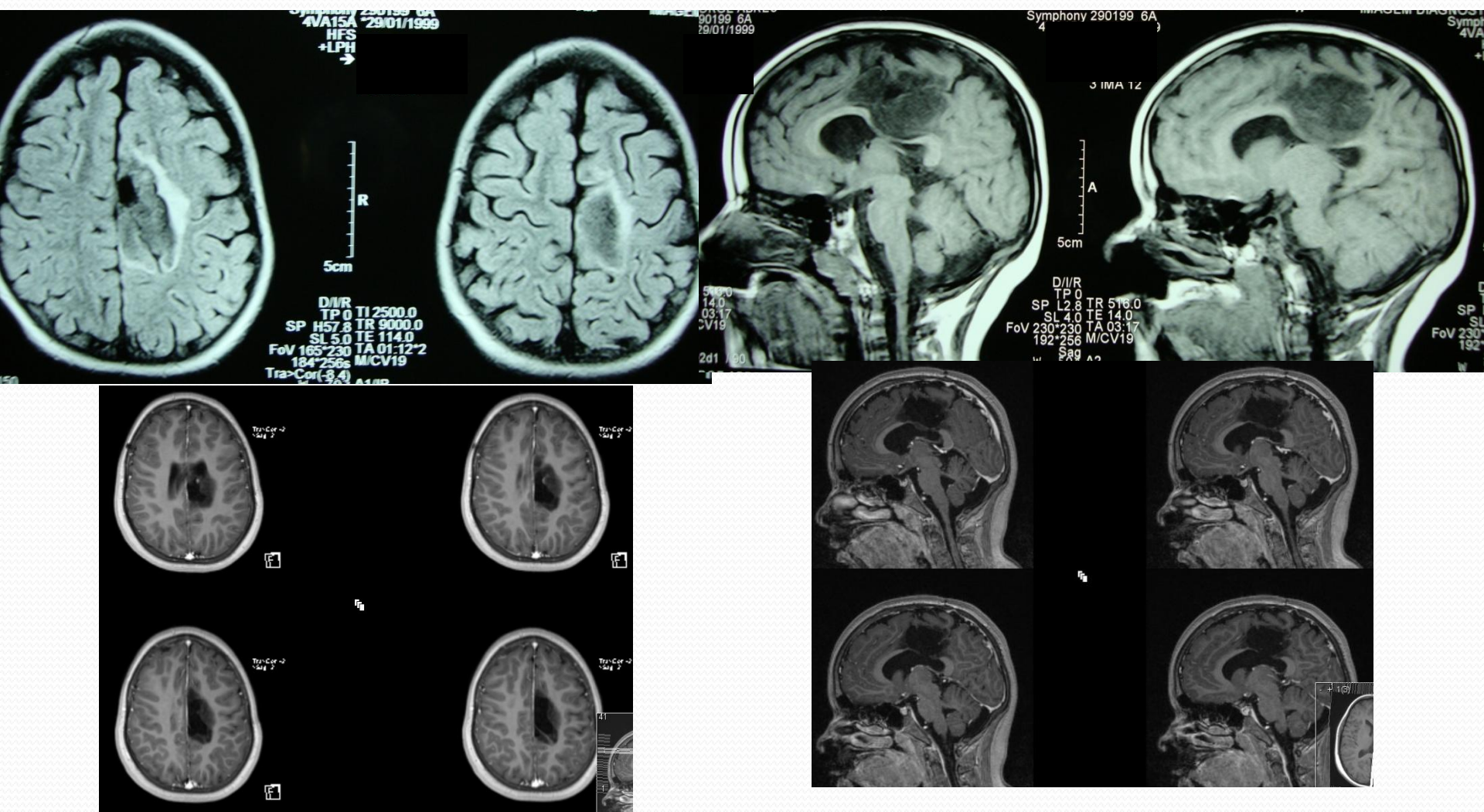
17 – Oligodendroglioma (II)

Cíngulo >



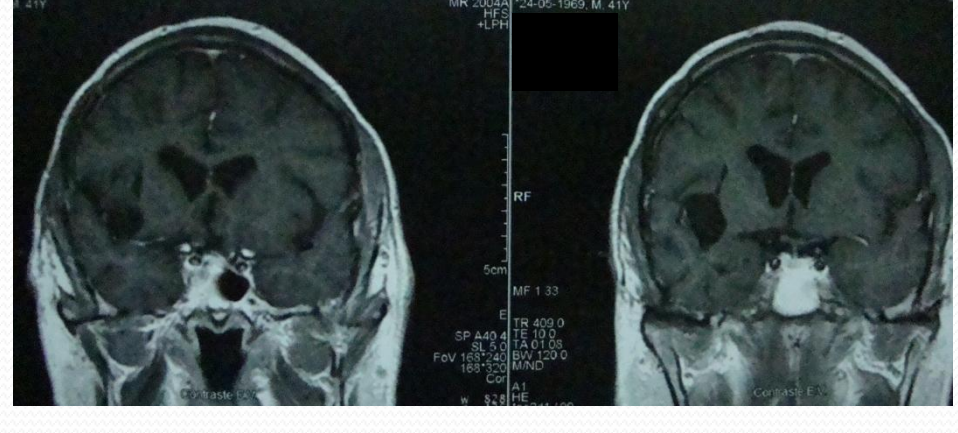
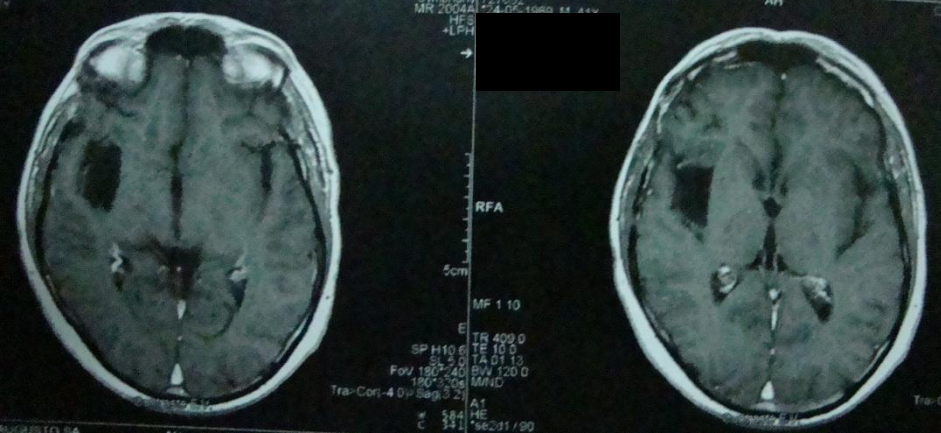
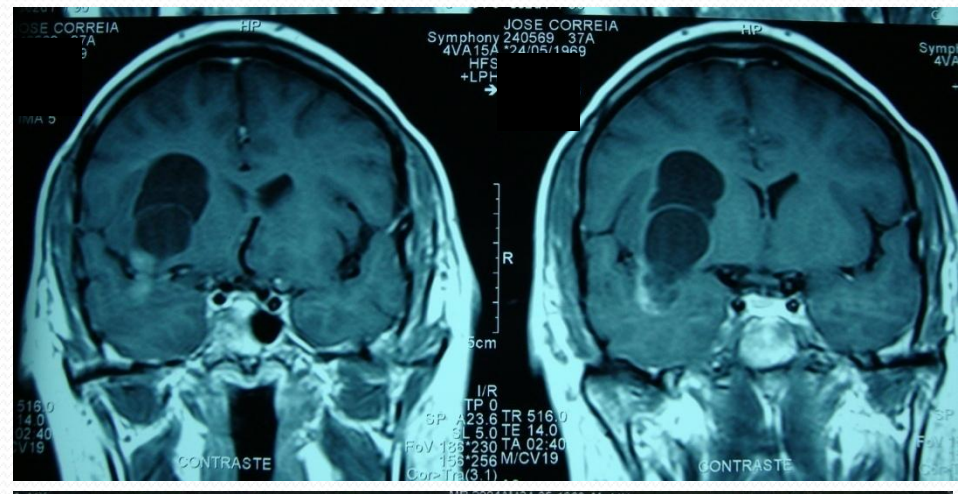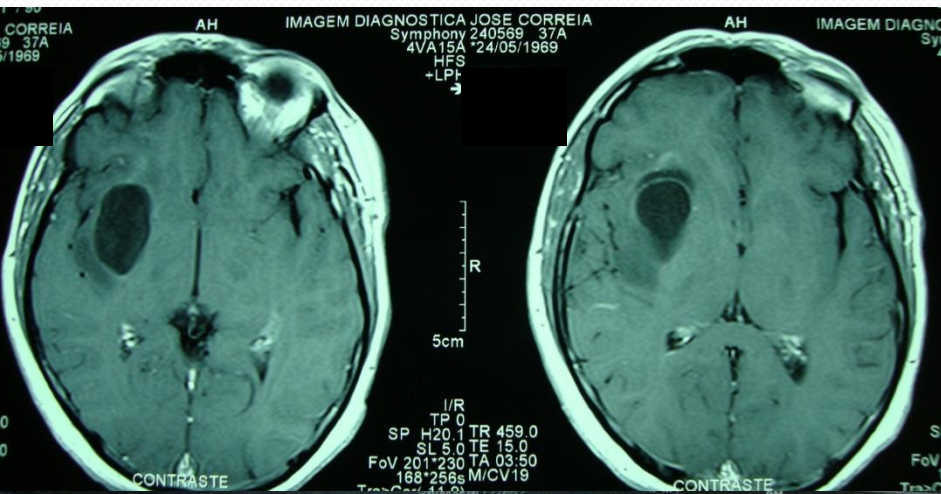
18 – DNET

Fronto-cingular, corpo caloso (1ªR, 3a) >



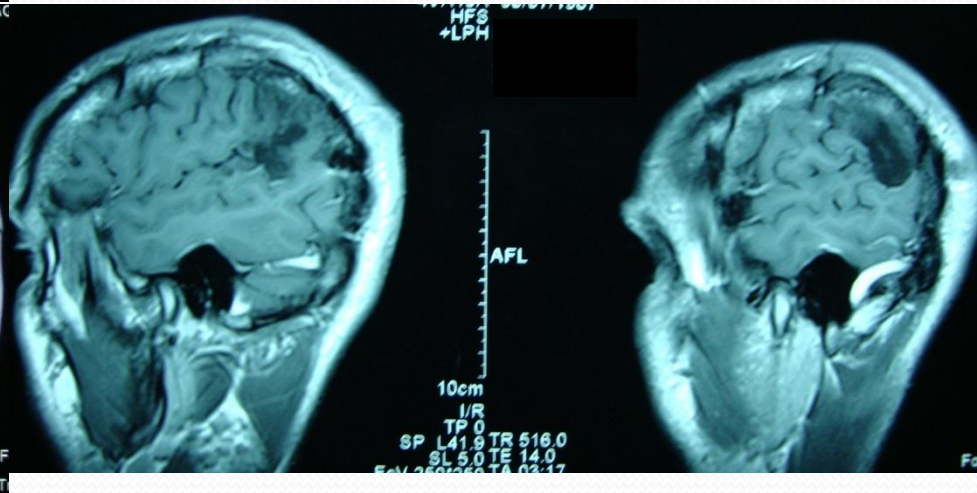
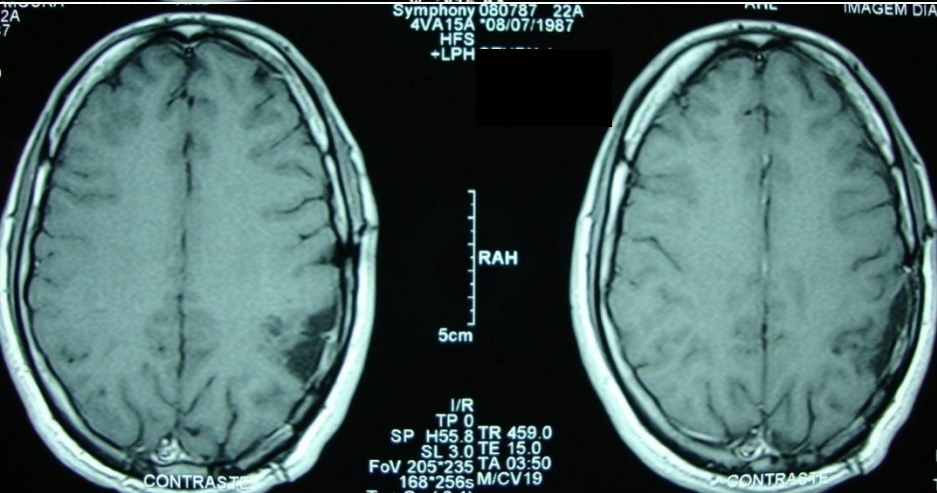
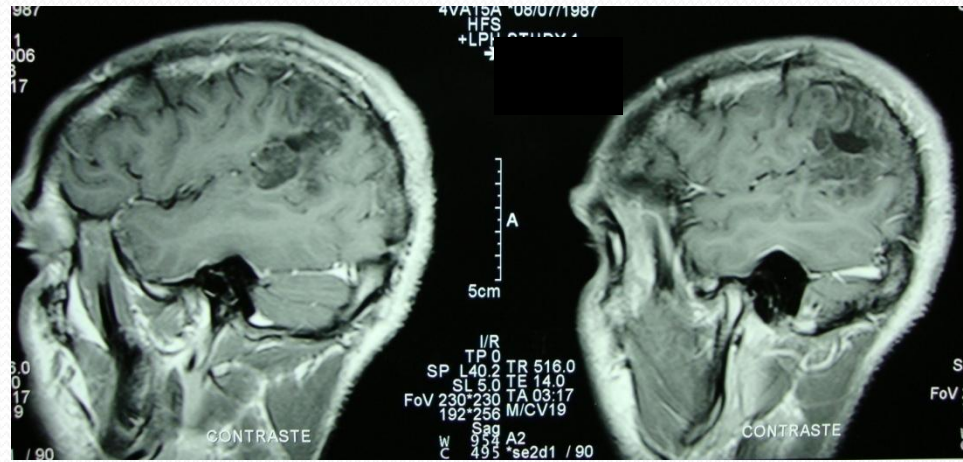
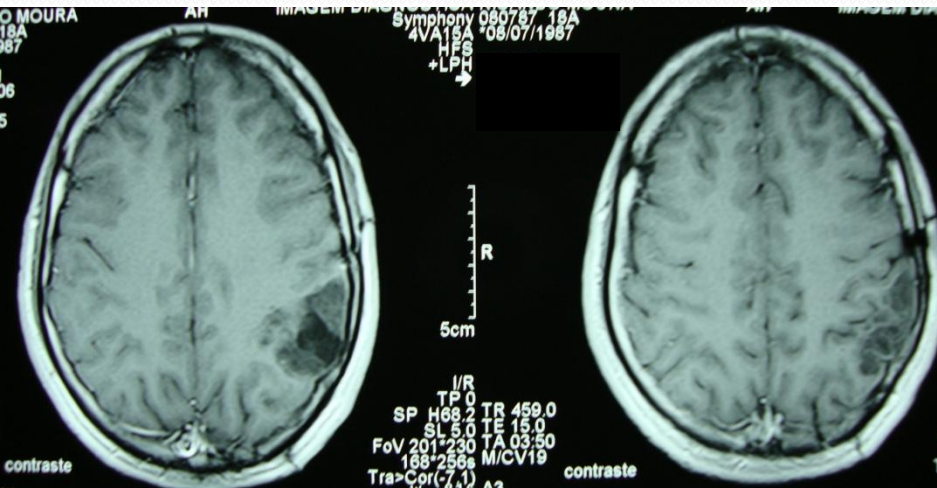
19 – Astrocitoma fibrilar (II)

Insular >



20 – DNET

Parietal, pós-central, gyrus supra-marginal (1ª R 5a) <



Conclusões

Conclusões

- Minimização riscos (tecnologia intraop, mapeamento)
- “Awake surgery” *gold standard* áreas eloquentes (linguagem)
- Riscos atitude “*wait and see*” e RT
- Extensão ressecção
- QT neoadjuvante
- Especialização neurooncológica
- Abordagem multidisciplinar