

TRATAMENTOS INTRA-VÍTREOS
REGIMES DE TRATAMENTO E GESTÃO DA CONSULTA

RETINA UPDATE

Caso Clínico

Aflibercept
na DMI neovascular
Primeiras Impressões...

Luís Mendonça



Hospital
Braga



CUF
porto
hospital



OFTALCONDE
CLÍNICA OFTALMOLÓGICA



Mulher Caucasiana, 82 anos

diminuição gradual da AV ODE com meses de evolução

História Médica Prévia:

(i) Ocular

- Cirurgia de Catarata ODE (2010)

(ii) Sistémica

- AdenoCa mamário (2008)
. Cx > QTx

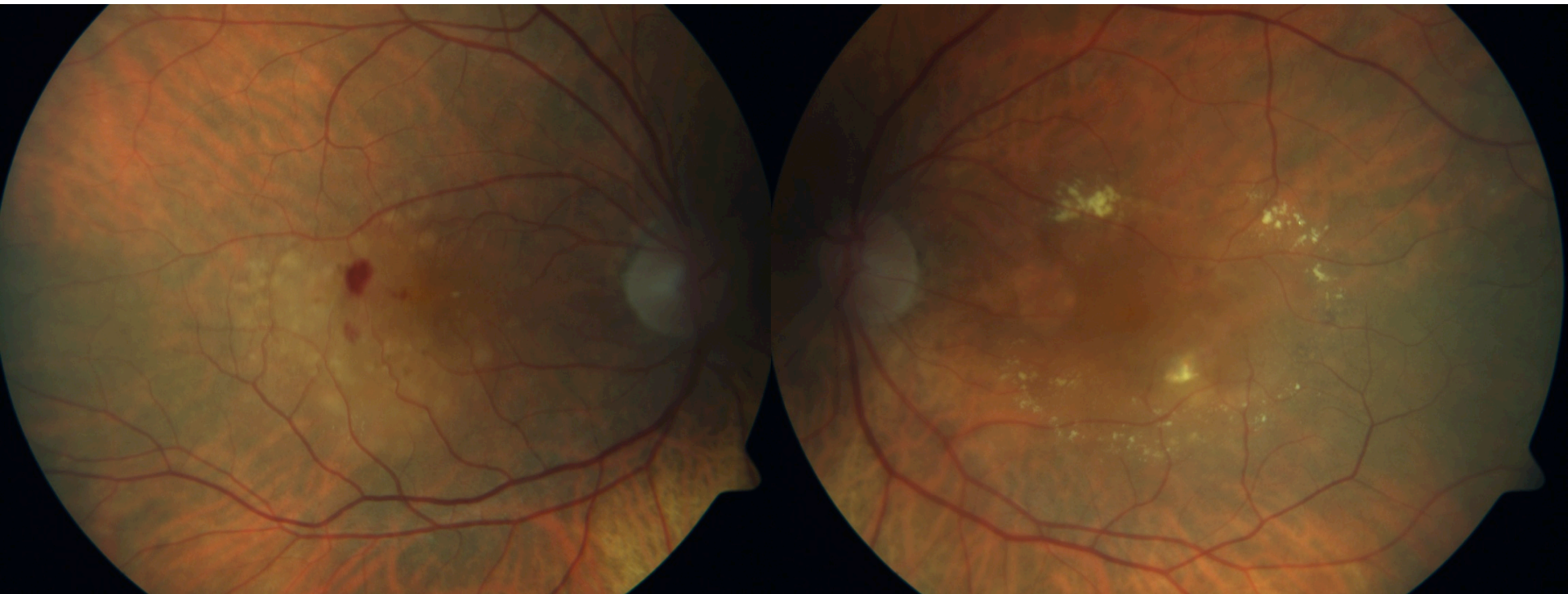
OD: 20/200

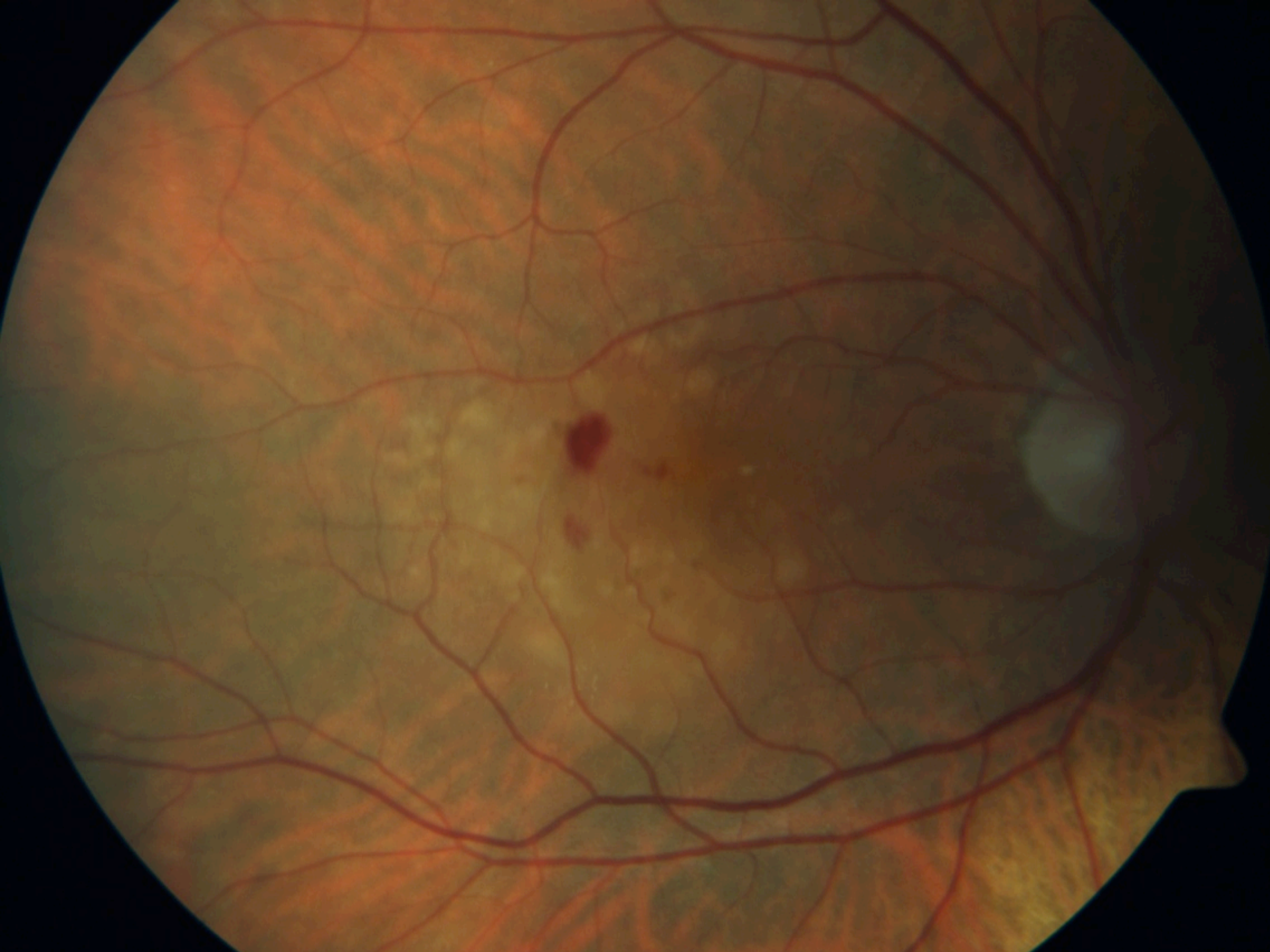OE: 20/400

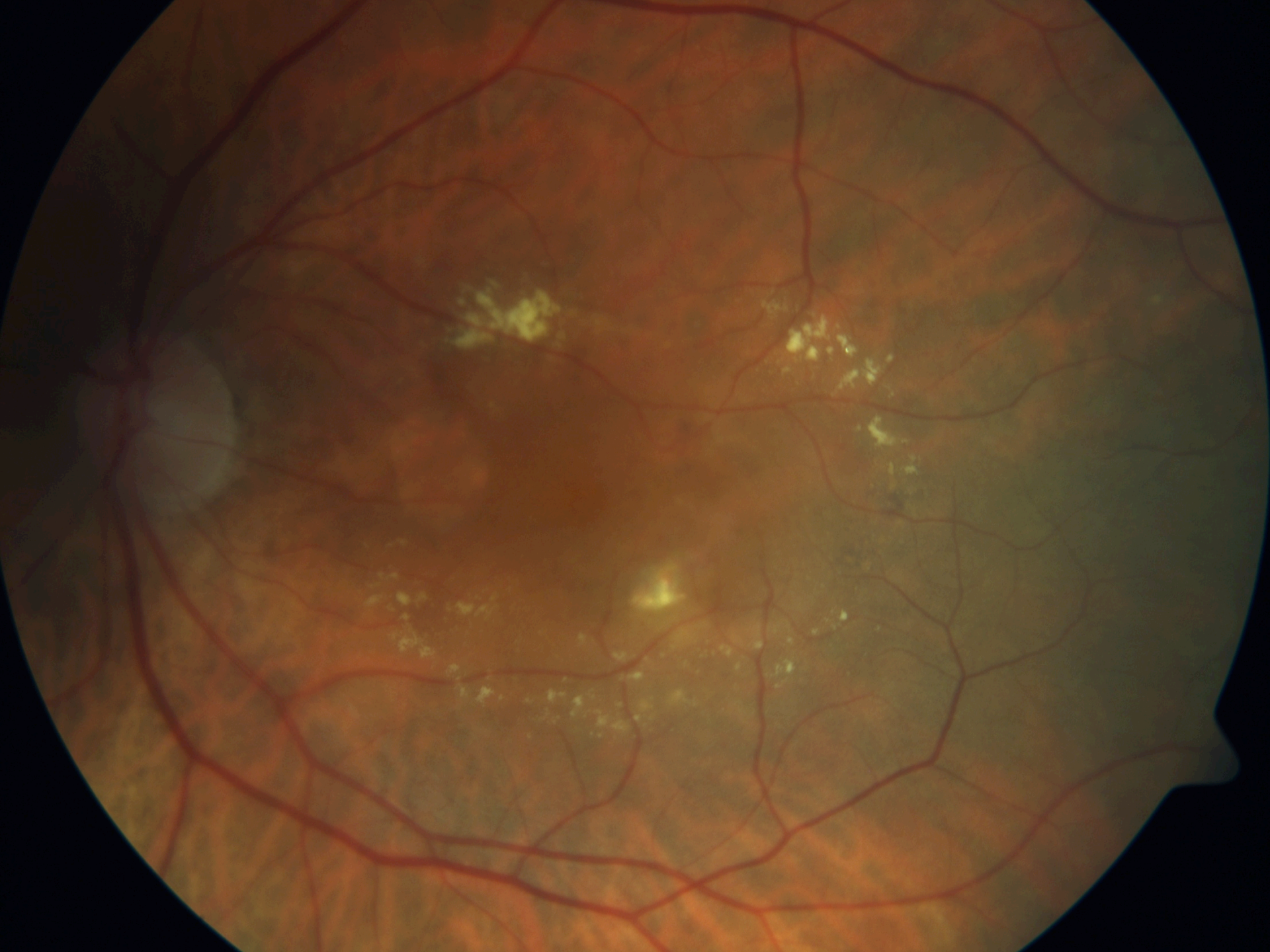

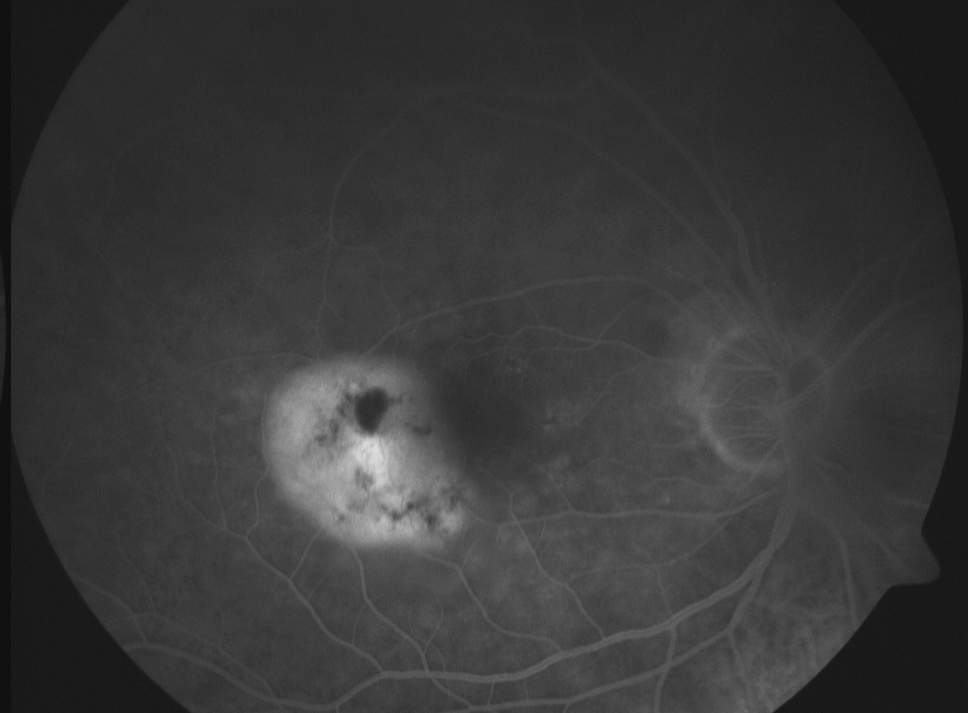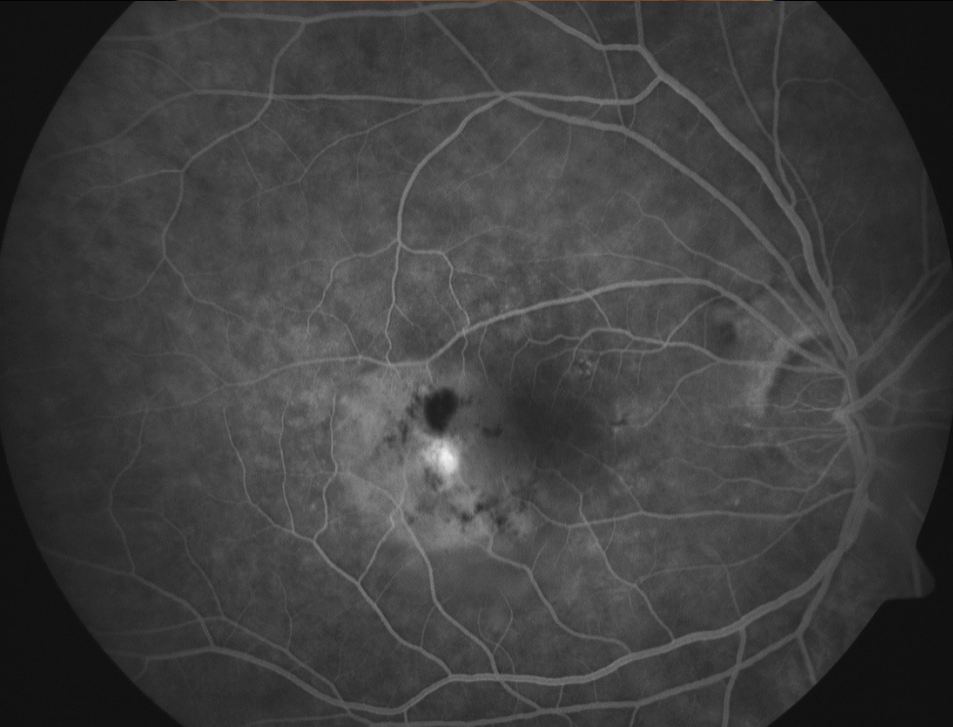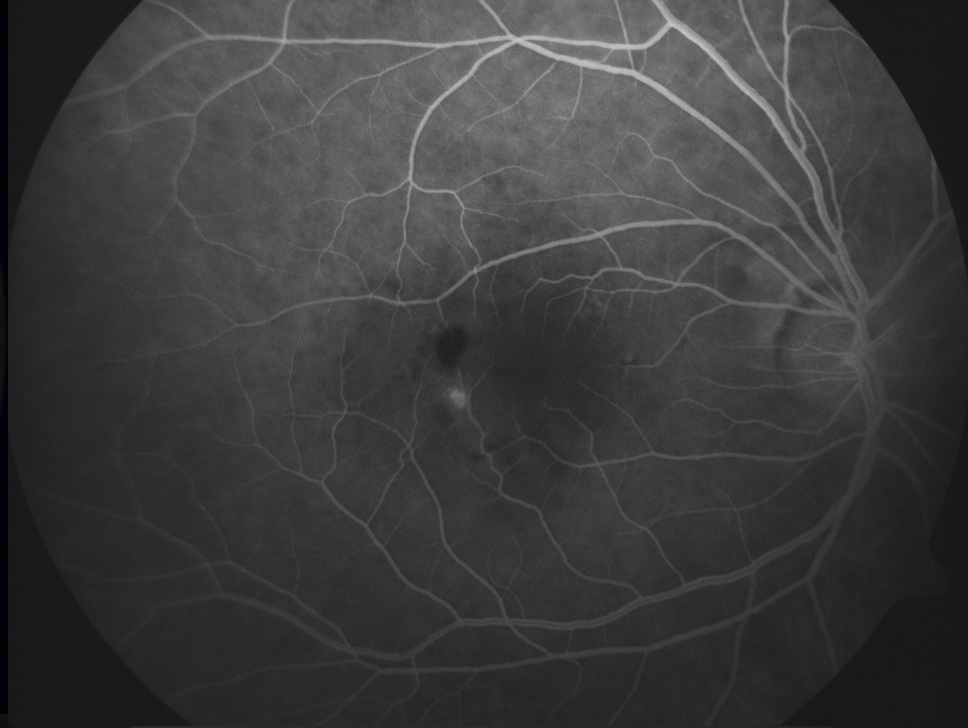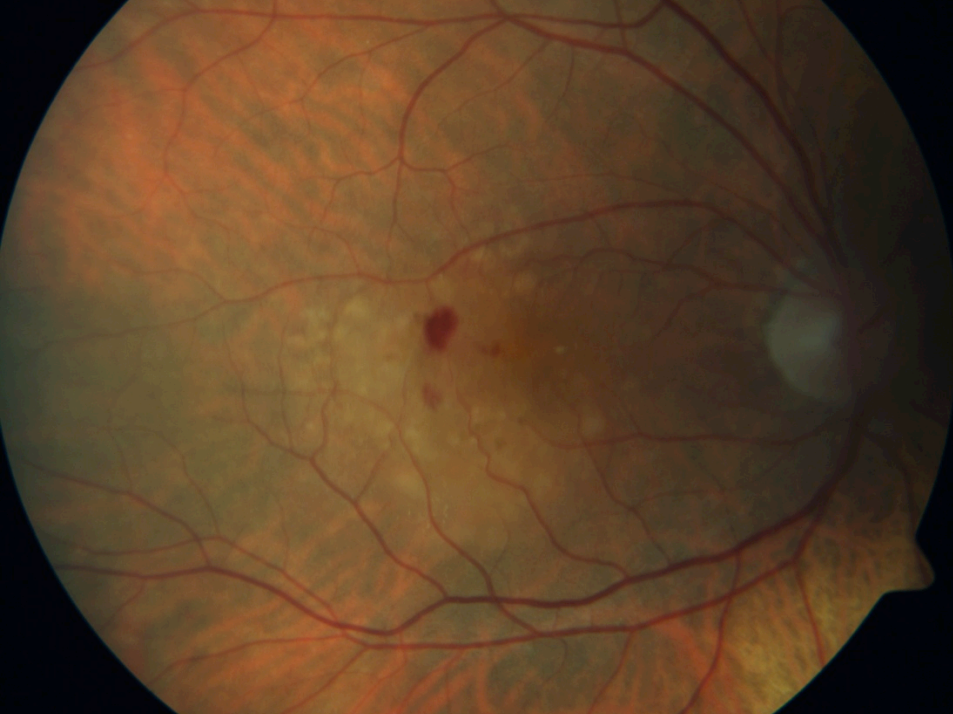Mulher Caucasiana, 82 anos

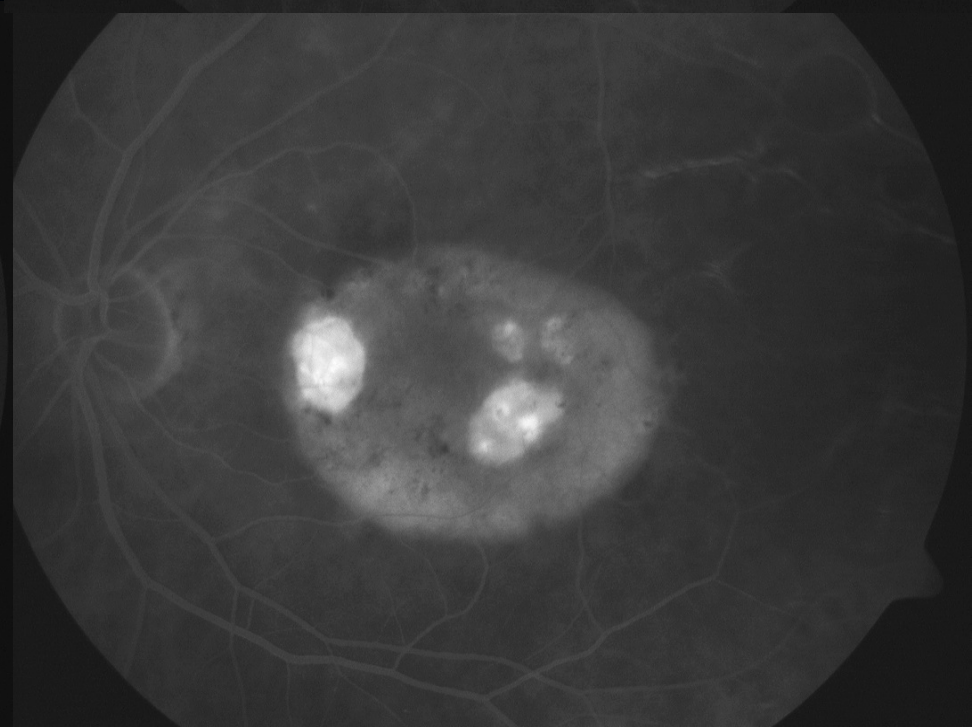
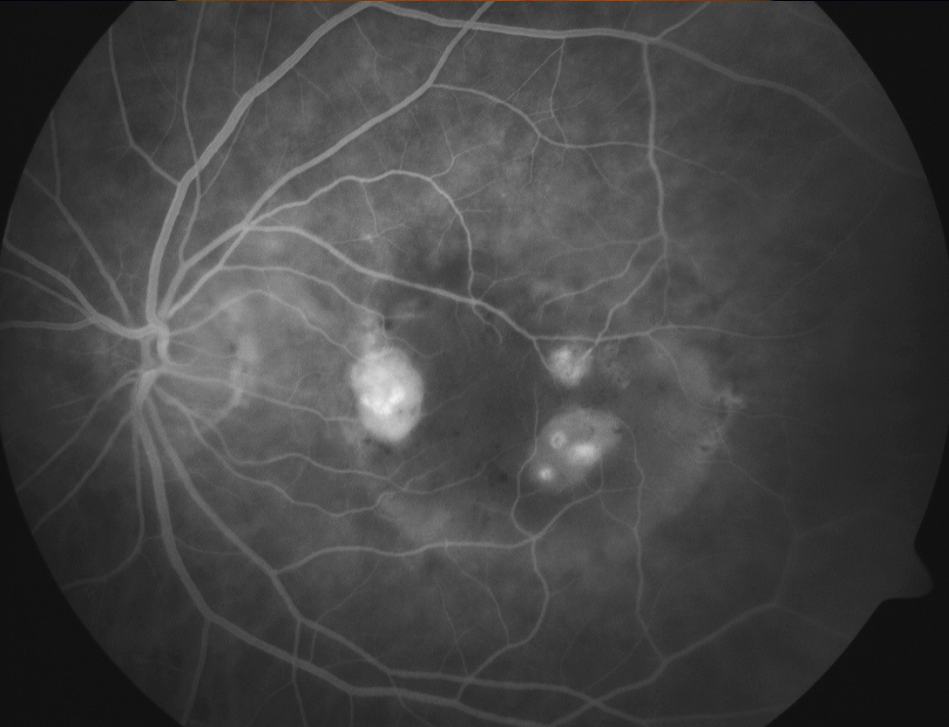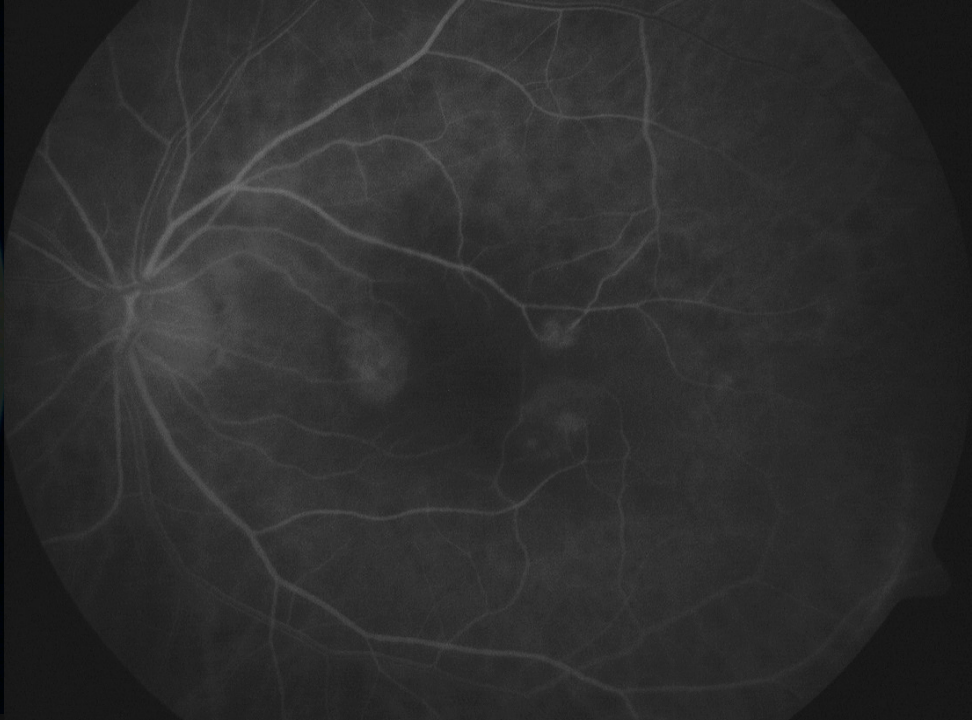
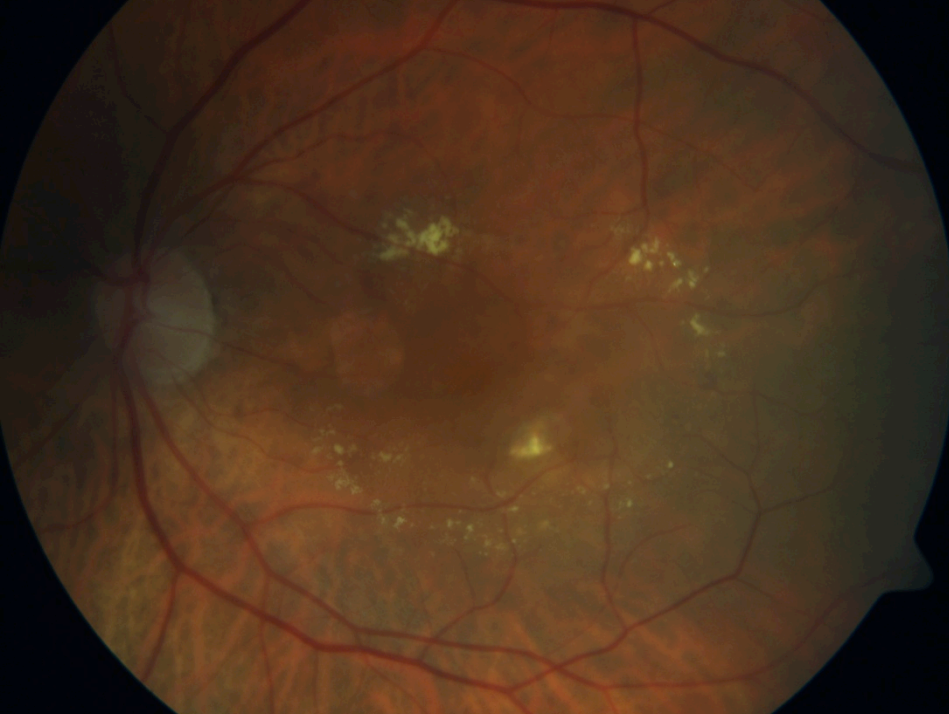diminuição gradual da AV ODE com meses de evolução





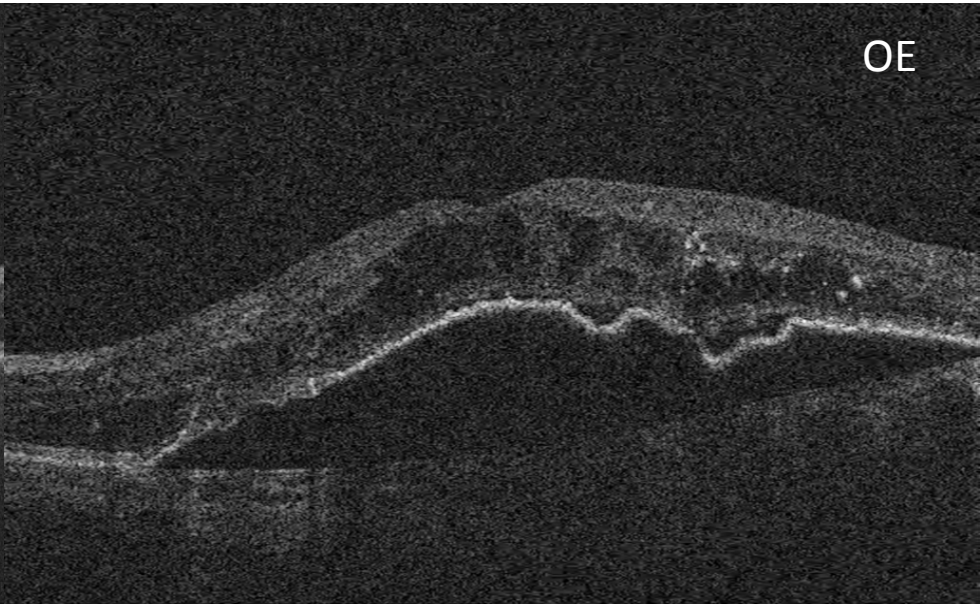
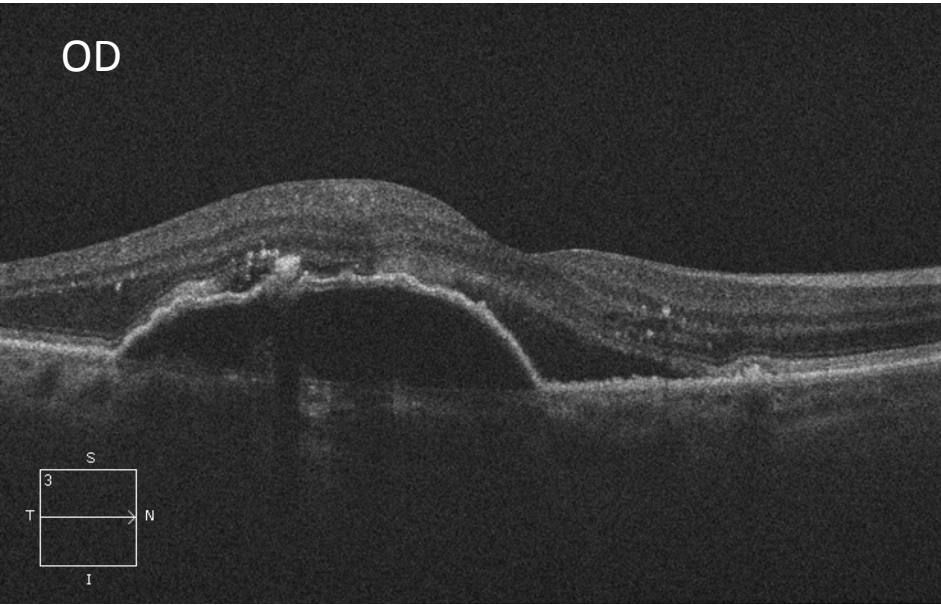


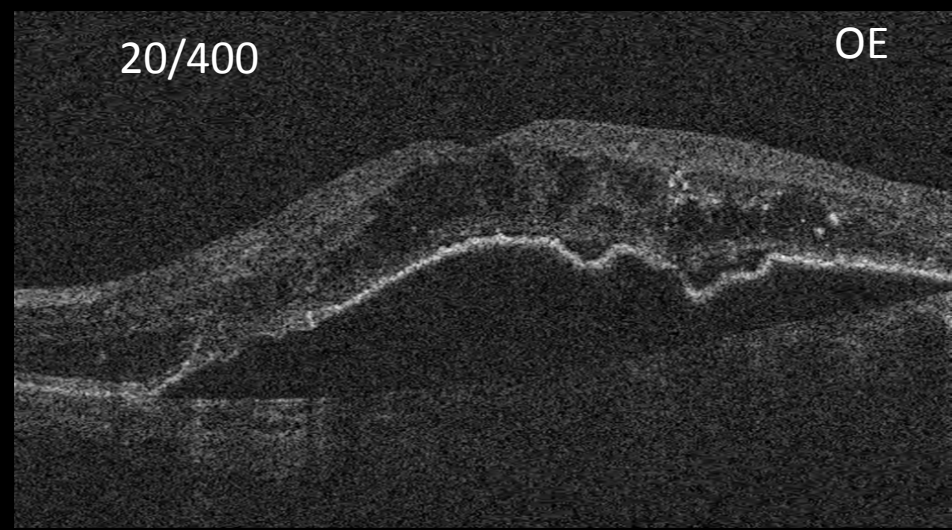
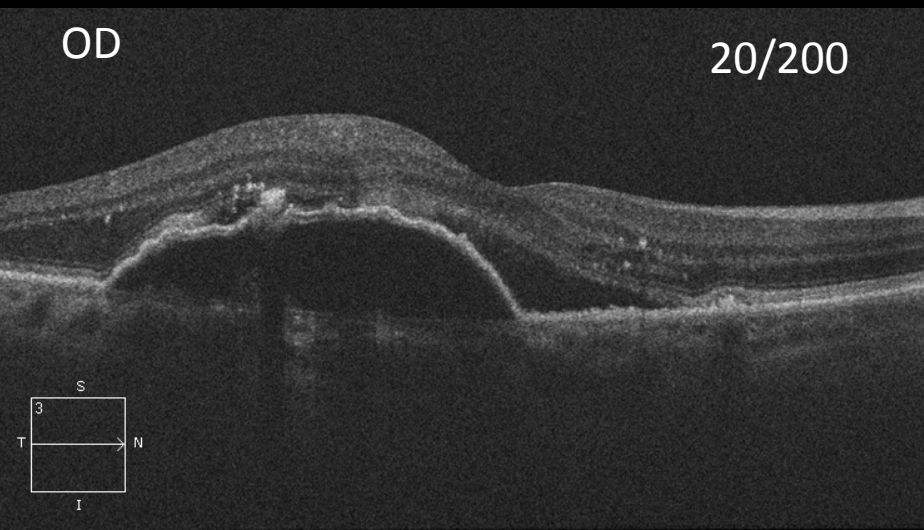






Mulher Caucasiana, 82 anos
diminuição gradual da AV ODE com meses de evolução

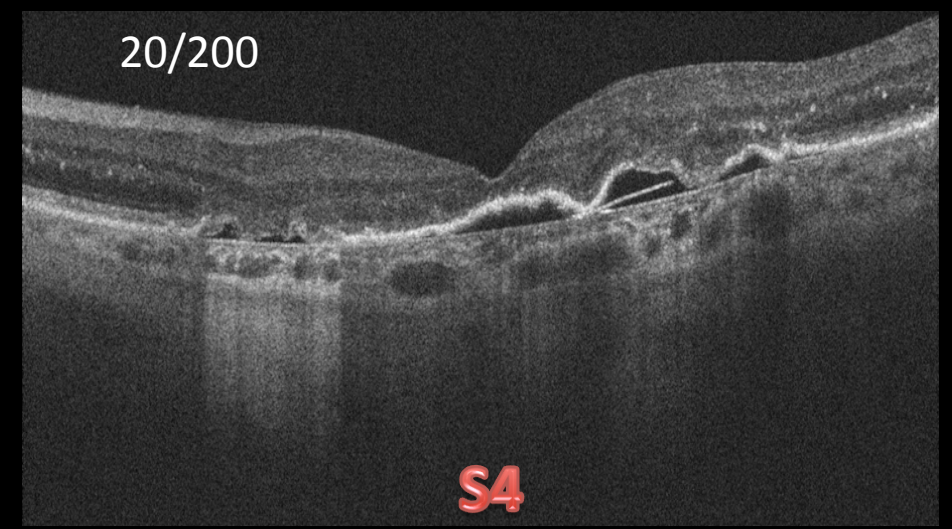
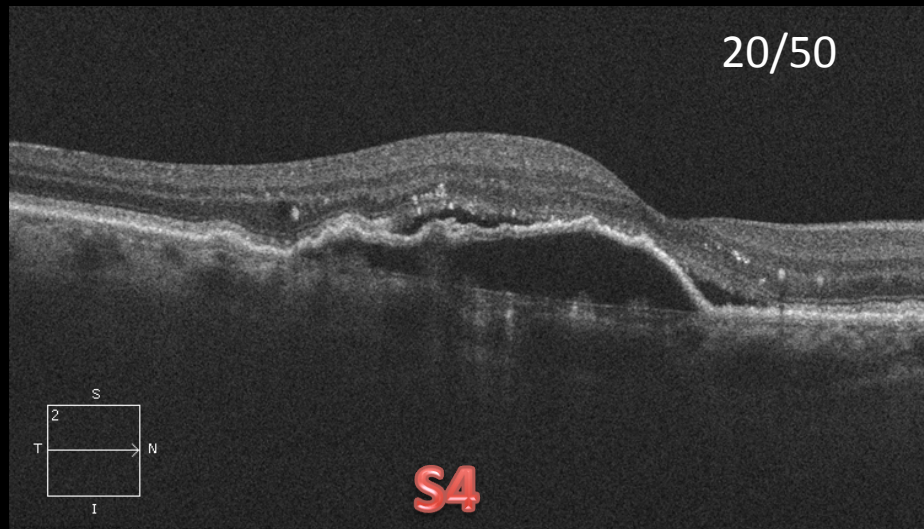


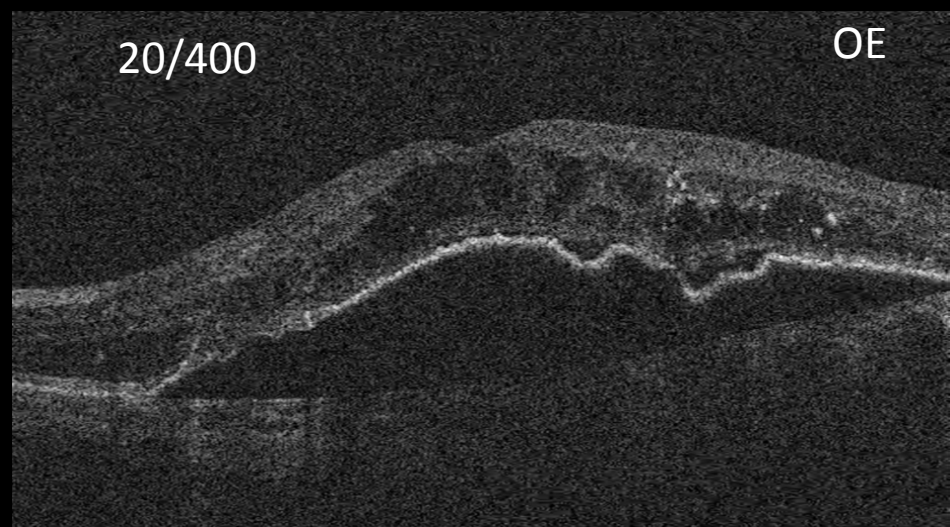
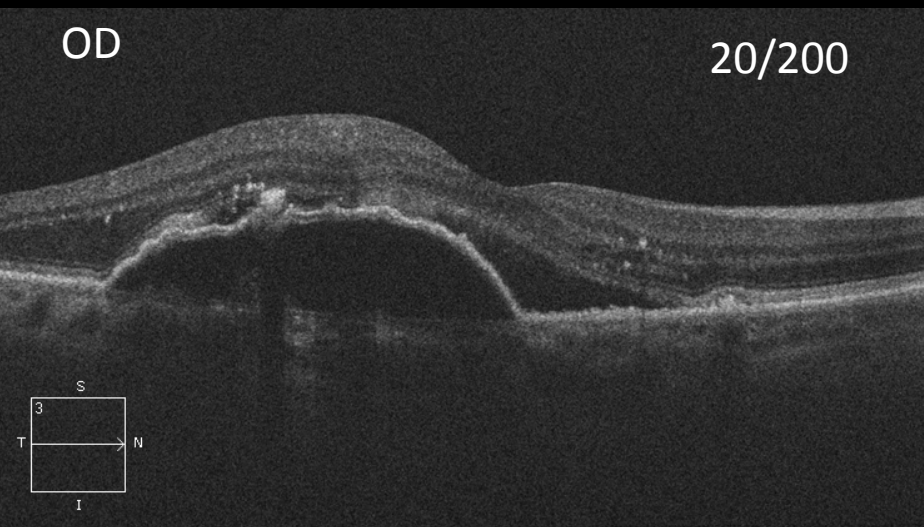

2.0 mg aflibercept



2.0 mg aflibercept

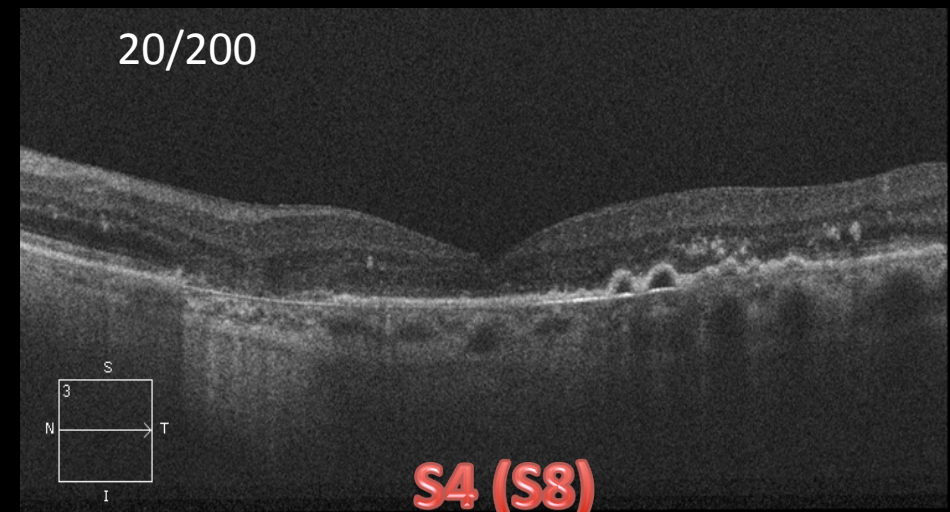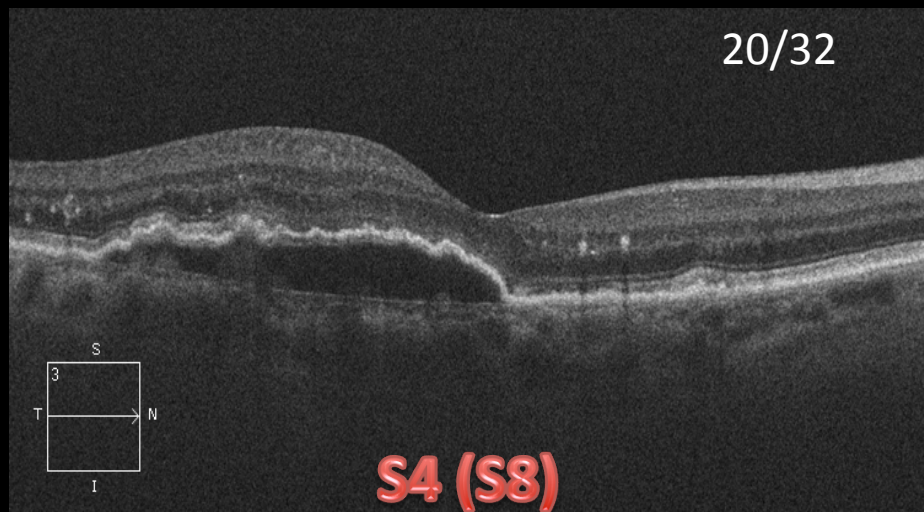


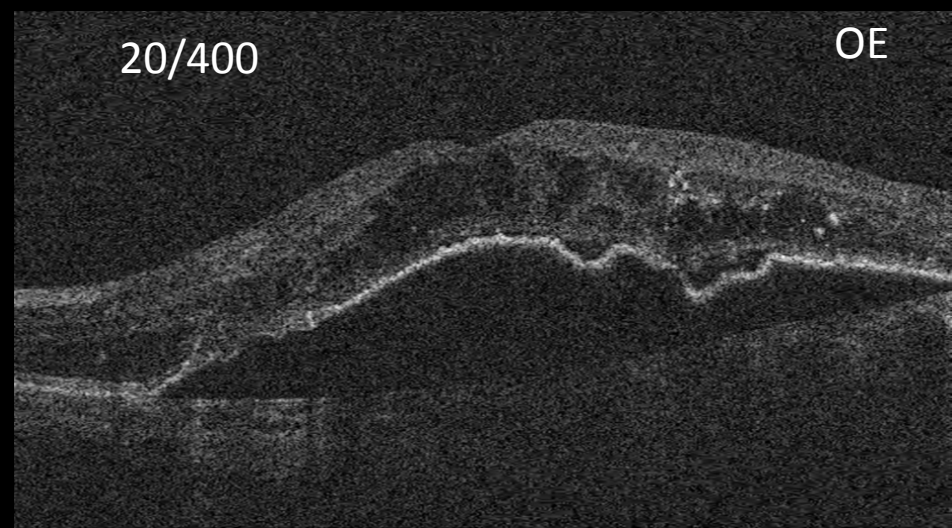
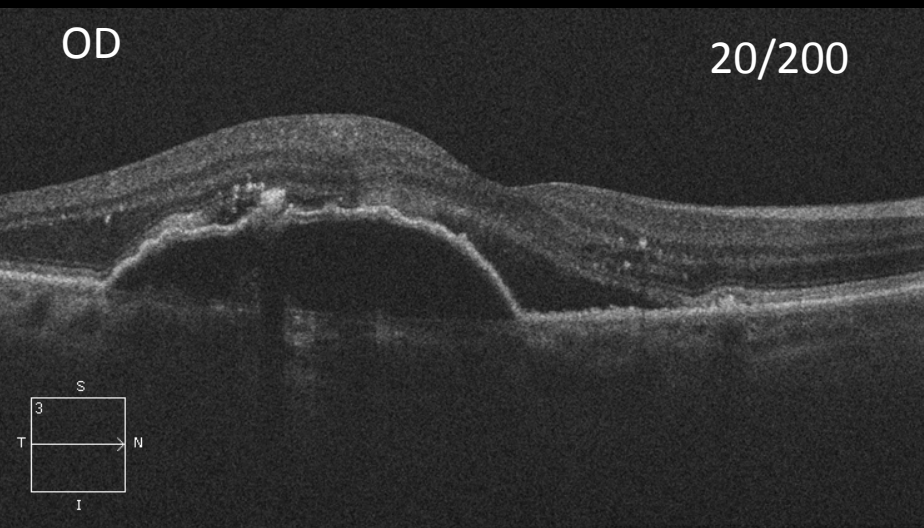


2.0 mg aflibercept #2



2.0 mg aflibercept #2





2.0 mg aflibercept #3

