

Dermatology Online Journal

Volume 16 Number 3

March 2010

[DOJ](#)

[Contents](#)

Two cases of annular elastolytic giant cell granuloma: Different response to the treatment

Filipa Ventura MD¹, Catarina Vilarinho MD¹, Maria da Luz Duarte MD¹, Fernando Pardal MD², Celeste Brito MD¹
Dermatology Online Journal 16 (3): 11

1. Dermatology and Venereology Department.
filipmanuelventura@hotmail.com
2. Pathology Department
Hospital de Braga, Braga, Portugal

Introduction

Annular elastolytic giant cell granuloma (AEGCG) is a rare granulomatous dermatosis of controversial origin characterized by loss of elastic fibers and elastophagocytosis by multinucleated giant cells [1]. Lesions of AEGCG are usually located on sun-exposed areas [2]. We present two patients with AEGCG both involving sun-exposed and covered areas.

Case reports

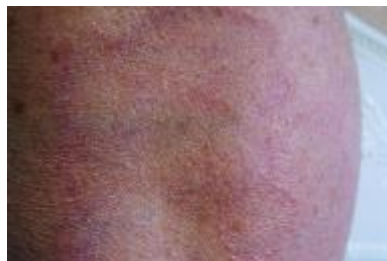

Figure 1

Figure 1. Annular red plaques localized on the lateral aspect of her right forearm (patient 1)

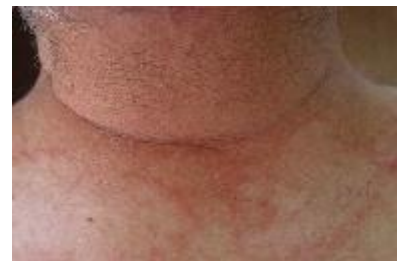

Figure 2

Figure 2. Annular red plaques localized on the upper back (patient 2)

A 66-year-old woman (patient 1) and a 70-year-old man (patient 2) presented with a slightly pruritic skin eruption evolving for 2 years and 3 months, respectively. They were not taking any medication. There was no family history of skin disorders. Physical examination revealed symmetric, erythematous papules and plaques, sometimes with annular configuration, with central atrophy and raised erythematous margins on the upper back, forearms, dorsal hands, and lower extremities (Figures 1 and 2). There was no mucous membrane or nail involvement. We performed a skin biopsy from the two patients. Histopathologic findings were almost identical. Both showed granulomatous infiltrates in the dermis consisting primarily of multinucleated giant cells, some of which contained fragments of elastic tissue (elastophagocytosis), and loss of elastic fibers in the center of the lesion (Figures 3 and 4). Laboratory tests including complete blood cell count, chemistry panel, antinuclear antibody, urinalysis, and chest x-ray were within normal limits.

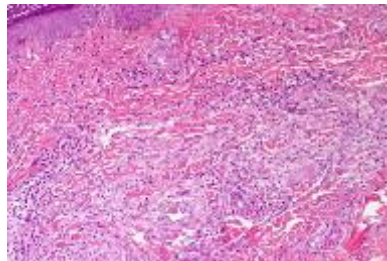


Figure 3

Figure 3. Granulomatous infiltrates in the dermis (H&E, x40)

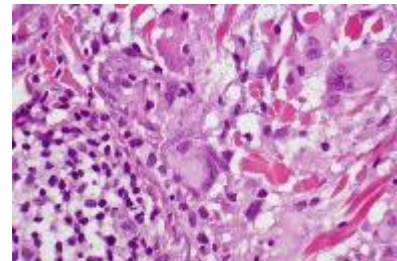


Figure 4

Figure 4. Phagocytosis of elastic fibers by multinucleated giant cells (H&E, x100)

The patient's response to the treatment was different. The female patient was treated with topical betamethasone dipropionate cream for 3 weeks with complete regression of the lesions. The male patient failed to respond to topical corticosteroids and PUVA therapy. Then, he was treated with hydroxychloroquine 400 mg/day over a period of 4 months with a good clinical result. However, the treatment had to be stopped because of early findings of retinopathy. Treatment with cyclosporine 200 mg/day was started with a complete response after 7 months. Eighteen months after discontinuance of the treatment there is no clinical recurrence of the lesions.

Discussion

In 1975 O'Brien described a new type of annular skin lesion with elastolysis and elastophagocytosis, localized on light-exposed body areas and titled this entity *actinic granuloma* [2, 3]. The term AEGCG was proposed by Hanke et al. in 1979 and includes the lesions previously called actinic granuloma, atypical necrobiosis lipoidica, and Miescher's granuloma [2, 3, 4]. They defend the observation that solar elastosis is not always present; although less common, the lesions could be present in covered areas.

Annular elastolytic giant cell granuloma is an uncommon disease that predominantly affects older adults, with no sex predilection [2]. Clinically, red papules and hypochromic or atrophic plaques with elevated borders and central depression are typically located on sun-exposed skin. There have been reports of lesions located on sun-protected sites [5], as in our case. There have also been generalized forms reported with red asymptomatic papules [6].

The histopathologic features are best demonstrated by a biopsy of the elevated edge of the plaque [7]. They are characterized by granulomatous infiltrates with multinucleated giant cells in the upper and mid dermis, loss and fragmentation of elastic fibers, and elastophagocytosis by giant cells, without necrobiosis and mucin deposition [2, 7, 8]. These features help to distinguish AEGCG from granuloma annulare and necrobiosis lipoidica, which are the main disorders in the histological differential diagnosis [7]. It is speculated that solar radiation, heat or other unknown factors transform the antigenicity of the elastic fibers and induce the cellular immunological reaction [1, 2, 9]. Immunohistochemical studies showing that CD4+ cells predominated over CD8+ cells in the inflammatory infiltrate also support this theory [1, 2]. It has been also proposed that diabetes mellitus could be implicated in the etiology by producing structural damage of the elastic tissue [2]. There have been reported cases of AEGCG associated with systemic sarcoidosis, cutaneous amyloidosis, molluscum contagiosum, squamous cell carcinoma of the lung and cutaneous T-cell lymphoma [2].

The treatment for AEGCG remains a challenge. Variable results have been reported with therapies such as topical or intralesional steroids, cryotherapy, clofazimine, antimalarials (chloroquine and hydroxychloroquine), dapsone, PUVA, and cyclosporine [1, 9]. Some cases resolve spontaneously [8, 9]. Although our patients were similar clinically, they responded very differently to therapy.

References

1. Lee H-W, Lee M-W, Choi J-H, Moon K-C, Koh J-K. Annular elastolytic giant cell granuloma in an infant: improvement after

treatment with oral tranilast and topical pimecrolimus. *J Am Acad Dermatol.* 2005;53:S244-246. [[PubMed](#)]

2. Doulaveri G, Tsagrioni E, Giannadaki M, Bosemberg E, Limas C, Potouridou I, Zakopoulou N. Annular elastolytic giant cell granuloma in a 70-year-old woman. *Int J Dermatol.* 2003;42:290-291. [[PubMed](#)]

3. Pock L, Blazková J, Caloudová H, Varjassyová I, Konkolová R, Hercogová J. Annular elastolytic giant cell granuloma causes na irreversible disappearance of the elastic fibres. *J Eur Acad Dermatol Venereol.* 2004;18: 365-368. [[PubMed](#)]

4. Campos-Muñoz L, Díaz-Díaz RM, Quesada-Cortés A, Hernández-Cano N, Martín-Díaz MA, Regojo-Zapata RM, Casado-Jiménez M. Annular elastolytic giant cell granuloma: a case report located in non-sun exposed areas. *Actas Dermosifilogr.* 2006;97(8):533-535. [[PubMed](#)]

5. Maramatsu T, Shirai T, Yamashina Y. AEGCG: an unusual case with lesions arising in non sun-exposed areas. *J Dermatol.* 1987;14:54-58. [[PubMed](#)]

6. Sina B, Wood C, Rudo K. Generalized elastophagocytic granuloma. *Cutis.* 1992;49(5):355-357. [[PubMed](#)]

7. Meadows KP, O'Reilly MA, Harris RM, Petersen MJ. Erythematous annular plaques in a necklace distribution. *Arch Dermatol.* 2001;137:1647-1652. [[PubMed](#)]

8. Misago N, Ohtsuka Y, Ishii K, Narisawa Y. Papular and reticular elastolytic giant cell granuloma: rapid spontaneous regression. *Acta Derm Venereol.* 2007;87(1);89-90. [[PubMed](#)]

9. Kelly BJ, Mrstik ME, Ramos-Caro FA, Iczkowski KA. Papular elastolytic giant cell granuloma responding to hydroxychloroquine and quinacrine. *Int J Dermatol.* 2004;43:964-966. [[PubMed](#)]