



**Hospital**  
Braga

# **REUNIÃO** **INTERDEPARTAMENTAL**

**Hospital de Braga**

Margarida Ferreira

15.01.2014

# HISTÓRIA CLÍNICA



## • Identificação:

- ✓ M. G. M.
- ✓ Sexo masculino;
- ✓ 67 anos.

## • História da Doença Atual:

- ✓ Défice visual esquerdo “*de novo*” em doente com história de craniotomia fronto-temporal direita por macroadenoma (prolactinoma, não secretor) em janeiro de 1996, com RT adjuvante.
- ✓ Amaurose direita sequelar.

# HISTÓRIA CLÍNICA



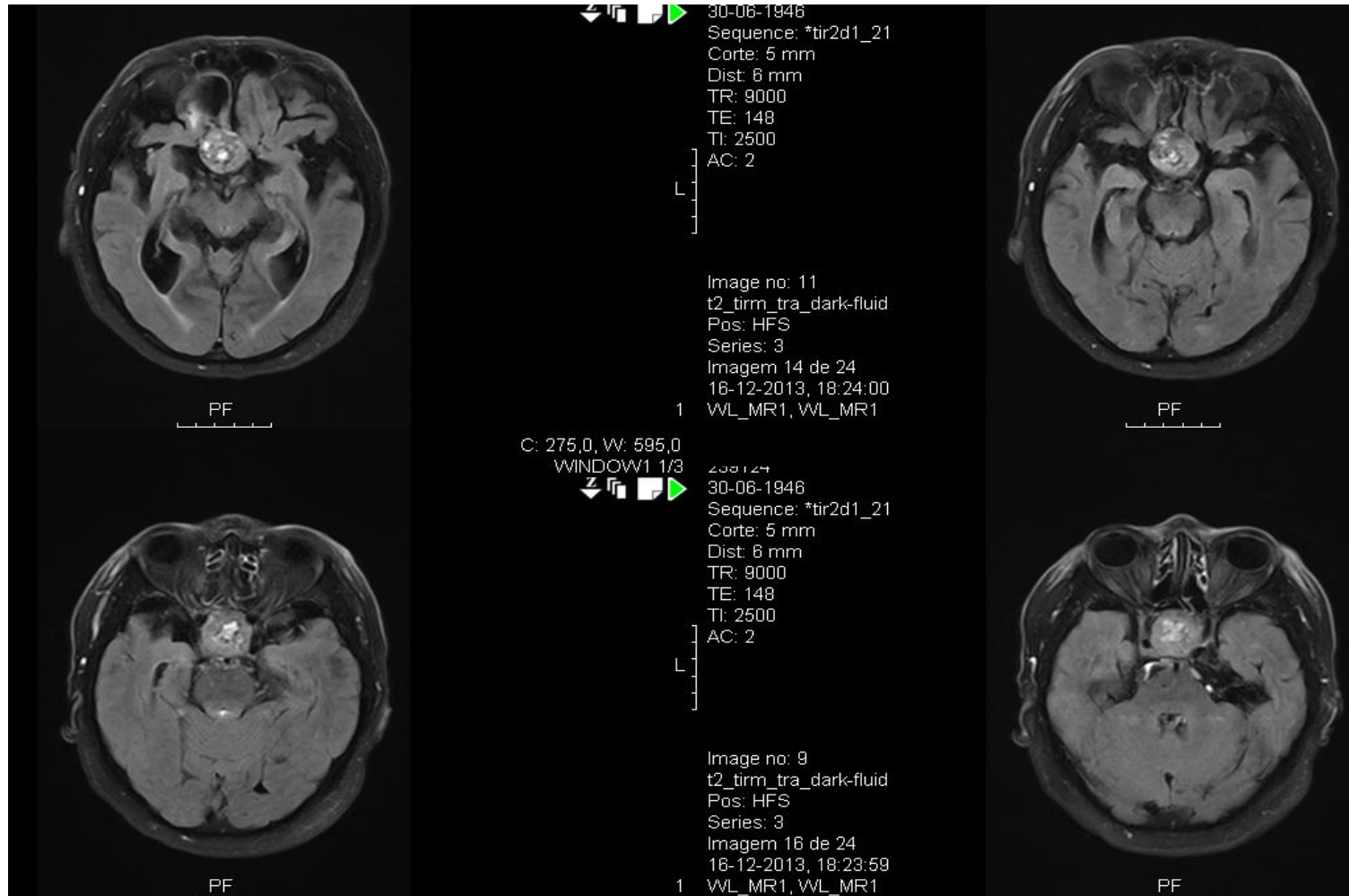
- **Exames complementares de diagnóstico:**

- **RM:**

✓ “(...) observa-se aumento do volume do macroadenoma hipofisário, com áreas de hemorragia recente; mede atualmente 26x42mm(...) inferiormente afunda o pavimento selar, tem expressão retro-selar e anteriormente ocupa quase todo o seio esfenoidal(...) O compartimento supra-selar deforma o quiasma ótico(...) verificando-se também marcada deformação do nervo ótico direito. O adenoma hipofisário é atualmente heterogéneo(...) devido ao componente hemático(...).

# HISTÓRIA CLÍNICA

- Exames complementares de diagnóstico:



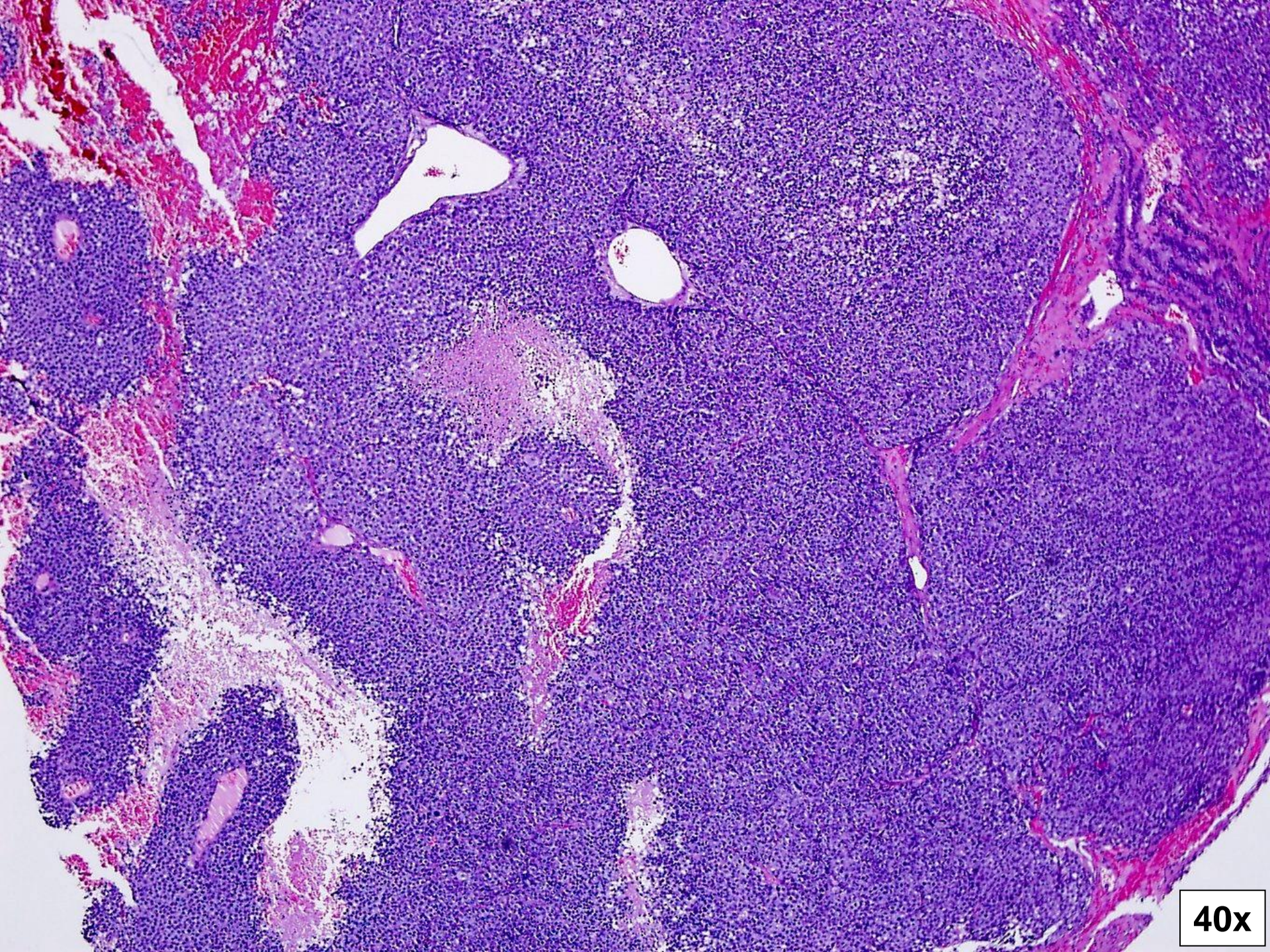
# HISTÓRIA CLÍNICA



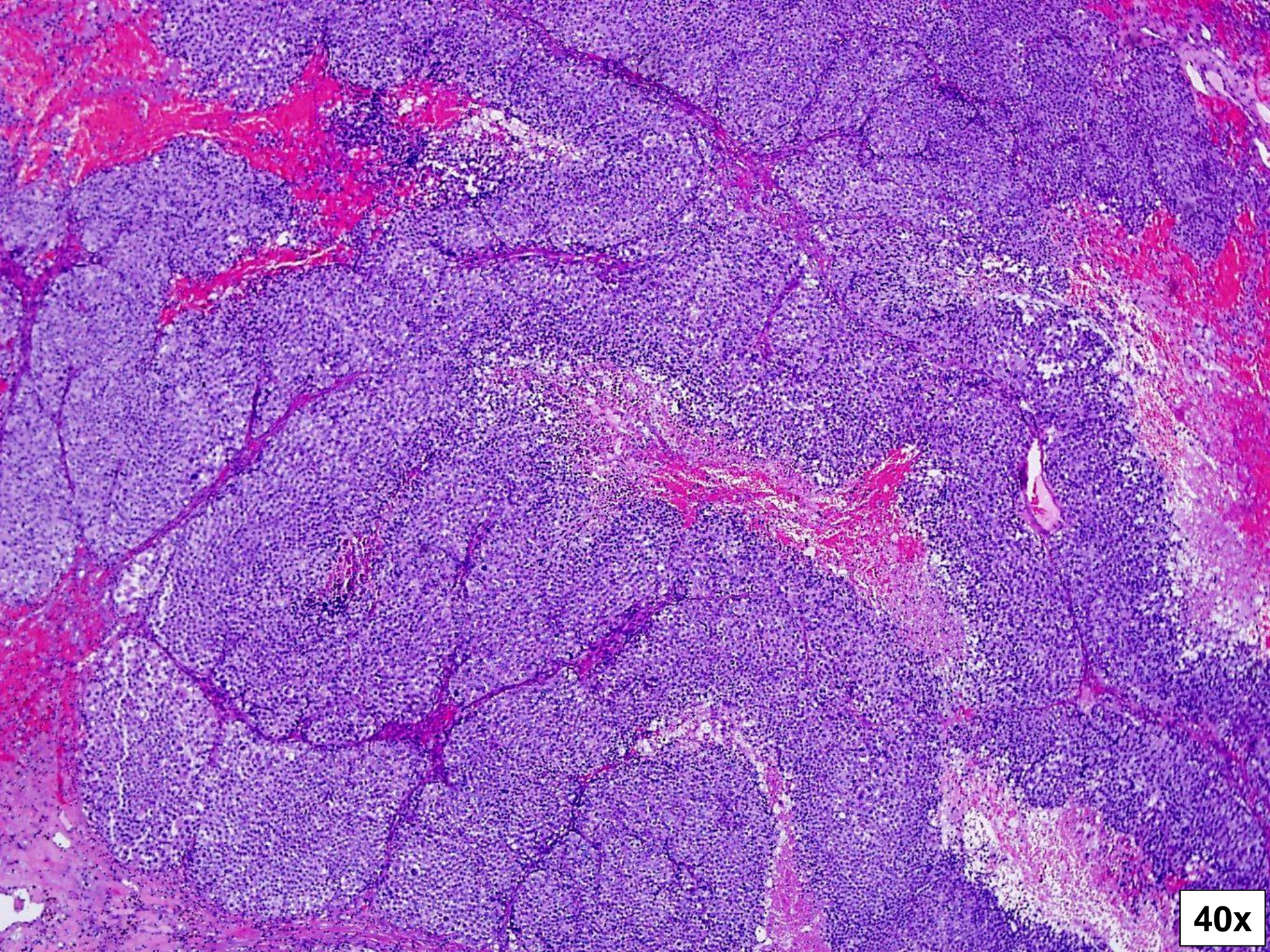
- Por suspeita de apoplexia pituitária, o doente é submetido a cirurgia transesfenoidal.

# MACROSCOPIA

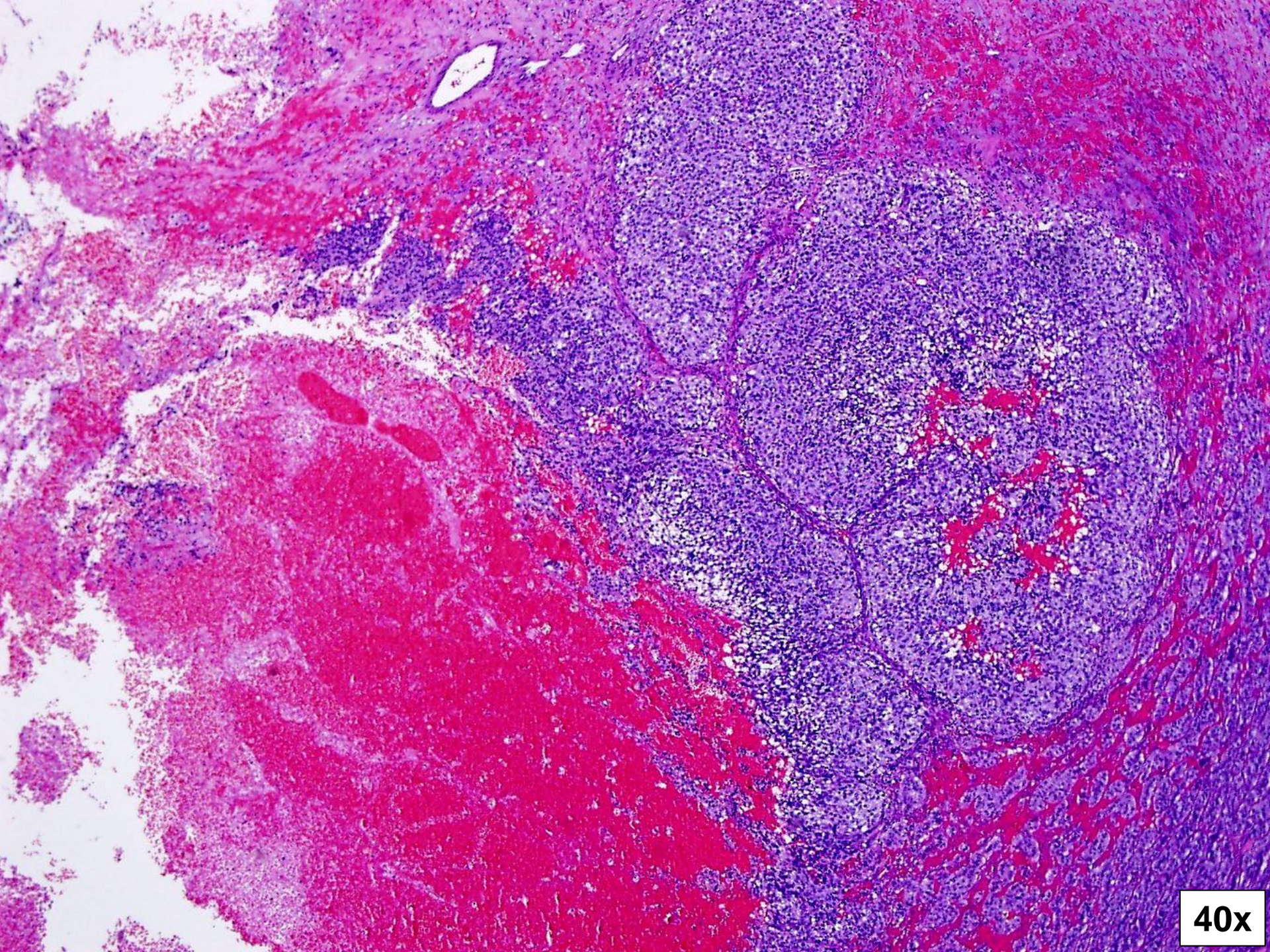
- Produto de 2 gr constituído por retalhos irregulares de tecido acastanhado.
  
- **Natureza da peça/Informação clínica:**
  - macroadenoma hipofisário recidivado e com apoplexia;
  - tumor com áreas consistentes e outras necróticas e hemorrágicas.



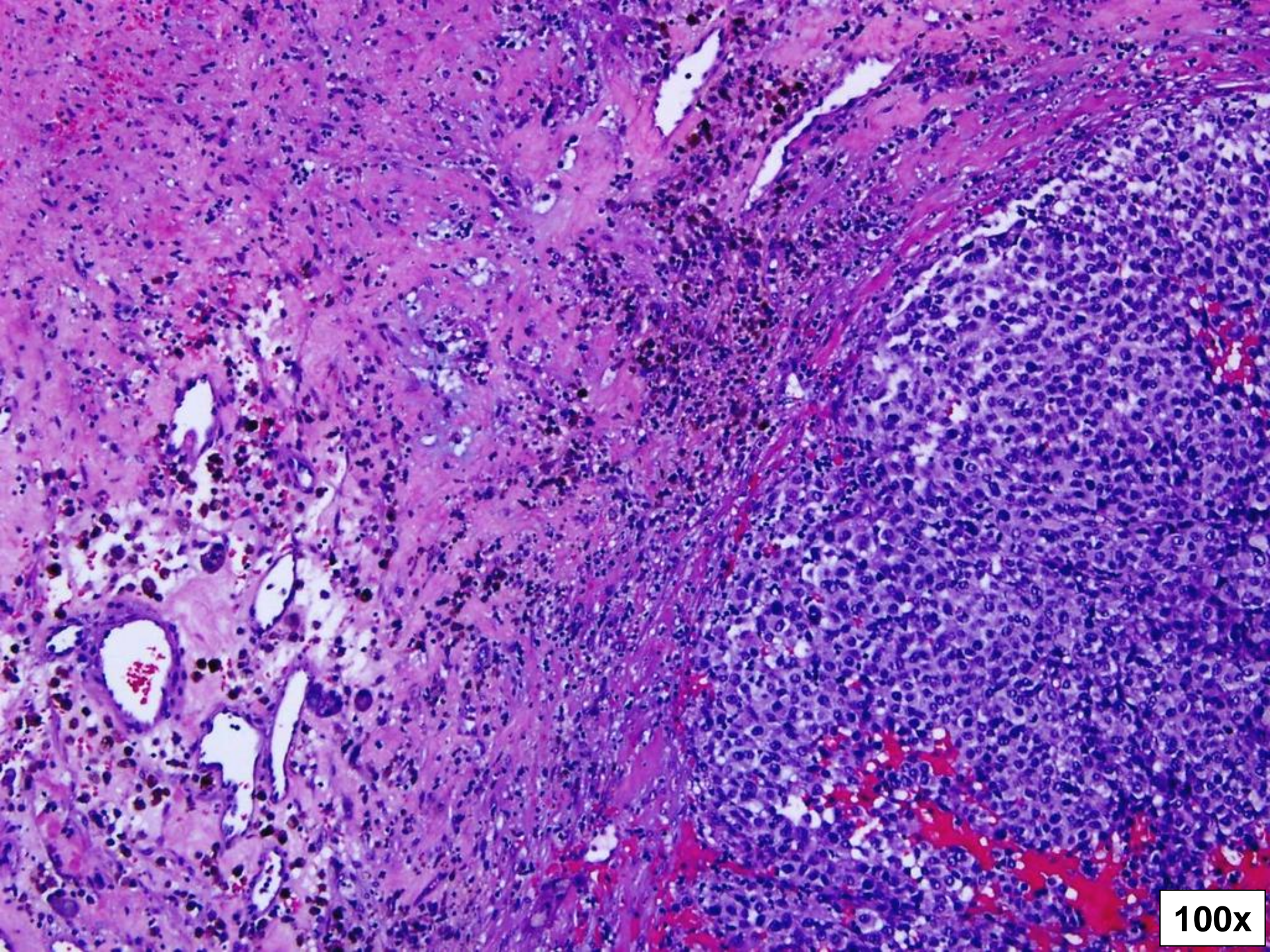
40x



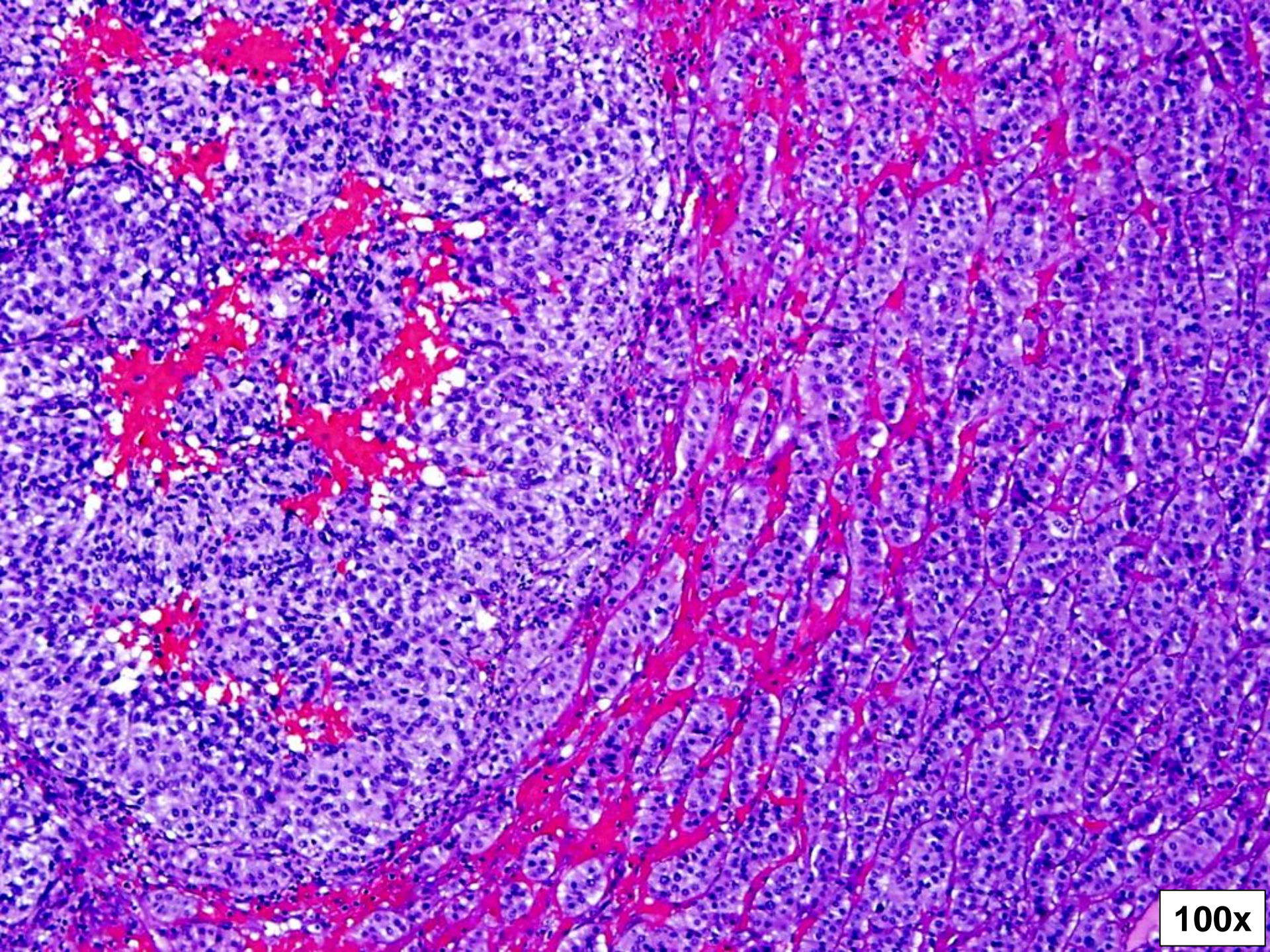
40x



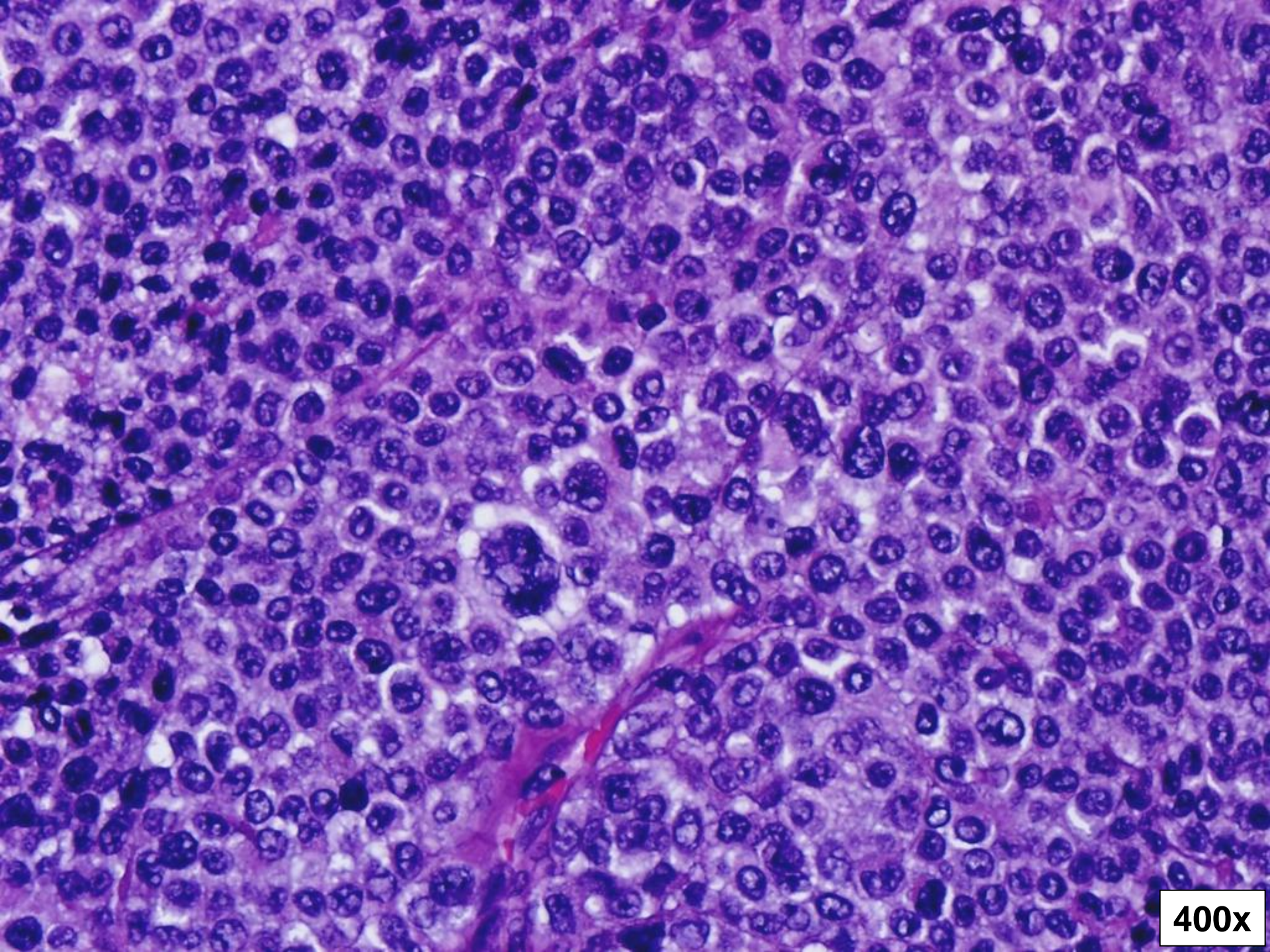
40x



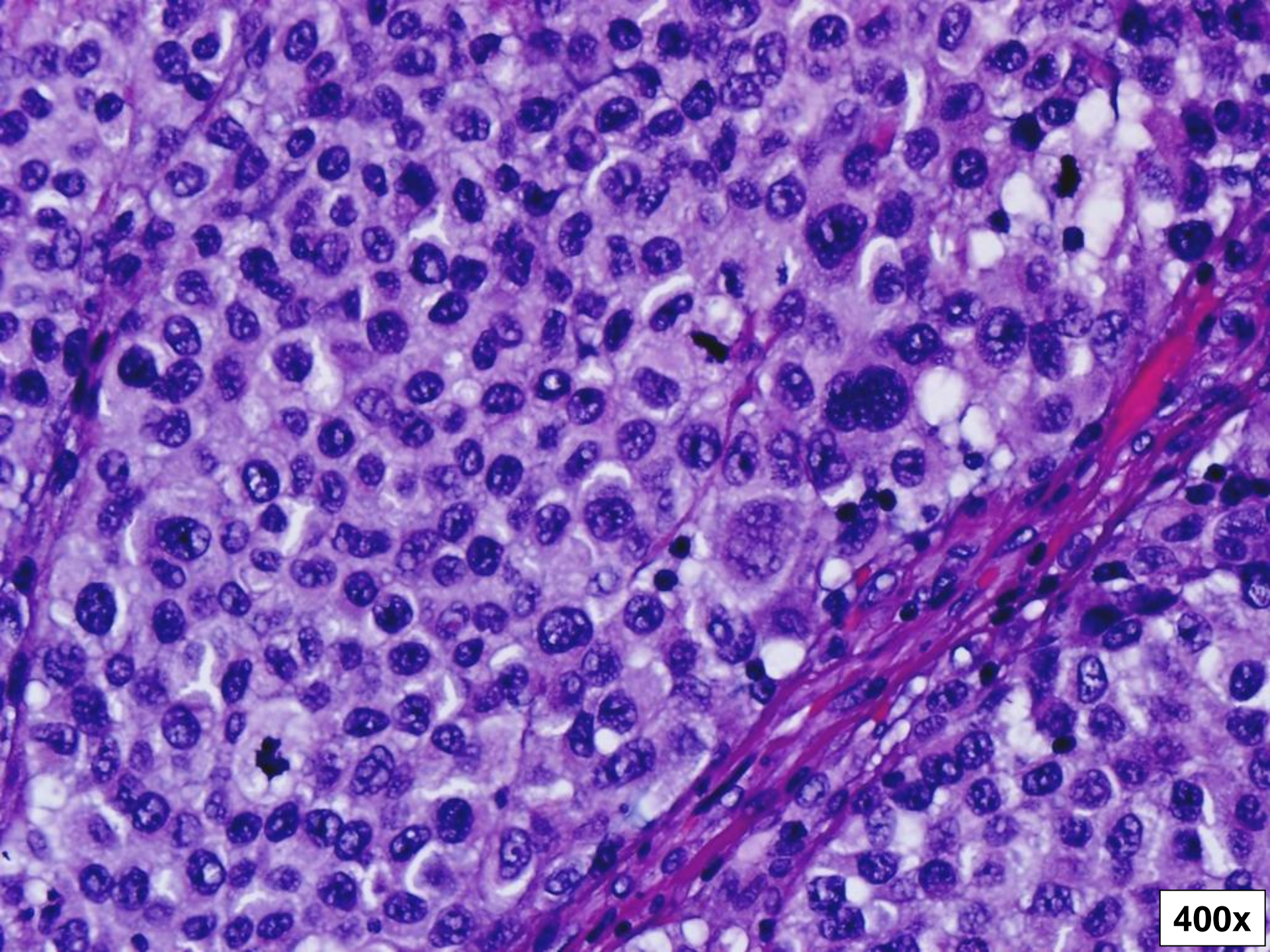
100x



100x



400x



400x



Hospital  
Braga

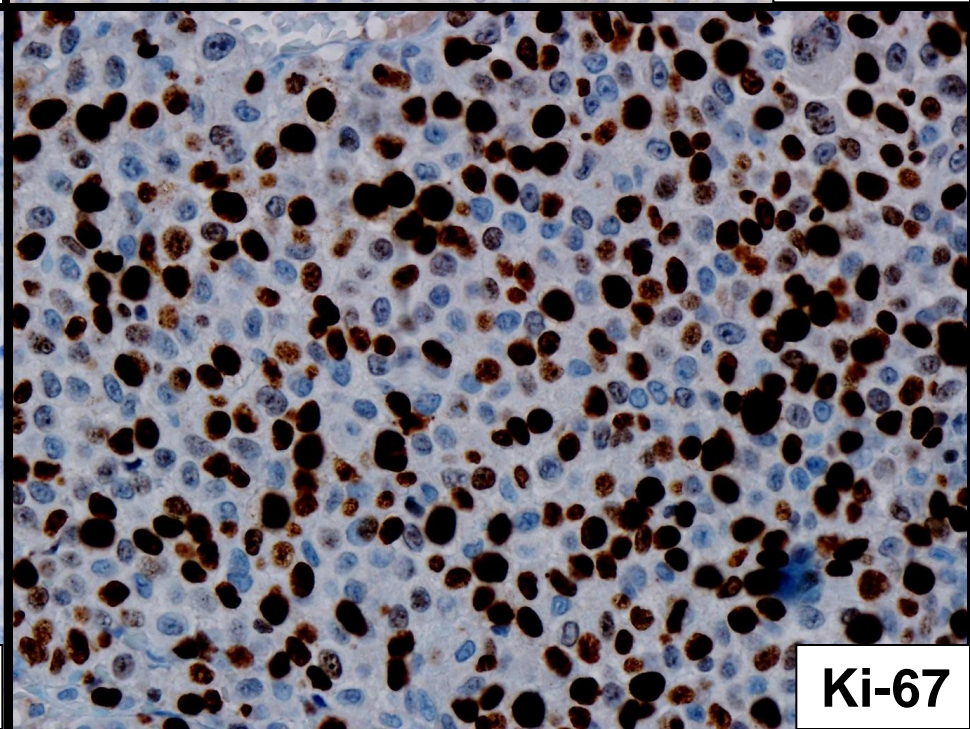
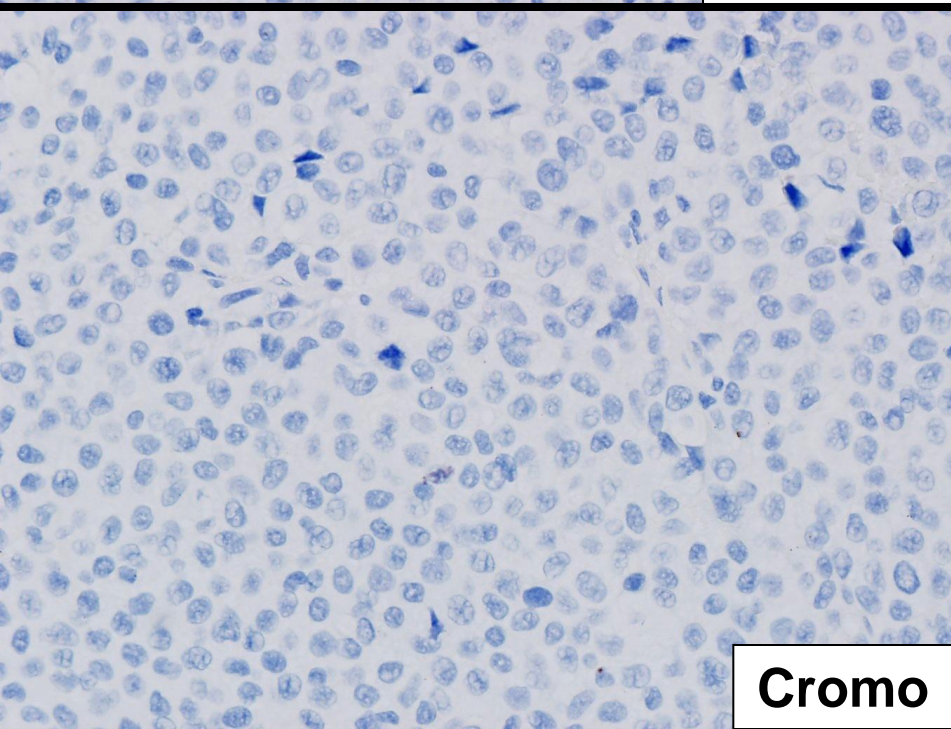
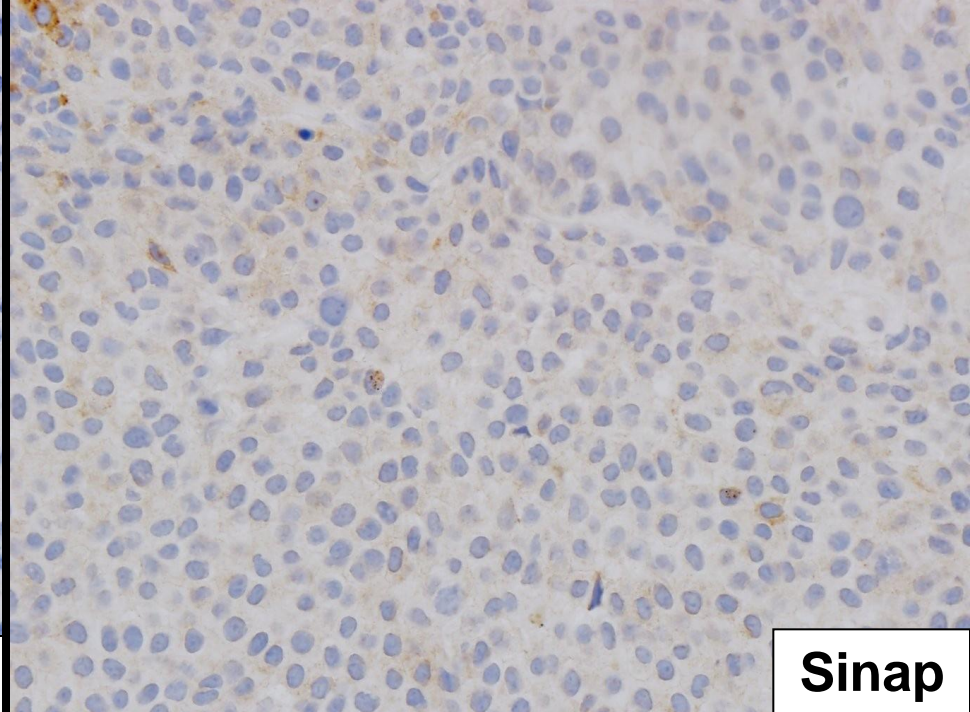
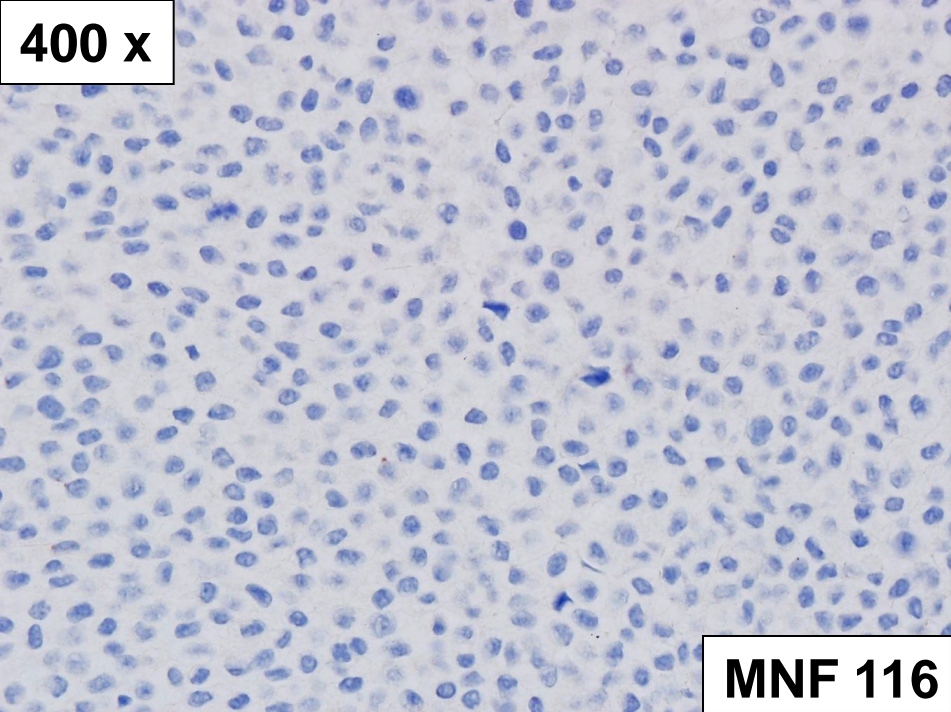


# HIPÓTESES DE DIAGNÓSTICO

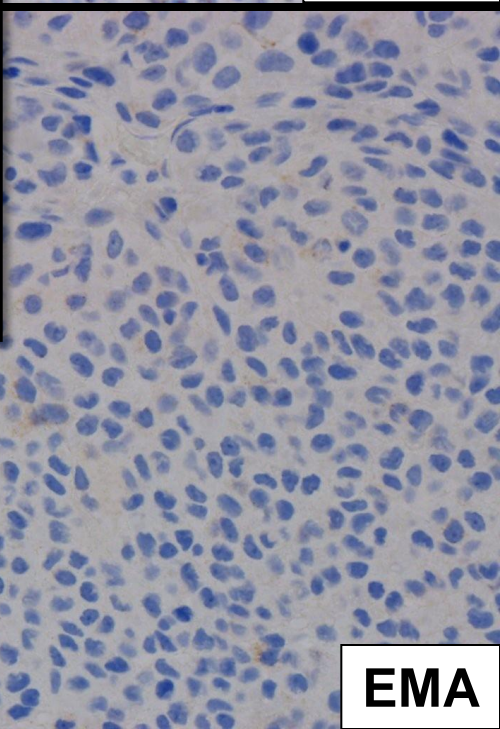
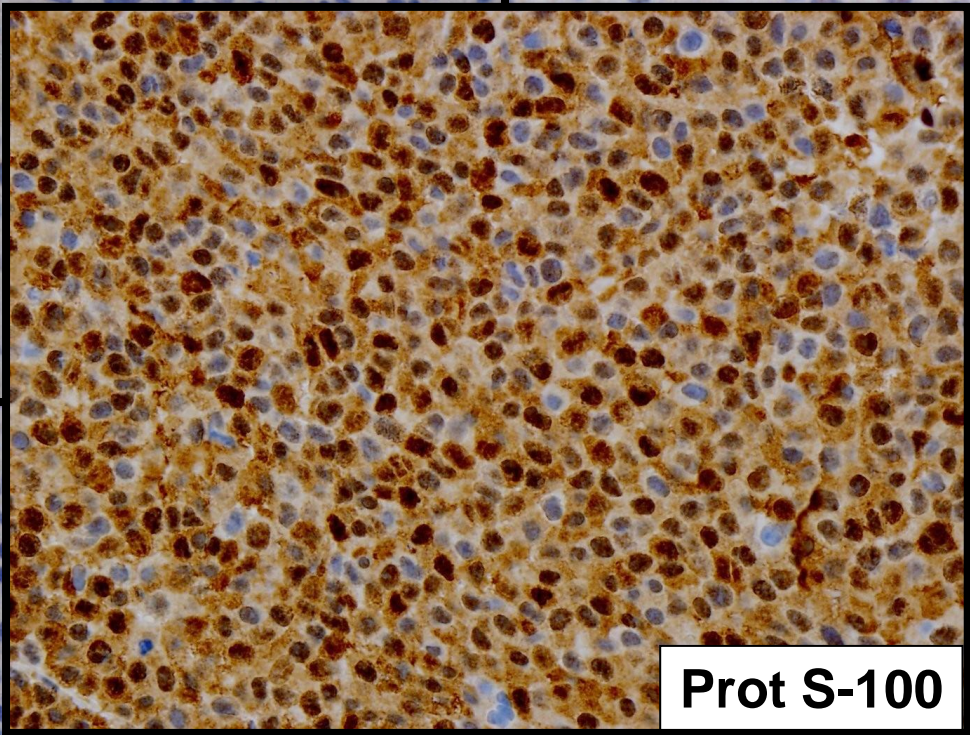
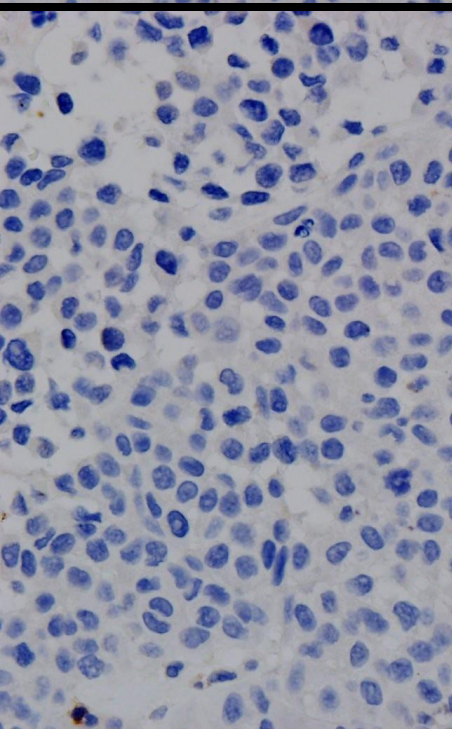
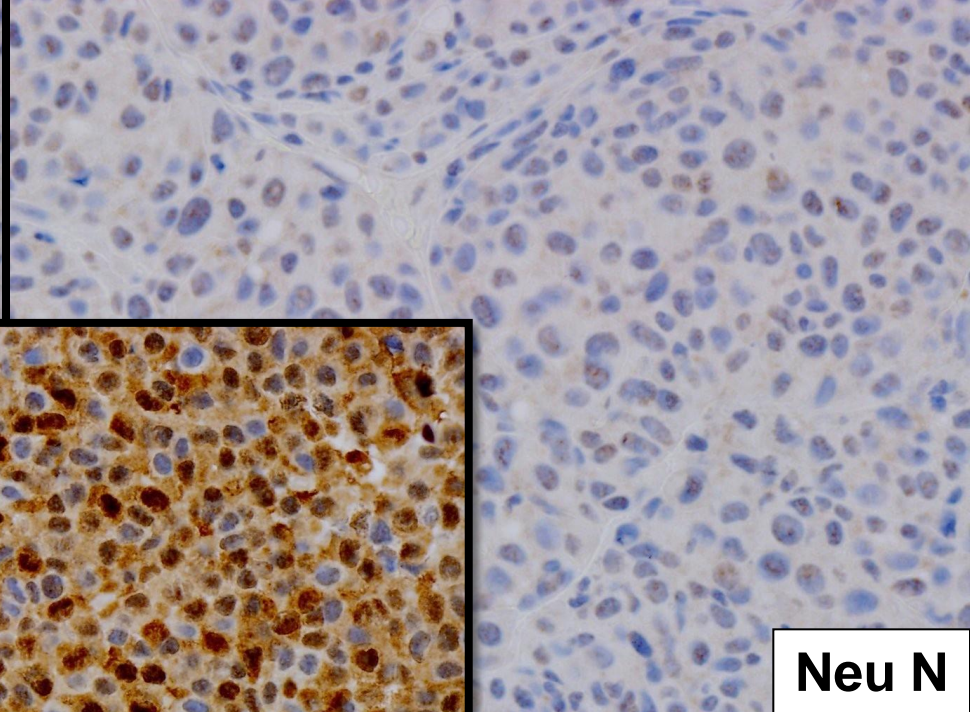
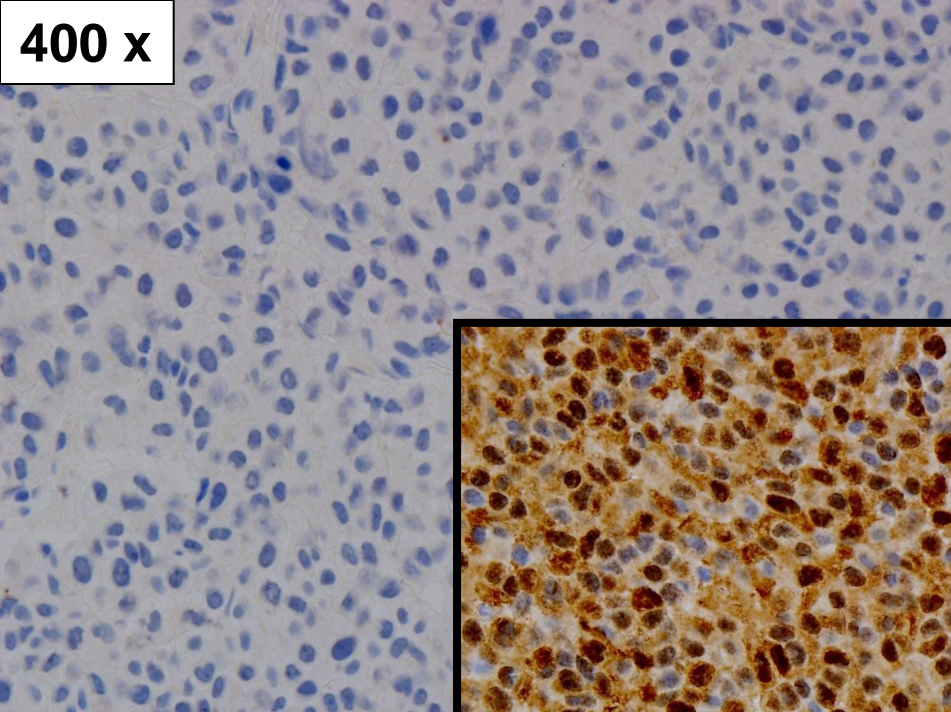
✓ Adenoma atípico da hipófise

... muito atípico!!!!

**400 x**



400 x



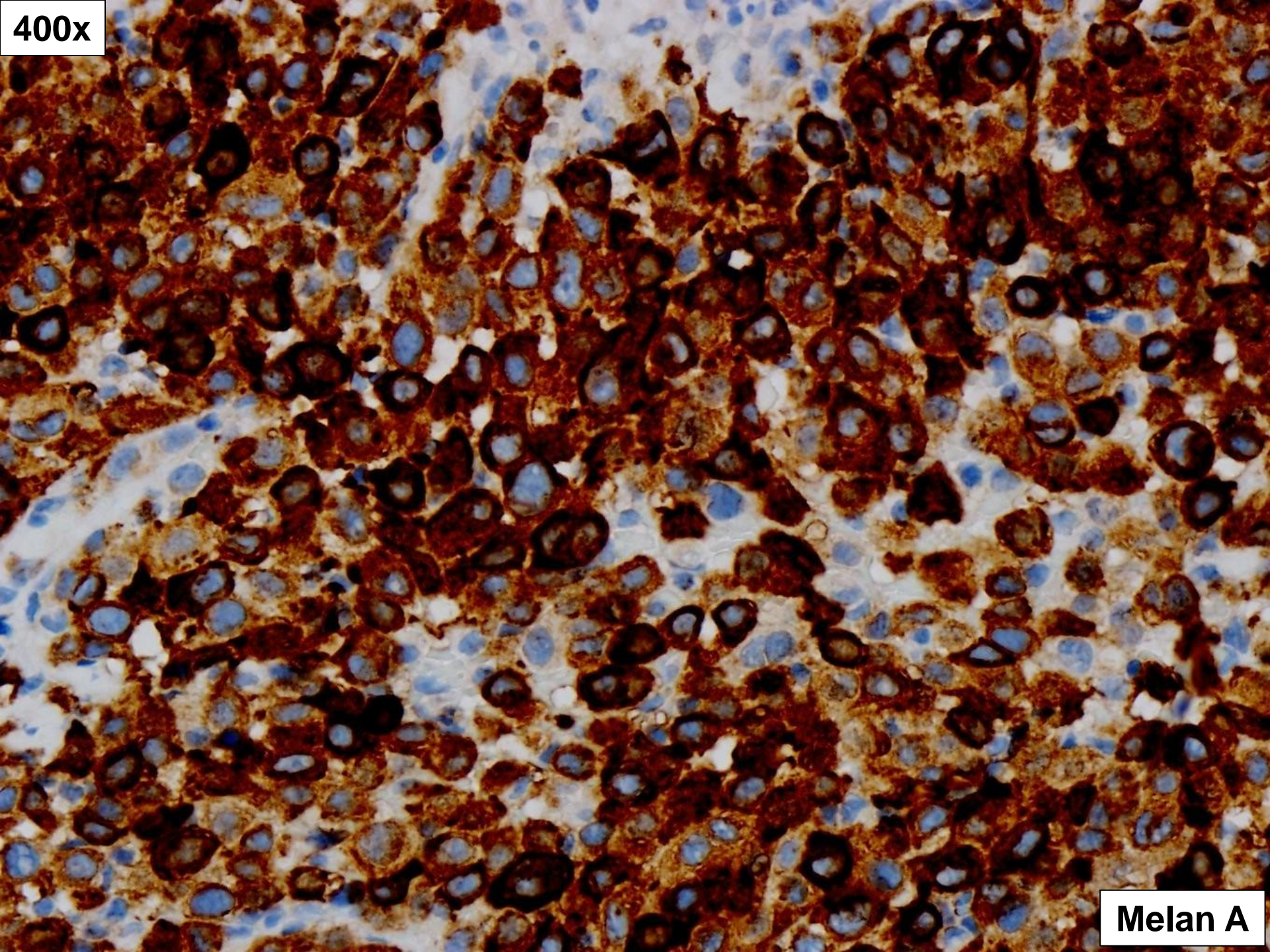
Neu N

Prot S-100

LCA

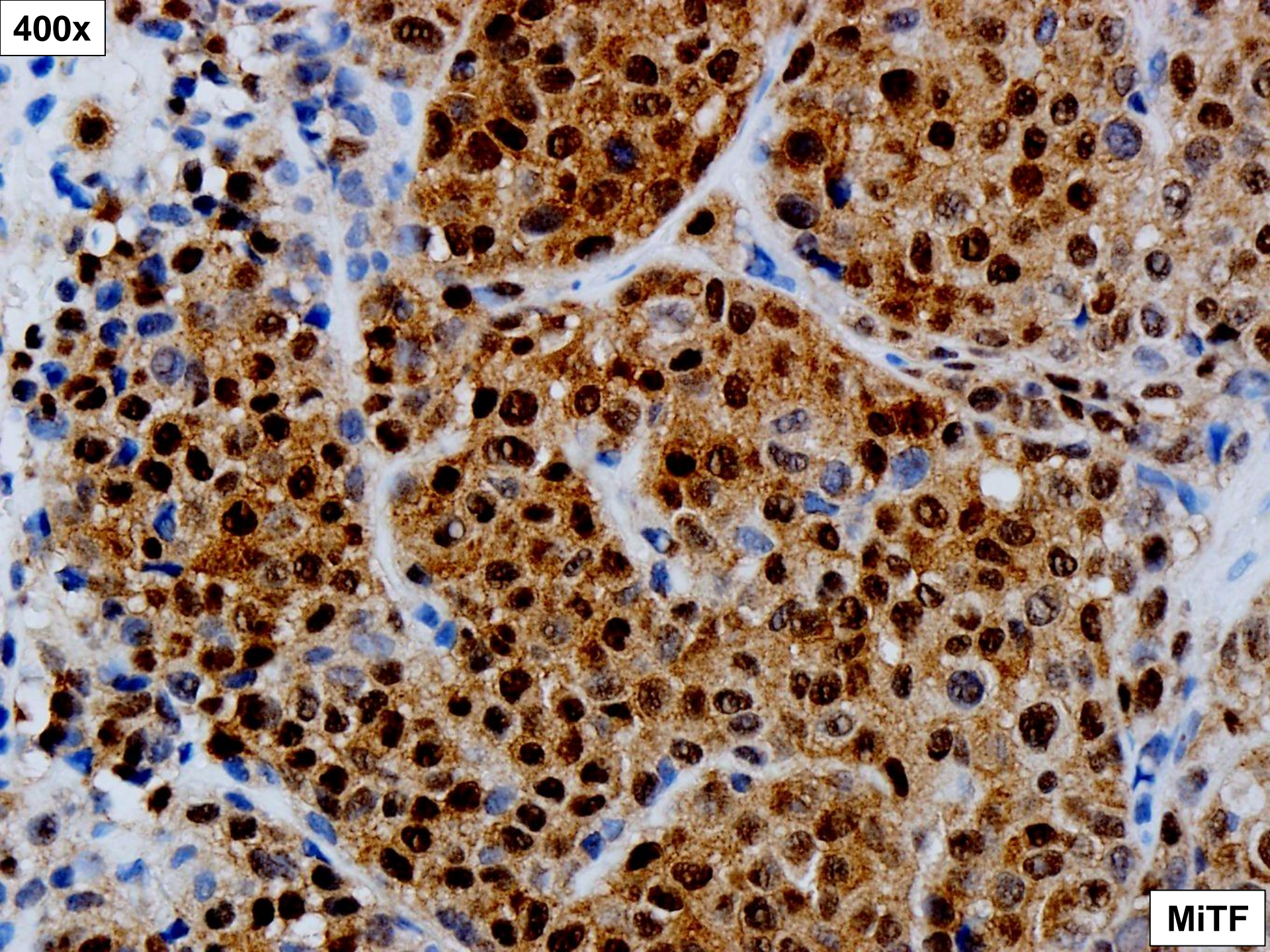
EMA

400x



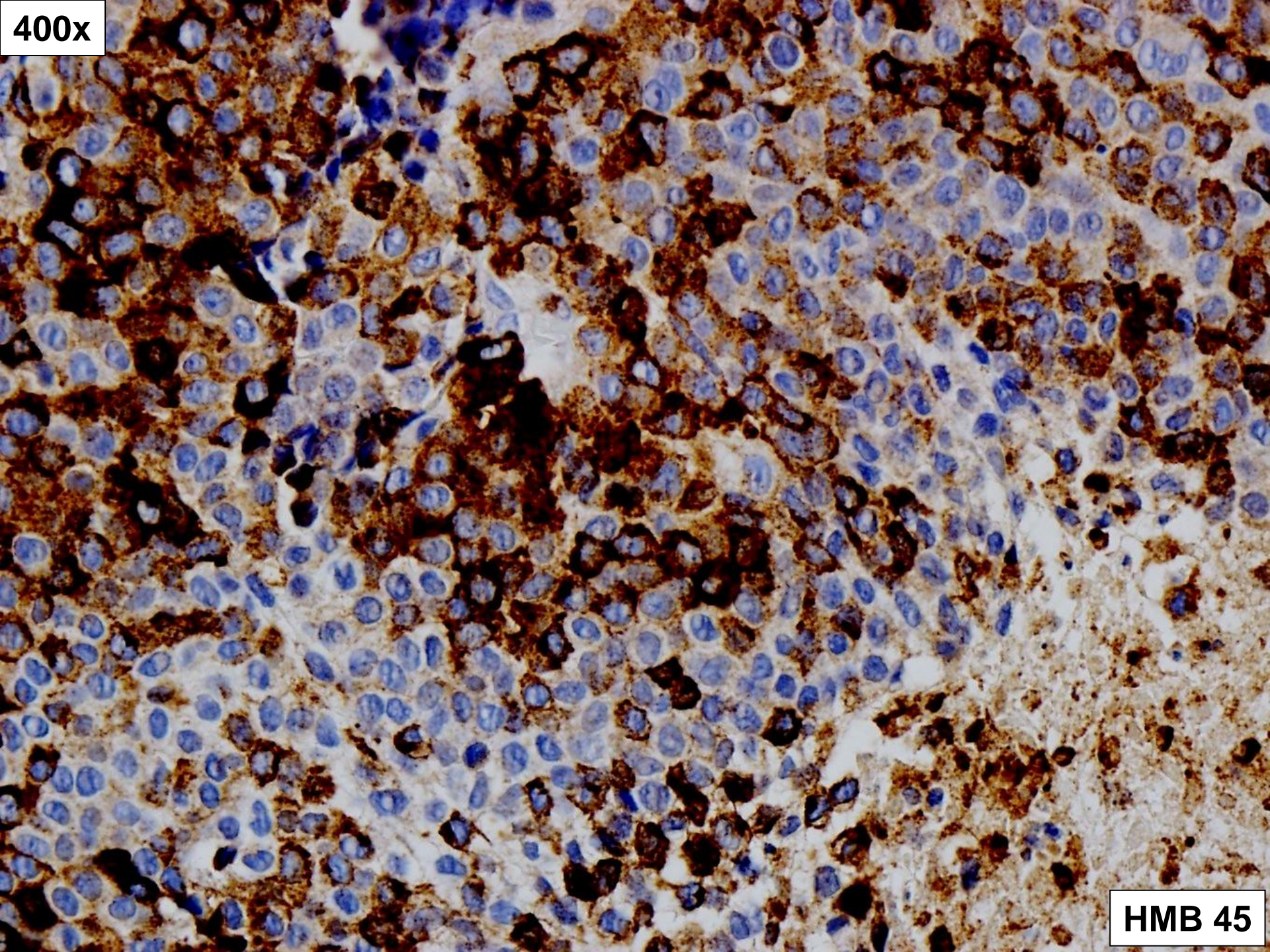
Melan A

400x



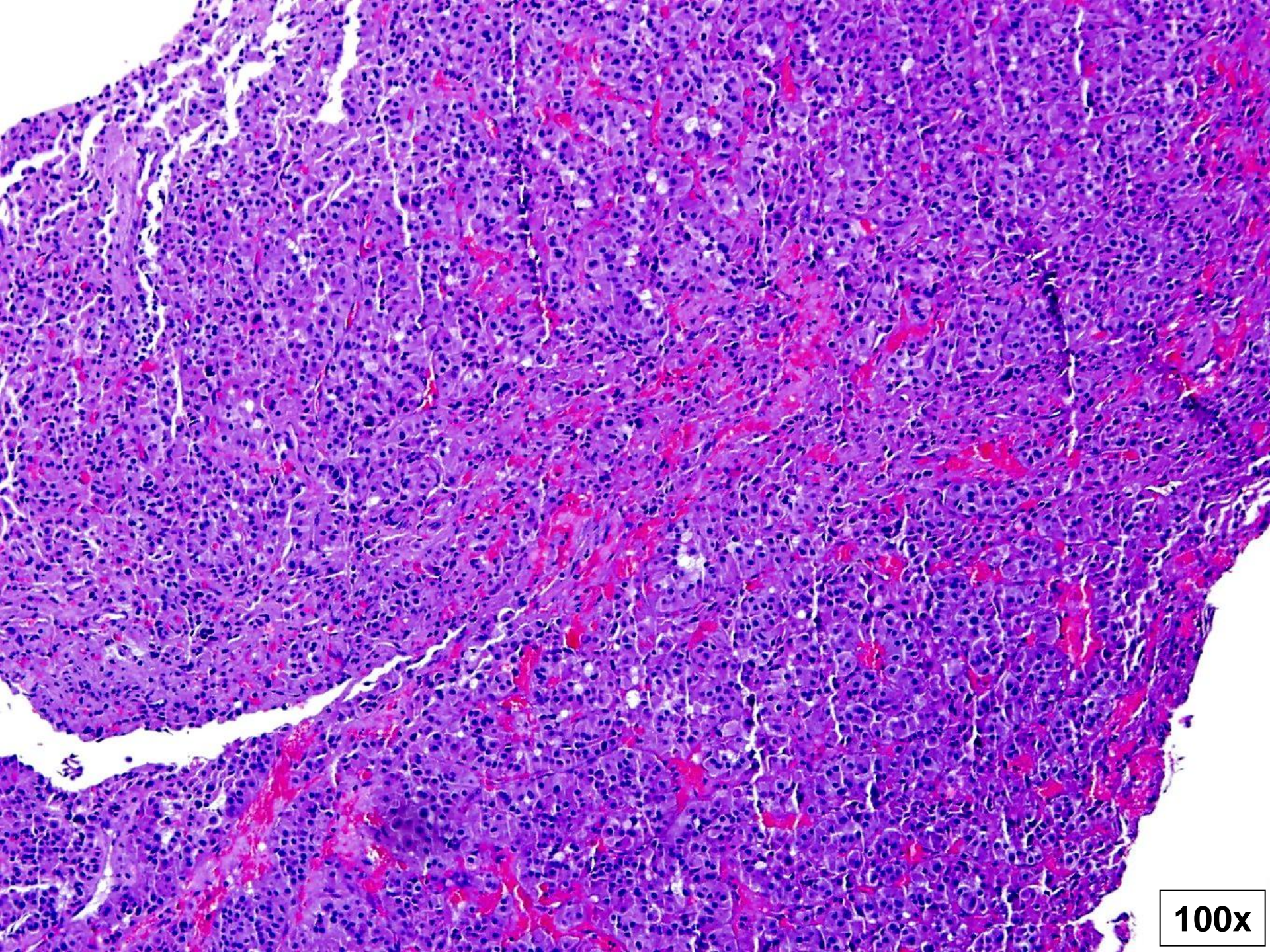
MiTF

400x

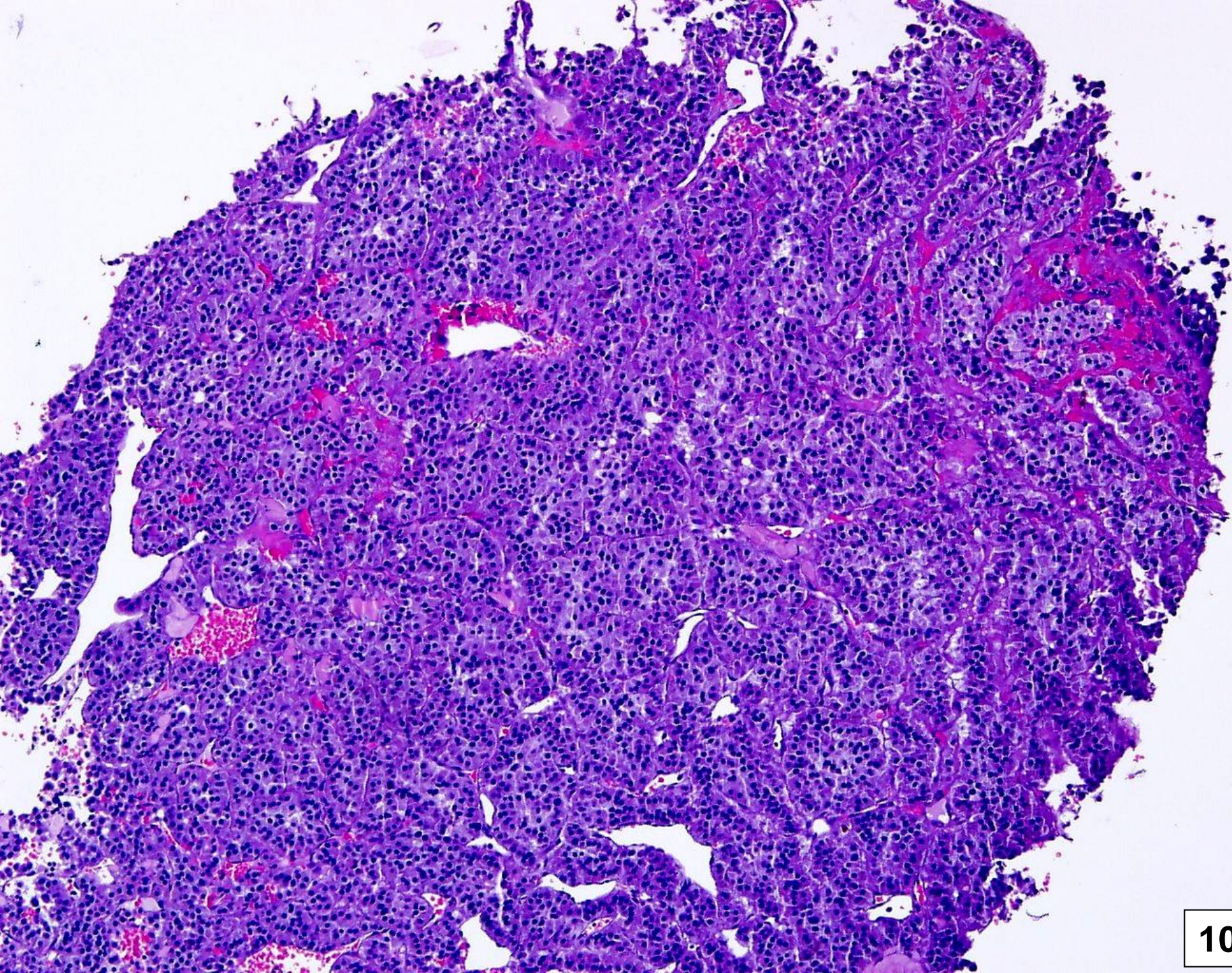


HMB 45

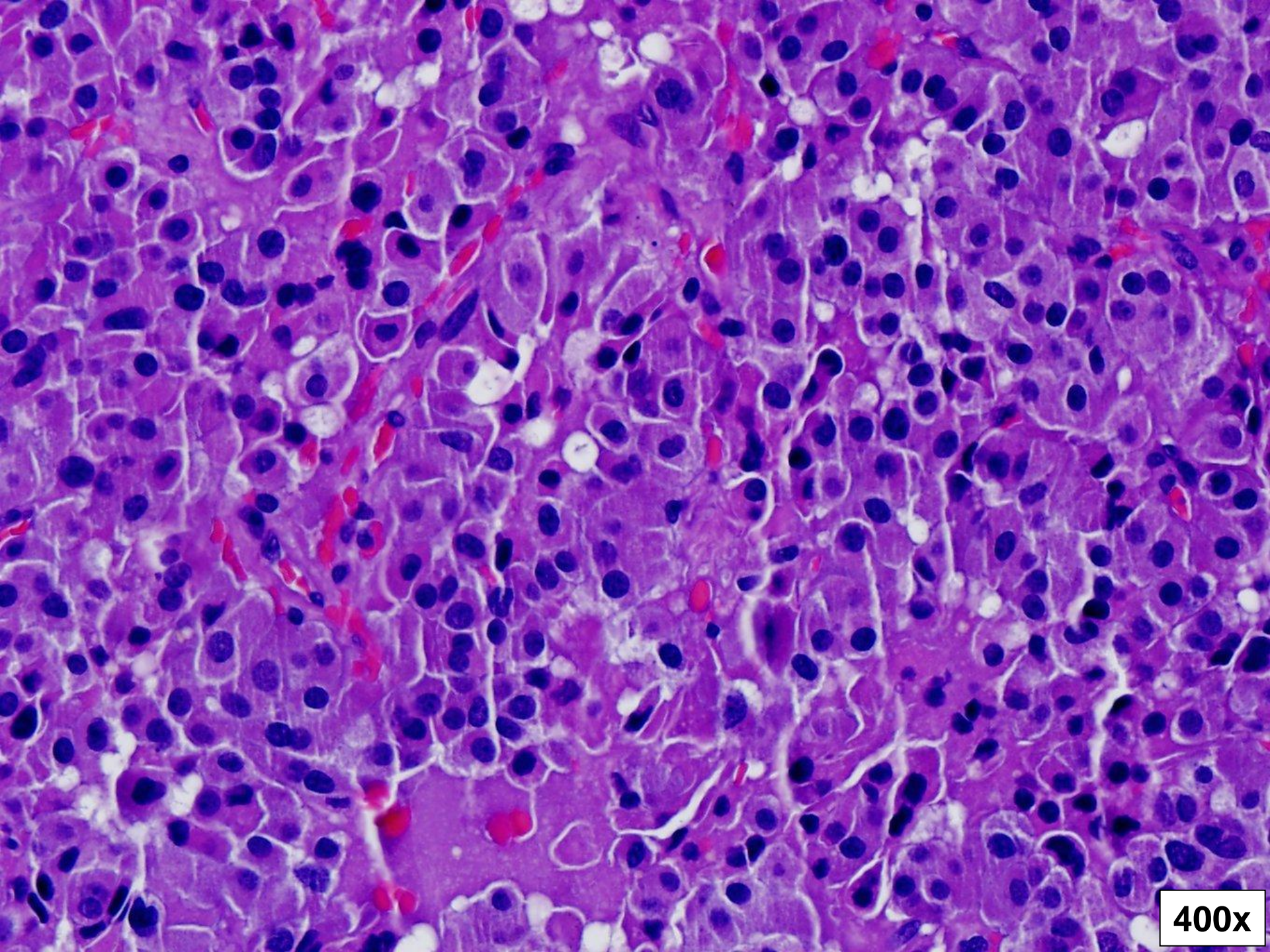
## ➤ METÁSTASE DE MELANOMA



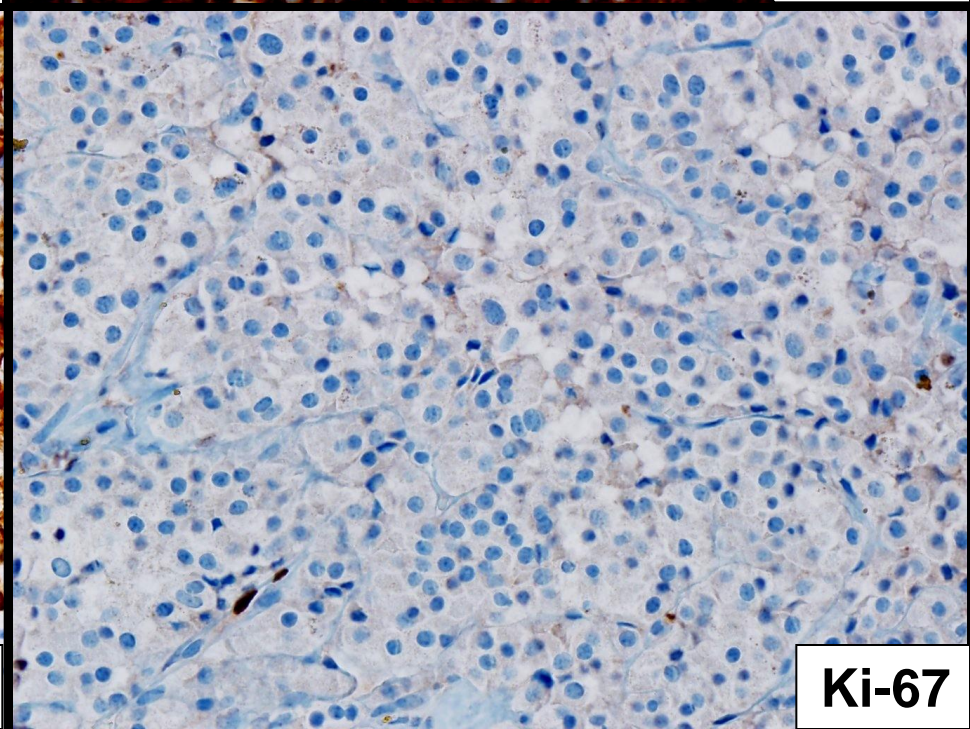
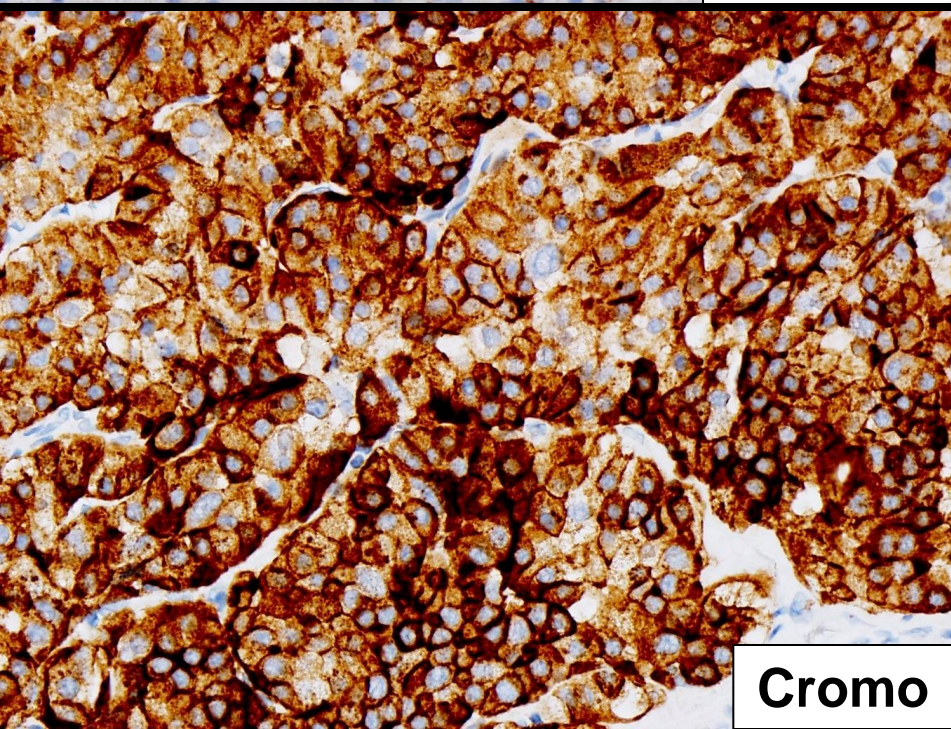
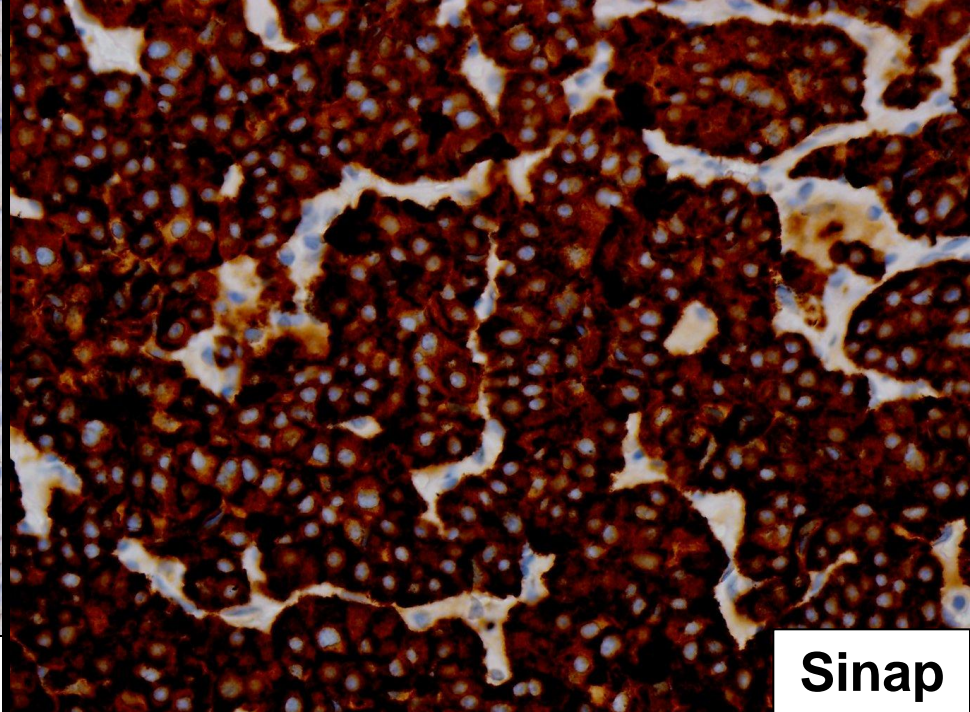
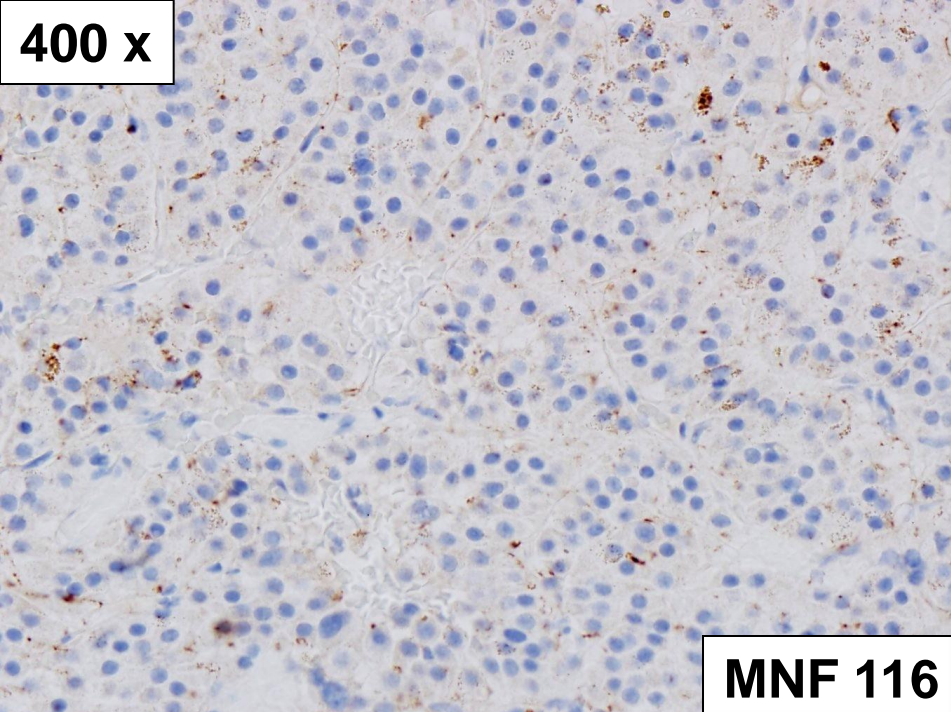
100x



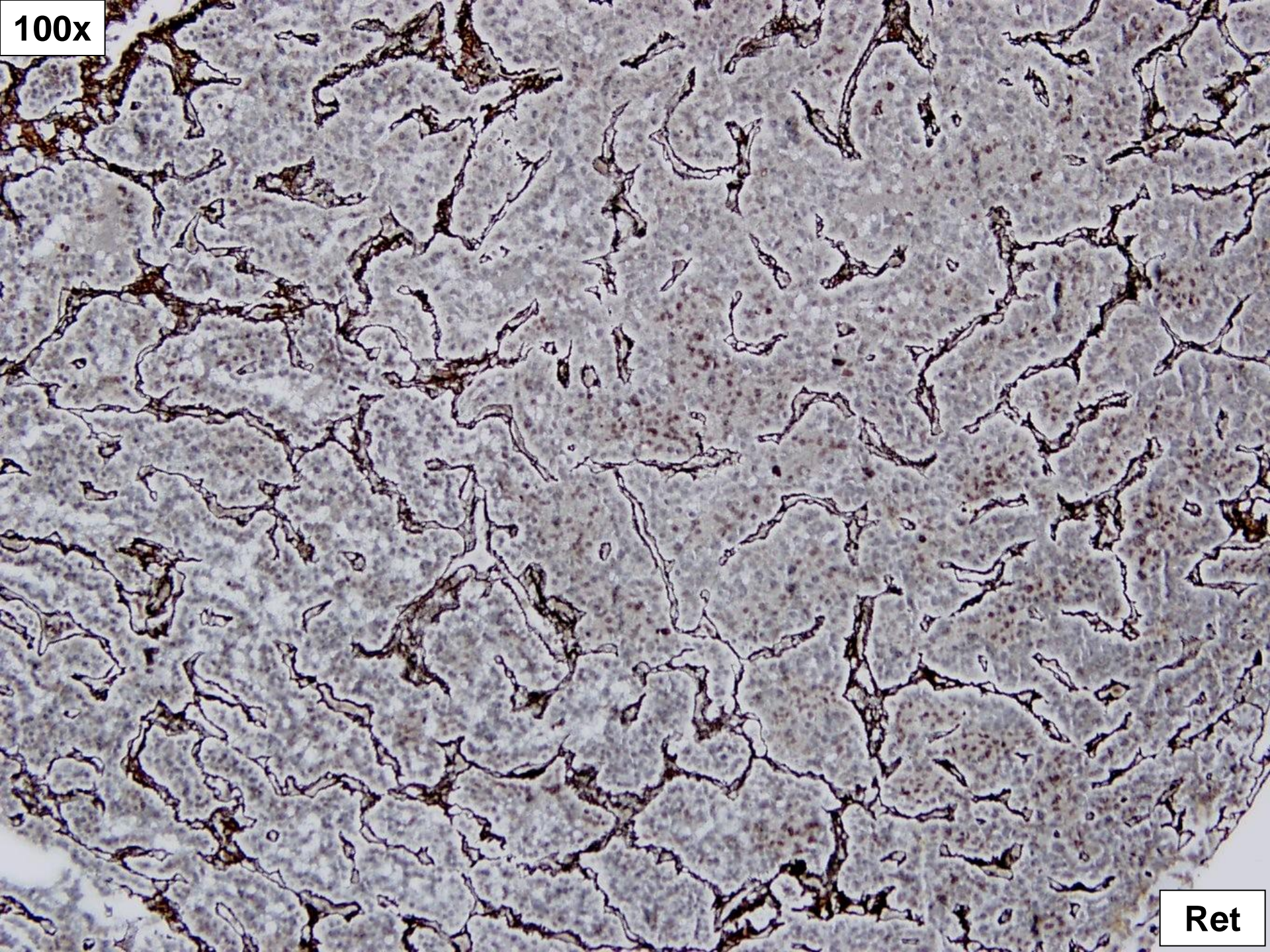
100x



400x

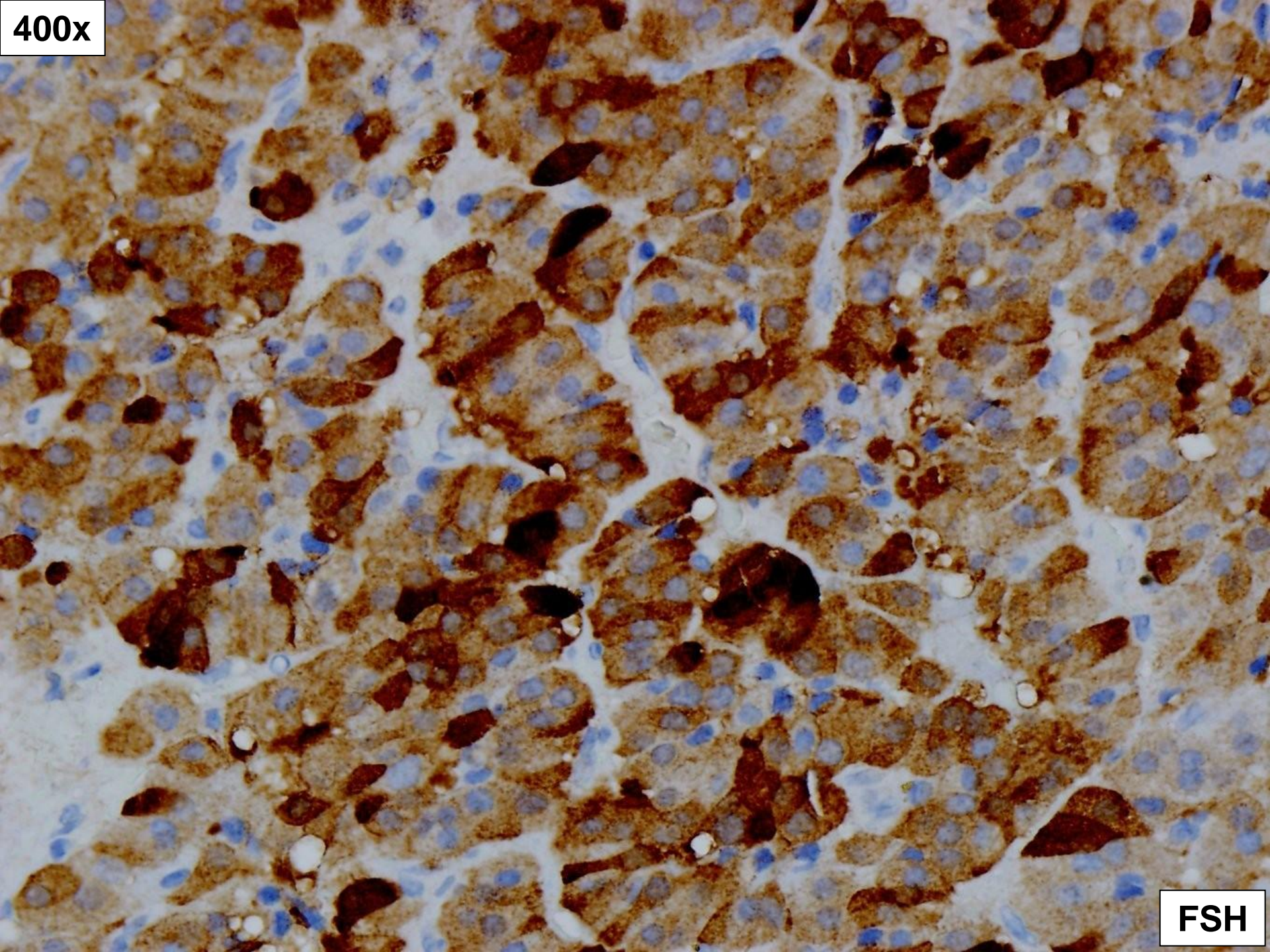


100x



Ret

400x



FSH

➤ **RECIDIVA DE ADENOMA HIPOFISÁRIO COM EXPRESSÃO DE FSH**

➤ **METÁSTASE DE MELANOMA E RECIDIVA DE  
ADENOMA HIPOFISÁRIO COM EXPRESSÃO DE FSH**

## Metástases na hipófise

- ✓ Detetadas em <1% dos doentes com metástases;
- ✓ Mais comum: **mama e pulmão** mas também próstata, GI, bexiga, supra-renal e tiróide;
- ✓ Sintomas:
  - ✓ *Diabetes Insipidus* (45-70%), panhipopituitarismo, alterações visuais e sintomas relacionados com a elevação da PIC.

# Melanoma metastático na hipófise



**Table: Patients with melanocytic tumors within the sella**

	Age/sex	Extrasellar primary	Preop endocrine deficits	DI	Brain mets	Surgery	XRT	Chemo	HMB-45/MIB-1	Follow-up/mos
<i>Primary sellar melanocytoma / benign</i>										
Neilson et al 1963 <sup>16</sup>	62/M	none	TSH, ACTH, FSH/LH	no	no	no	no	no		D/36
Scholtz and Siu 1976 <sup>17</sup>	54/M	none	?	?	no	yes	no	no		D/0.5
Kasumova and Imauri 1980 <sup>18</sup>	36/M	none	?	?	no	yes	no	no		A/72
Chappell et al 1990 <sup>19</sup>	35/F	none	?	no	no	yes	no	no		A/3
Rousseau et al 2005 <sup>20</sup>	25/F	none	ACTH	no	no	yes	no	no	positive / 3%	A/24
<i>Primary sellar melanoma / malignant</i>										
Roos 1963 <sup>23</sup>	44/F	none	TSH, ACTH	yes	no	yes	no	no		D/15
Copeland et al 1980 <sup>24</sup>	37/F	none	?	no	LMD	yes	no	yes		D/41
Aubin et al 1997 <sup>25</sup>	47/M	none	TSH, FSH/LH, ACTH	SIADH	no	yes	yes	no	positive	D/16
Tutenberg et al 2004 <sup>26</sup>	37/F	none	TSH, FSH/LH	no	no	yes	yes	no	positive / 15-30%	A/24
Jacob et al 2006 <sup>27</sup>	63/F	none	none	no	no	yes	yes	no	positive	D/weeks*
<b>Metastatic melanoma</b>										
Cox and Sloan 1924 <sup>1</sup>	54/M	jejunum	?	yes	yes	no	no	no		D/6
Girdwood 1928 <sup>2</sup>	42/F	skin (multiple)	?	yes	yes	no	no	no		D/1
Schurmeyer and Bettmann 1956 <sup>3</sup>	31/F	skin (back) spinal cord	?	no	no	no	no	no		D/unknown
Clifford et al 1968 <sup>4</sup>	64/M	(unproven) <sup>***</sup>	?	?	yes	no	no	no		D/unknown
Mayr et al 1993 <sup>5</sup>	25/M	?	TSH	no	yes	?	?	?		A/unknown
Leung et al 2004 <sup>6</sup>	46/M	skin (neck)	TSH, FSH/LH	yes	no	yes	yes	no	positive	A/7
McCutcheon et al 2006 (case 1)	79/M	skin (chest)	FSH/LH	no	no	yes	yes	no	positive	A/6
McCutcheon et al 2006 (case 2)	49/M	skin (chest)	TSH, FSH/LH, ACTH	no	yes	yes	yes	yes	positive	D/6
<i>Non-melanocytic tumors showing melanin production</i>										
		Tumor type								
Harris et al 1999 <sup>14</sup>		cranio-pharyngioma (2 cases)								
Tobo et al 1981 <sup>15</sup>		teratoma containing melanotic progroma (1 case)								

# Melanoma metastático na hipófise

- ✓ Muito raro;
- ✓ Descrito em 1857;
- ✓ Tratamento:
  - ✓ Exérese cirúrgica;
  - ✓ QT e RT.
- ✓ Sobrevida:
  - ✓ ~4 meses.



**Hospital**  
**Braga**

Sete Fontes – S. Victor  
4710-243 BRAGA

T. 253 027 000 F. 253 027 999

[www.hospitaldebraga.com](http://www.hospitaldebraga.com)